

Comparative Evaluation Of Efficacy Of Three Different Rotary Nickel Titanium Retreatment File Systems On Preserving Remaining Root Dentin Thickness Using Cone Beam Computed Tomography - An In Vitro Study

¹Dr. Noopur Mane, ²Dr. Anamika C.Borkar, ³Dr. Pradeep Shetty, ⁴Dr. Sanchit Mujumdar, ⁵Dr. Sayali Lokhande, ⁶Dr. Shreya Shirsath

¹PG Student, ²Professor, ^{4,6}PG Student, Department of Conservative Dentistry and Endodontics, Dr D.Y. Patil Dental College and Hospital, Dr.D.Y.Patil Vidyapeeth, Pune, Maharashtra, India;

³Professor and Head of Department, Department of Conservative Dentistry and Endodontics, Dr D.Y. Patil Dental School, Pune, Maharashtra, India;

⁵PG Student, Department of Oral Medicine and Radiology, Dr D.Y. Patil Dental College and Hospital, Dr.D.Y.Patil Vidyapeeth, Pune, Maharashtra, India

Corresponding author: Dr. Anamika Borkar, Professor, Department of Conservative Dentistry and Endodontics, Dr D.Y. Patil Dental College and Hospital, Dr.D.Y.Patil Vidyapeeth, Pune, Maharashtra, India Email: borkar.anamika@gmail.com

DOI: 10.47750/pnr.2023.14.02.95

Abstract

Objective: To evaluate and compare the efficacy of different rotary retreatment file systems on preserving the remaining dentin thickness using cone beam computed tomography.

Materials and methods: 36 single rooted, non carious mandibular premolars with straight single canals and closed apices were selected. All the teeth were prepared by the same operator using rotary files using an electric motor with the recommended torque and speed. Obturation was completed and CBCT images were taken at the coronal, middle and apical third and the buccolingual and mesiodistal dimensions were noted. The samples were then randomly allocated into 3 groups (n=12), Group I, Group II and Group III according to the retreatment kit used. A drop of gutta percha solvent was used in all the teeth. Post retreatment, the CBCT images were taken in the axial plane at the coronal, middle and apical one third. RDT was measured at the buccal, lingual, mesial and distal walls and compared. Statistical evaluation was done using Paired t test, One Way ANOVA and Post Hoc test.

Conclusion: A statistically significant difference was present in the RDT after retreatment between all the 3 groups in coronal, middle and apical section. Maximum amount of RDT was conserved in Group III followed by Group I followed by Group II after retreatment.

Key words: Retreatment, Endodontics, Remaining dentin thickness, Cone beam computed tomography

INTRODUCTION

Remaining Dentin Thickness (RDT) is an important factor as it is responsible for the fracture resistance of root canal treated teeth. ^[1] According to Lim and Stock, 200- 300mm dentin thickness must be retained after the chemo mechanical preparation to withstand the compaction forces, and to prevent errors like perforation or fracture of the tooth. ^[2] The amount of root dentin removal is directly proportional to the fracture susceptibility of the tooth and hence, the amount of remaining tooth structure is of utmost importance, as it determines the fracture resistance

of the root canal. ^[3] Despite the high success rate of root canal therapy, there can be various causes of failures. Endodontic failures can occur due to the persistence of microorganisms and debris within the intricacies of the root canal anatomy due to improper chemo mechanical preparation, or iatrogenic procedural errors leading to an incomplete coronal or apical seal. ^{[1][4]} Retreatment of these canals is necessary so as to remove the contents and present a clean canal with the absence of any debris or microorganisms. ^[1] It could be via two approaches, surgical and non surgical. Non surgical retreatment requires the complete removal of the pre-existent endodontic filling material from the canals. This eliminates the necrotic tissues and microbial populations and provides effective cleaning, shaping and filling of the root canal system. ^{[4][5]} The most commonly used material for filling root canals is gutta percha and hence, it should be removed whenever retreatment is indicated. ^[4] Usage of hand or rotary instruments with or without heat are the contemporary techniques used to remove the root canal filling material. Solvents and/or ultrasonic instruments can also be used. Specialized rotary instruments have now been designed for the purpose of retreatment. ^[1] Nickel Titanium (NiTi) instruments are better centered in the root canals when compared with hand instrumented stainless steel (SS) files and engine-driven Gates Glidden burs. The NiTi alloys are strong and have good flexibility. They also have a precise taper and flute design, which was not present with instruments made of stainless steel, which resulted in consistent shapes of the root canals. ^[6] Retreatment procedures may cause more damage to the root canal walls, as they require more mechanical manipulations and further preparations of the root canals. ^[7] As a result, various rotary retreatment file systems are now available, in order to minimize damage caused to root dentin and improve working safety. They are designed to have specific lengths, tapers and tip sizes for the purpose of efficient instrumentation. The Protaper Universal Retreatment Instrument kit (Dentsply Maillefer, Ballaigues, Switzerland), Neoendo Retreatment file kit (Orikam Healthcare, India) and R-Endo Instruments (Micro-Mega, Basancon, France) are 3 such file systems available in the market. Various methods have been employed to measure the RDT of root canals. Traditional methods such as sectioning of roots demand the destructive sectioning of specimens, and their physical reassembly. In this regard, Hartmann et al. recommended the use of Cone Beam Computed Tomography (CBCT) as a reliable method of measuring the RDT as it doesn't require destructive sectioning of specimens. CBCT has been proven to be very valuable to assess RDT following retreatment as it is a nondestructive technique, providing 3D images that are highly accurate, fully quantifiable and of a superior resolution. ^[9] Our study aimed to evaluate and compare the efficacy of ProTaper Universal Retreatment Files, NeoEndo Retreatment Files and the R-Endo Retreatment System on preserving the RDT using CBCT.

MATERIALS AND METHODS

36 intact, single rooted, mandibular premolars with single canals and closed apices were selected and diagnostic IOPA was taken. Soft tissue and calculi were mechanically debrided from the root surfaces and 2% Glutaraldehyde solution was used for disinfection of the root surfaces. Access cavity preparation was done and #10 stainless steel K file was placed in the canal so that the file tip is visible at the apical foramen to note the glide path. Digital radiographs were taken using radiovisuography (RVG). Standardization of the teeth was done by decoronating all the teeth and the root length was kept to 19mm. Chemo mechanical preparation was done using ProTaper Universal Rotary file system upto F1 file according to manufacturer's instructions using an electric motor (EConnect - Eighteenth™) with the recommended torque and speed and were intermittently irrigated using 5.25% sodium hypochlorite, 17% EDTA and normal saline. The final rinse was done using 2% chlorhexidine digluconate and canals were dried with absorbent paper points. Gutta Percha cone corresponding taper to F1 was selected as master cone and after confirming radiographically, obturation was done using AH Plus sealer using cold lateral compaction technique by the same operator. A hot plugger was used to remove the extra gutta percha up to the orifice level. The quality and the apical extension of the obturation was evaluated by digital radiography in the bucco lingual and mesio distal directions. The access cavities were sealed using temporary filling material – CAVIT G (3M ESPE) All the CBCT images were taken at the coronal, middle and apical third in the axial plane and the buccolingual and mesiodistal dimensions were noted. The samples were then be randomly allocated into 3 groups (n=12) according to the retreatment file systems used.

RETREATMENT PROCEDURE

After removal of the temporary restoration, one drop of GP solvent (RC Solve) was used for 2 minutes to soften the obturating material.

Group I was treated by ProTaper Retreatment files (Dentsply Maillefer). They comprise of three files; D1(30/0.09) used in the coronal third, D2(25/0.08) used in the middle third and D3(20/0.07) used in the entire root length up to the apical third. They were used at a speed of 300 rpm with a 3 N/m torque.

Group II was treated by NeoEndo Retreatment kit (Orikam Healthcare, India). It consists of three instruments; N1(30/0.09) used in the coronal third, N2(25/0.08) used in the middle third and N3(20/0.07) used up to the apical third. They were used at a speed of 350 rpm as per the manufacturer's instructions.

Group III was treated by REndo Retreatment files (Micro-Mega, Basancon, France). They consist of 5 files, Rm, Re, R1, R2, R3 with size and taper corresponding to 25/04, 25/08, 25/06 respectively. The Rm file is made up of stainless steel and was used with a ¼ turn to allow the following files to align. The Re was used to remove the initial 2- 3 mm of the filling. The initial 2-3mm of the GP was removed with the Re instrument. Following this, R1 and R2 instruments were used to remove the GP upto 1/3rd and 2/3rd of the entire length. Lastly, the R3 file was used upto the entire working length in a circumferential motion.

CBCT images were taken and evaluated in the axial plane after removal of the GP for all the samples in the 3 groups. RDT post obturation and post retreatment after using the ProTaper, NeoEndo and R-Endo files are seen in Figures 1, 2 and 3 respectively. Apical, middle and coronal one third of the roots were viewed and RDT of the buccal, lingual, mesial and distal walls was calculated in the axial plane using the measurement tool in the CBCT software. The mean values of the same are depicted in Table no. 1-3.

Figure 1: (Remaining dentin thickness post obturation and post retreatment in ProTaper group)

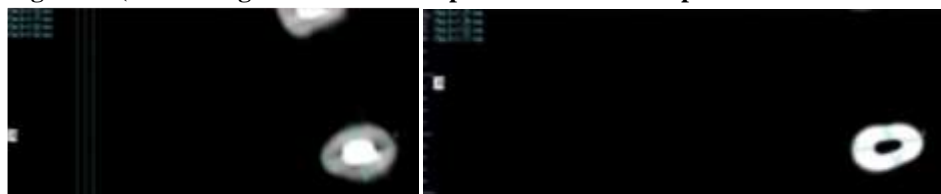



Figure 2: (Remaining dentin thickness post obturation and postretreatment in NeoEndo group)

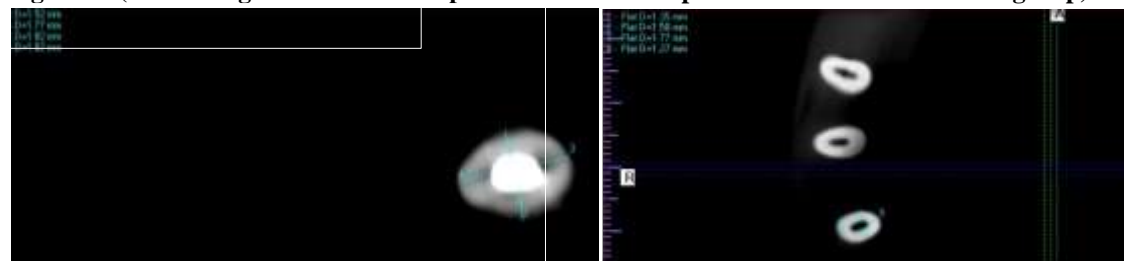

Figure 3: (Remaining dentin thickness post obturation and postretreatment in R-Endo group)



RESULTS

Statistical Analysis was performed using Paired t test, One Way ANOVA, Post Hoc test.

A statistically significant ($p < 0.05$) difference was noted in the RDT after retreatment between all the 3 groups in coronal, middle and apical section. In the coronal section, maximum RDT is noted in the R-Endo file system followed by the NeoEndo group and least amount of RDT was noted in the ProTaper group. (Table no. 1)

In the middle and apical sections, maximum RDT was preserved in the R-Endo file system followed by the ProTaper files and least with the NeoEndo files. (Table no. 2 and Table no. 3 respectively)

The dentin thickness was reduced more in NeoEndo group followed by Protaper and least with R-Endo group.

Groups	Mean	F	Significance (p)
NeoEndo file system	1.4800	11.591	<0.0001*
R-Endo file system	1.2883		
ProTaper file system	1.6092		
(Table no.1) Difference in remaining dentin thickness after the retreatment between NeoEndo, R-Endo and ProTaper file systems in coronal section.			

*Significance at $p < 0.05$

Groups	N	Mean	F	Significance (p)
NeoEndo file system	12	1.3208	11.727	<0.0001*
R-Endo file system	12	1.0375		
ProTaper file system	12	1.1275		
(Table no.2) Difference in remaining dentin thickness after the retreatment between NeoEndo, R-Endo and ProTaper file systems in middle section.				

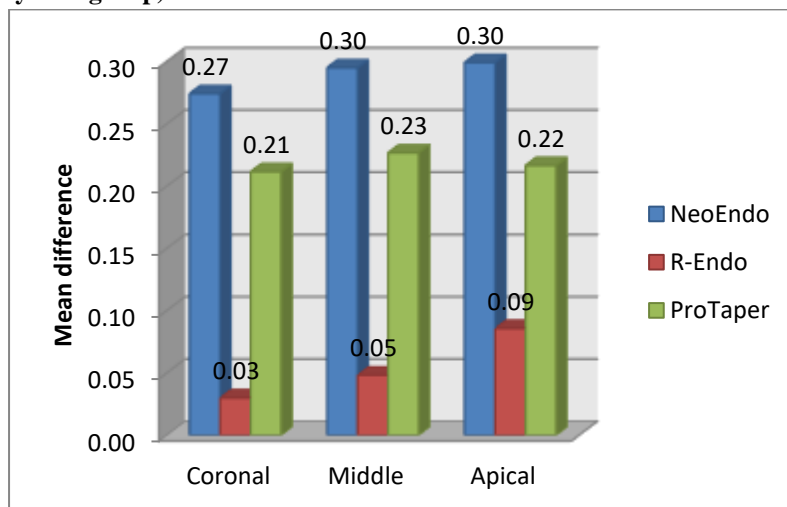
*Significance at $p < 0.05$

Groups	Mean	F	Significance (p)
NeoEndo file system	.9733	7.586	0.002*
R-Endo file system	.7075		
ProTaper file system	.7717		
(Table no.3) Difference in remaining dentin thickness after the retreatment between NeoEndo, R-Endo and ProTaper file systems in apical section.			

*Significance at $p < 0.05$

The mean difference in RDT in all 3 file systems is seen graphically in Figure 4.

Figure no: 4 (Bar diagram representing mean difference in remaining dentin thickness in all three file system group)



DISCUSSION

Although techniques used for retreatment of failed root canals are successful, a review of literature showed that a major cause of concern was the effect of these techniques on the RDT of the root canals.^[9] Mechanical limits of instrumentation are indicated by the RDT, that enlarge the diameter of the root canal, to approximately predetermined values that would not significantly cause the dentinal walls to weaken. In comparison to conventional radiography (CR), CBCT imaging has enabled the evaluation of anatomic structures in 3D, with a higher accuracy and greater resolution.^[7] CR provides two-dimensional (2D) representations of three-dimensional (3D) tooth structures. They provide a noninvasive, inside view of the root canal system.^[7] Hence, it is possible to scan the teeth before and after instrumentation and then draw a comparison between the obtained images. Xu et al in 2017 studied the accuracy of CBCT in measuring dentin thickness and its potential of predicting the RDT after removing fractured instruments and proved that this single imaging technique helps us in viewing the images in various planes i.e., coronal, sagittal, or even an oblique or curved image planes.^{[8] [13]} Many studies have been conducted till date to study the efficacy of rotary retreatment files in removing the gutta percha from canal spaces, and in assessing the RDT after usage of the same. A similar study was conducted by Kulkarni et al in 2020, where they evaluated the RDT following the usage of 3 different rotary retreatment files using CBCT. In this study, Mtwo and D-Race files were associated with significantly more amount of RDT when compared to ProTaper files. In our present study, teeth were divided into 3 groups (n=12) according to the retreatment files used, Group I – Protaper Universal Retreatment Files, Group II – NeoEndo Retreatment files, Group III – R-Endo instruments. CBCT images were taken before and after the retreatment, and the RDT was measured in the buccal, lingual, mesial and distal walls at the coronal, middle and apical third in the axial view.

The R-Endo retreatment kit has a stainless steel hand file and four NiTi files, with a triangular cross section. They also have equally spaced cutting edges with no radial angle or an active tip. It has an improved flexibility due to its lesser core structure. The files are usually centered within the canal. This could be the reason for the maximum amount of RDT conserved in Group III after retreatment.

The Protaper files have a progressive taper and length and a convex triangular cross section. More dentin removal could be attributed due to the multiple tapers present in the file systems or the large internal mass. These results are in consensus with the study conducted by Kulkarni et al in 2020 showed that ProTaper Retreatment files conserved lesser dentin when compared with D-Race and Mtwo retreatment files.

The NeoEndo files have a parallelogram cross section that limits the contact between the file and the dentin to only one or two points at any given cross section. This reduces the binding of the file and ensures little or no screwing in. A positive rake angle is present in the file. The improved cutting efficiency could be the reason for lesser amount of dentin remaining. This is in accordance with the the study done by Muraleedhar AV et al in 2021, where the NeoEndo group showed least amount of gutta percha remaining in the root canals during retreatment, when compared to ProTaper and R-Endo retreatment files. A greater cutting could be the reason for lesser amount of dentin remaining.

CONCLUSION

A statistically significant difference was present in the RDT after retreatment between all the 3 groups in coronal, middle and apical section. Maximum amount of RDT was conserved in Group III(REndo) followed by Group I (ProTaper) followed by Group II (NeoEndo) after retreatment. As the dentin thickness was reduced least with R-Endo group, it can be concluded that greater efficacy is present in the R-Endo files for conserving the RDT. However, more studies are required to be directed towards the evaluation of the efficacy of rotary retreatment files in the conservation of RDT.

ACKNOWLEDGMENTS

None.

CONFLICT OF INTEREST

None.

FINANCIAL SUPPORT

None.

ETHICS STATEMENT

None.

REFERENCES

1. Sartaj M, Ankush Sangra, Riyaz Farooq, et al Comparative evaluation of dentinal changes following retreatment by rotary NiTi retreatment files: An ex vivo stereomicroscopic analysis. *Indian Journal of Applied Dental Sciences*. 2017;3(1):94-97.
2. Lim SS, Stock CJ. The risk of perforation in the curved canal: anticurvature filing compared with the stepback technique. *Int Endod J* 1987;20:33-9.
3. Bhaumik T, Roy M, Das UK, Dutta K. Comparison of apical transportation and centering ability of ProTaper next, HyFlex cm and twisted files by using cone beam computed tomography. *J Med Dent Sci Res* 2017;3:29-34.
4. Mollo A, Botti G, Prinicipi Goldoni N, Randellini E, Paragliola R, Chazine M, Ounsi HF, Grandini S. Efficacy of two Ni-Ti systems and hand files for removing gutta-percha from root canals. *International endodontic journal*. 2012 Jan;45(1):1-6.
5. Imura N, Kato AS, Hata GI, Uemura M, Toda T, Weine F. A comparison of the relative efficacies of four hand and rotary instrumentation techniques during endodontic retreatment. *Int Endod J*. 2000; 33:361-6.
6. Suneetha M, Moiz A, Sharief H, Yedla K, Baig M, Abu Al Qomsan M. Residual root dentin thickness for three different rotary systems: A comparative cone beam computed tomography in vitro study. *Journal of Indian Society of Pedodontics and Preventive Dentistry*. 2020;38(1):48.
7. Mangal S, Mathew S, Murthy BS, Nagaraja S, Dinesh K, Ramesh P. Cone-beam computed tomographic evaluation of remaining dentin thickness in bifurcated roots of maxillary first premolars after rotary instrumentation and post space preparation: An in vitro study. *Journal of Conservative Dentistry: JCD*. 2018 Jan;21(1):63.
8. Bunn Daiana Lopes, Corrêa Márcio, Dutra Kamile Leonardi, Schimdt Tamer Ferreira, Teixeira Cleonice da Silveira, Garcia Lucas da Fonseca Roberti et al . Accuracy of Cone-Beam Computed Tomography in Measuring the Thickness of Radicular Dentin. *Braz. Dent. J.* 2020; 31(5): 516-522
9. Kulkarni NR, Kamat SB, Hugar SI, Nanjannawar GS, Patil PD. Evaluation of remaining dentin thickness following use of three different rotary nickel–titanium retreatment files: A cone-beam computed tomography study. *J Conserv Dent* 2019;22:588-92
10. Joseph M, Ahlawat J, Malhotra A, Rao M, Sharma A, Talwar S. In vitro evaluation of efficacy of different rotary instrument systems for gutta percha removal during root canal retreatment. *Journal of clinical and experimental dentistry*. 2016 Oct;8(4):e355.
11. Xu J, He J, Yang Q, Huang D, Zhou X, Peters OA, Gao Y. Accuracy of cone-beam computed tomography in measuring dentin thickness and its potential of predicting the remaining dentin thickness after removing fractured instruments. *Journal of endodontics*. 2017 Sep 1;43(9):1522-7.
12. Antony JM, Kudva AR, Shetty HK, Kini S, Gowri S. Comparative Efficacy of Three Different Retreatment Rotary Instrument Systems for Removal of Gutta-Percha from Root Canals: A Comparative in Vitro Study. *Indian Journal of Public Health Research & Development*. 2019 Apr 1;10(4).
13. Muraleedhar AV, Satish SV, Patil AM, Kovvuru SK, Patil S. Comparative Evaluation of Efficacy of Three Different Rotary Retreatment Systems with Manual Instrumentation in Removing Gutta-Percha from Root Canals--An In Vitro Study. *Journal of Evolution of Medical and Dental Sciences*. 2021 Apr 5;10(14):1025-30.