

A Case Report of Atypical Cutaneous Necrobiotic Xanthogranuloma Associated with Lung Involvement, Papillary Thyroid Carcinoma and Review of the Literature

Mohammadreza Ghassemi¹, Anahita Tabavar², Nasrin Shayanfar³, Azadeh Goodarzi⁴, Azadeh Seifadini⁵, Ehsan Alavi Rad⁶

¹MD, Associate Professor, Department of Dermatology, Rasool Akram Medical Complex Clinical Research Development Center (RCRDC), School of Medicine, Iran University of Medical Sciences, Tehran, Iran. E-mail: ghassemi.mr@iums.ac.ir; mohammadreza.ghassemi@gmail.com, ORCID ID: <http://orcid.org/0000-0002-0706-554X>

²MD, Department of Dermatology, Rasool Akram Medical Complex Clinical Research Development Center (RCRDC), School of Medicine, Iran University of Medical Sciences, Tehran, Iran. E-mail: anahita.tabavar@gmail.com, <https://orcid.org/0000-0001-8556-9893>

³MD, Associate Professor, Department of Dermatopathology, Rasool Akram Medical Complex, Iran University of Medical Sciences, Tehran, Iran. E-mail: nasrin.shayanfar@gmail.com; <https://orcid.org/0000-0001-8599-1402>

⁴MD, Associate Professor, Department of Dermatology, Rasool Akram Medical Complex Clinical Research Development Center (RCRDC), School of Medicine, Iran University of Medical Sciences, Tehran, Iran. E-mail: goodarzi.a@iums.ac.ir; azadeh_goodarzi1984@yahoo.com, ORCID ID: <http://orcid.org/0000-0002-1249-4429>

⁵MD, Department of Dermatology, Rasool Akram Medical Complex Clinical Research Development Center (RCRDC), School of Medicine, Iran, University of Medical Sciences, Tehran, Iran. E-mail: dr.az.seif@gmail.com, ORCID ID: <http://orcid.org/0000-0002-3907-466x>

⁶MD, Department of Radiology, Imam Khomeini Hospital Complex (IKHC), Tehran University of Medical Sciences, Tehran, Iran. E-mail: ehsan.alaviad@gmail.com ORCID ID: 0000-0003-1065-5913

Abstract

Necrobiotic Xanthogranuloma is a rare skin disorder, manifesting with yellow-brown nodules and plaques usually found in periorbital areas. The most common associated malignancy is monoclonal gammopathy. This is the first case of NXG associated with lung involvement and papillary thyroid cell carcinoma and a novel therapeutic strategy for cutaneous lesions.

Keywords: Histiocytosis, Necrobiotic Xanthogranuloma, NXG, Xanthogranuloma, Malignancy.

Key Message: Necrobiotic Xanthogranuloma is an uncommon skin disease of the non-Langerhans cell histiocytosis. We present the first case of NXG associated with lung involvement and papillary thyroid cell carcinoma and a novel strategy for cutaneous lesions.

DOI: 10.47750/pnr.2022.13.S03.110

INTRODUCTION

Necrobiotic Xanthogranuloma is a uncommon type of non-langerhans cell histiocytosis. Its skin lesions more involved the periorbital area with brown-yellow papules, nodules and less ulceration, atrophy and telangiectasia. Common its association is systemic paraproteinemia and less other malignancies. This is the first case of NXG associated with lung involvement and papillary thyroid cell carcinoma and a novel therapeutic strategy for cutaneous lesions.

nodules and plaques on herextra-orbital facial area, scalp and upper trunk from 1 year ago (Figure 1-2).

Case report

A 56-year-old woman presented to our dermatologic department with multiple progressive yellowish-brown

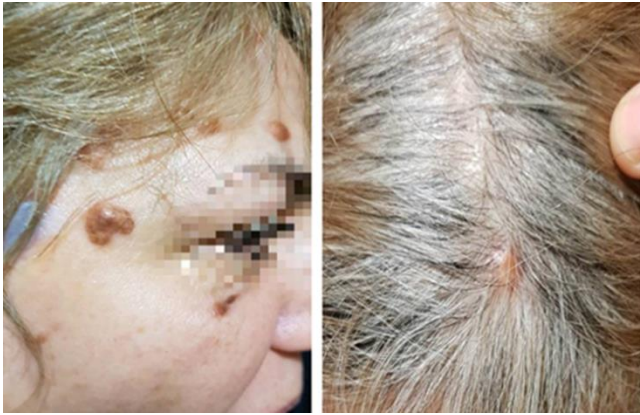


Fig 1: The primary skin lesions in clinical examination: yellow-brown papular and nodular lesions in lateral face and the scalp

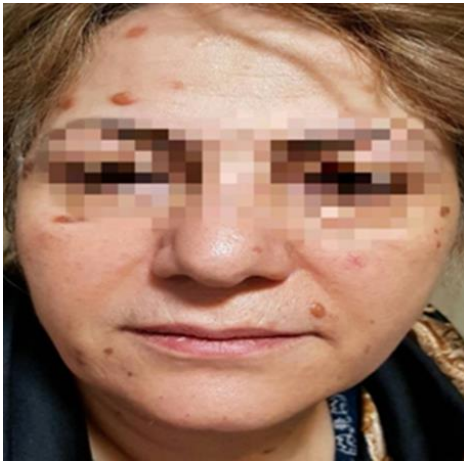

Fig 2: The primary skin lesions in clinical examination: yellow-brown papular and nodular lesions scattered in the face

Her past medical history were hypothyroidism, type 2 diabetes mellitus and a history of non-productive cough from 1 year prior.

There was no history of any hematologic, eye complaints or other organ disorders.

The communication chain of findings and final diagnosis were made based on clinical, paraclinical, laboratory, histopathological and immunohistochemical (IHC) findings.

The Cell blood counts and differential were within the standard level. Other lab tests included: complements (C3, C4 and CH50), tumor markers such as CEA, CA19-9, CA125, CA15-3 and hormones (TSH, T4, T3, RTH, Calcitonin) were within the normal ranges.

Exisional biopsy of one cutaneous lesion was performed and showed infiltrative pattern of mixed inflammatory cells including lymphocyte, plasma cells, epithelioid cells, macrophages and foamy histiocytes resembling Totoun giant cells in a vague storiform arrangement, extension into subcutaneous fat, consistent with

Necrobiotic xanthogranuloma (Figure 3).

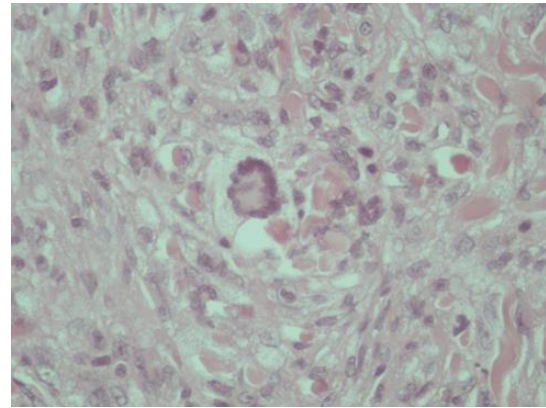


Fig 3: Histological images of skin biopsy: Infiltrative pattern of mixed inflammatory cells including lymphocyte, plasma cells, epithelioid cells, macrophages and foamy histiocytes resembling Totoun giant cells in a vague storiform arrangement, extension into subcutaneous fat

Immunohistochemistry staining show positive for CD68 and negative for CD1a, langerin and S100. Serum protein electrophoresis showed no monoclonal gammopathy.

(Total protein: 6.7 (referenc interval (RI): 6.6 -8.1)

Alpha1: 2.8 (RI: 1-3.2)

Alpha2: 10.9 (RI : 7.1-11.8)

Beta globulin: 10.2 (7.5-12.9)

Gamma: 13.5 (11.1-18.8)

Bone marrow aspiration and biopsy were normocellular.

Thyroid ultrasound was performed because of the history of hypothyroidism and that showed a hypoechoic nodule with an ill defined border which included macrocalcification about 18*20 mm in the right lobe. Finally it was reported by fine needle biopsy (FNA) as papillary thyroid carcinoma (Figure 4).

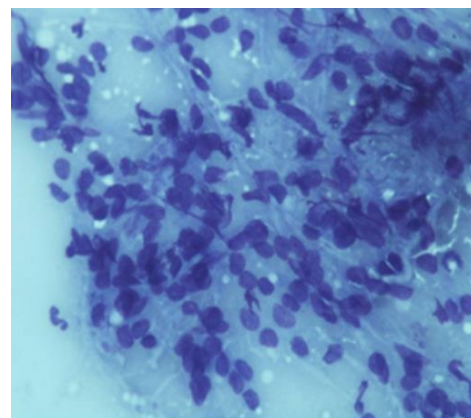


Fig 4: The Biopsy of thyroid nodule: Papillary thyroid carcinoma (FNA)

Serum metanephrine and normetanephrine were measured for screening of MEN II, which was in the normal range.

Normetanephrine: 99 (RI: up to 196).

Metanephrine: 25.2 (RI: up to 65)

Noradrenaline: 10 (RI: up to 100).

Malignancy screening including mammography, endoscopy, colonoscopy were done and there were no problem.

Whole-body scan showed no remarkable abnormality throughout the body.

Abdomen CT scan reported multiple nodules in the lung parenchymal, suggesting of metastatic nodules.

High resolution computed tomography (HRCT) confirmed the presence of multiple nodules with sharp borders in both lung field, that suggesting of metastatic nodules, granulomatous disease and fungal infection. The biopsy of lung nodules showed spindle cell proliferation with reactive cellular changes and few mitotic actin, admixed with foamy macrophages (Figure 5).

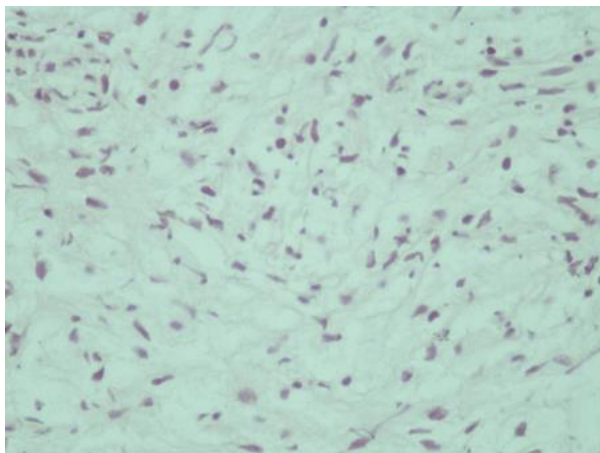


Fig 5: The Biopsy of lung nodule: Spindle cell proliferation with reactive cellular changes and few mitotic actin, admixed with foamy macrophages

Benign hisiocytic nodule was more in favor of xanthomatus nodule. (IHC Markers: LCA (Leukocyte Common Antigen): positive in spindle cell, CK (Cytokeratin): negative in spindle cell, CD68: positive in spindle cell, SMA (Smooth Muscle Antigen): negative in spindle cell, Desmin: negative in spindle cell).

Finally, for the treatment of skin lesions, due to the patient's condition such as multiple skin lesions, poor compliance and multiple excision and sutures, Radiofrequency was performed, and showed no recurrence during the first year of follow up (Figure 6).

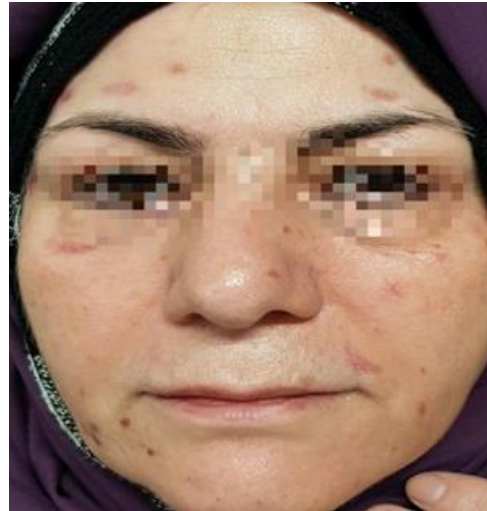

Fig 6: One month after treatment of lesions with radiofrequency electrosurgery

The patient was also referred to continue the thyroid carcinoma treatment.

NXG could be paraneoplastic and is usually associated with hematologic malignancies and rarely presents together with solid organ neoplasia; we reported the first case of NXG associated with papillary thyroid carcinoma and concomitant histiocytic lung metastasis. Also, we present a novel therapeutic approach regarding multiple cutaneous xanthogranuloma lesions.

DISCUSSION

Necrobiotic Xanthogranuloma is an uncommon skin disease of the non-Langerhans cell histiocytosis. The first case of NXG was reported by Kossard and Winkelmann in 1980.¹

The pathogenesis of NXG has not yet been elucidated, but possible theories include a foreign body giant cell reaction in the dermis and subcutaneous tissue to the complex formed by serum immunoglobulins with lipids. Lipoprotein receptors in monocytes have also been described as one of the possible mechanisms.^{2,3}

Histopathologically, NXG is an inflammatory granulomatous disease of the dermis and subcutaneous areas and focal necrobiosis. Other diagnostic changes include granulomas composed of foamy histiocytes called Touton giant cell, extracellular lipids, or cholesterol clefts.^{4,5}

More than 80% of cutaneous NXG cases occur first in the periorbital areas, although they occur later in the trunk and extremities. Other noncutaneous organ involvements reported include the eye, heart, liver, lung, skeletal muscle, bone marrow, spleen, kidneys, ovaries, intestines, paranasal sinuses, lacrimal glands, larynx and pharynx.^{2,3,6-11}

The most important complication in NXG is systemic comorbidities that the most commonly reported comorbidities to date are hematologic diseases, among which monoclonal gammopathy has been detected in more than

80% of NXG cases, especially IgG type. The Lambda or Kappa light chain has been listed, which can be identified years before, at the same time, or after NXG detection.

Other systemic diseases that have been mentioned in the literature so far include multiple myeloma, Hodgkin's lymphoma, and non Hodgkin's lymphoma, chronic lymphocytic leukemia, lymphocytolasmacytic lymphoma, Waldenstrommacroglobulinemia, amyloidosis and myelodysplastic syndrome.^{3, 5, 9-12}

Although NXG can be not associated with paraproteinemia in some patients, it is necessary to evaluate all patients for hematological disorders.

To date, more than 100 cases of NXG have been reported in the literature with different clinical manifestations and treatment strategies. In this review, we will examine the important review articles that have been provided so far about this disease.

The first review was written in 1986 by Finan MC,¹³ in which 22 NXG cases were reviewed. The most commonly reported site of involvement was periorbital and the most common complication was IgG monoclonal gammopathy (in 20 cases). Multiple myeloma was reported in 3 patients and cryoglobulinemia in 3 patients. The most commonly treatment was a low dose chemotherapy, which resulted in favorable results in both skin and hematologic involvement.

In 1992, Mehregan¹⁴ examined 48 cases (32 from myoclinics and 16 from world literature); the most common site of involvement was related to facial involvement, especially periorbital, and the most common complication was monoclonal gammopathy. Other systemic complications included mucosal, muscle and myocardial involvement and the most commonly used treatment was a low dose of chlorambucil which was eventually reported to be effective. Some patients also had a good therapeutic response to corticosteroid, melphalan, local radiation, and plasma change.

In 2000, Ugrulu¹⁵ examined 26 cases (1980 - 1997) of myoclinics. Eighty-one percent of the cases had ocular adnexa, 4 multiple myeloma, 5 placental dyscrasia and 1 a lymphoproliferative disease. Recurrence occurred in 11 patients after surgical removal.

Wood AJ⁷ surveyed 17 cases in 2009, the most common site was periorbital (65%) and then trunk (47%). Seventy one percent of the patients had monoclonal gammopathy and 18% multiple myeloma, and 3 patients had mastoid, lung and facial nerve palsy and 5 patients had ocular involvement. The most commonly used modality of therapy was chemotherapy, often prescribed with oral choricosteroids. In 4 patients chlorambucil plus prednisolone had an excellent response in 2 patients and in 2 patients without therapeutic response.

Efebera^{Y3} studied 19 cases from the world literature in 2011 (1993–2013), the most common site of involvement was periorbital and the most common complication was IgG monoclonal gammopathy. The other complications included

cardiac, splenomegaly, cryoglobulinemia, multiple myeloma, hepatomegaly, CLL, breadwinner lymphoma, and lymphoplasmic lymphoma. In this study, the introduced case responded to thalidomide plus dexamethasone with complete response, while not expressing the treatments were used for the previous case and the overall outcome was unavailable.

Higgins LS⁵ surveyed 35 cases (2015-2000) in 2016, the study results showed that the most common site of the involvement was periorbital (66%) and the involvement cases were reported as the liver in 1 case, 1 mastoid, and 4 intra-orbital cases. Twenty eight patients had IgG monoclonal gammopathy of undetermined significance (MGUS). Smoldering multiple myeloma (SMM) was reported in 5 patients and Chronic Lymphocytic Leukemia (CLL) in 2 patients. Treatments included excision, intra-lesional injection, radiotherapy, and systemic chemotherapy.

In 2018, Hilal^{T6} examined 19 cases (1987–87) of myoclinics, indicating 53% with periorbital involvement, 32% with liver, and 20% with sinusitis. Moreover, Most of the patients (84%) had IgG monoclonal gammopathy and malignancy present in 26% of the patients with CLL, multiple myeloma and Hodgkin's lymphoma. The most commonly used treatment was chlorambucil with or without systemic corticosteroids with a 95% response.

Due to the uncommon nature of the disease, there is no standard and definite therapeutic modality yet and various treatments reported so far usually based on the patient's condition and systemic associations.

Miguel D⁴ in 2016 conducted a systematic review of the previous treatments for NXG during the years 1980–2014 and put forward a proposed treatment algorithm for aphrodisiac disease.

Table 1 lists cases reported from 2017 to the current study that which has not been in any review so far.

Table 1: Reported cases of necrobioticxanthogranuloma

Author	Age/Sex	location	Association	Treatment
Keorochana/2017 ¹⁶	53/M	Scleral involvement	In the setting of Wegner's granulomatosis	High dose CS and cyclophosphamide
Lukacs/2017 ¹⁷	74/F	Periorbital and lower extremities	-	Intravenous immunoglobulin (IVIG)
Edwards/2017 ¹⁸	61/F	periorbital	Chronic myelomonocytic leukemia (CMML)	Debulking surgery
Vignon/2017 ¹⁹	-65/F -66/M	-Neck -Orbital globe wall	-Smoldering multiple myeloma and non-cirrhotic HTN -Gammopathy of unknown significance	IVIg (skin inflammation decrease)
Mahendran/2017 ²⁰	78/F	Periorbital and temple	Monoclonal gammopathy	Lenalidomide (clearance of the skin lesion)
Nguyen/2017 ²¹	52/F	Facial and lower extremity and hepatic lesions	Monoclonal gammopathy	Lenalidomide and dexamethasone (partial hepatic lesions improvement and lower extremity ulceration)
Olson/2018 ²²	44/F	periorbital	Monoclonal gammopathy and multiple myeloma	CyBorD and IVIG
Goyal/2018 ²³	42/F	periorbital	IgG monoclonal gammopathy	Rituximab/CyBorD/Michophenolate IVIG
Sagiv/2018 ²⁴	61/M	orbital	-	Rituximab
Fink/2018 ²⁵	Not available	-	CLL	-
Miola/2018 ²⁶	65/F	Lower eyelide	In the setting of Pelger-Huet anomaly	Not discussed
Schoenberg/2019 ²⁷	76/F	Shine/buttock and arm	Monoclonal gammopathy	Not discussed
Chakari/2019 ²⁸	89/F	periorbital	Planocellular carcinoma	Not discussed
Legrand/2019 ²⁹	-51/M -64/M	-Neck and limb -Trunk and limb	Monoclonal gammopathy	Not discussed
Mello/2019 ²	48/F	Face/cervical and clavicular	Smoldering multiple myeloma	Cyclophosphamide, dexamethasone and thalidomide

In this study, we reported the first case of cutaneous NXG with unique features in association with pulmonary involvement and solid organ cancer that was papillary thyroid cell carcinoma.

Comparing with the previous studies, which showed the most common site of the skin involvement was periorbital and the most hematologic disorders were monoclonal gammopathy, our patient had more lesions in the extraorbital facial area, in the scalp and upper trunk and had no hematologic disorders.

In cases that NXG accompanied by malignant manifestations, with the treatment of malignancy, the skin lesions often regressed, but in our patients, due to her non-acceptance in systemic treatment, poor compliance in order to follow up and treatment of thyroid cancer, atypical presentation of skin lesions and different therapeutic strategies, only skin lesions were managed. Therefore, her skin lesions were treated destructively with radiofrequency, that after one year. The lesions did not recur in their previous location, but in other areas of the face numerous other lesions were formed similar to the previous lesions.

Histiocytosis based on its type, may mimic a wide variety of

dermatologic disorders, so getting more familiar with different clinical presentations,^{30, 31} helps us to easier a better approach to the patients. In this regard, reporting different clinical presentations of histiocytosis especially atypical ones are of great value.

CONCLUSION

As regards to NXG is basically a skin disease, which sometimes has systemic complications and generally associated with life-threatening morbidity, and this morbidity is not always a hematologic malignancy, the patient with cutaneous histiocytosis should be considered and worked up for solid organ malignancies and for systemic involvements as well.

FUNDING

We have no funding source for this project.

DECLARATION OF CONFLICTING INTERESTS

All the authors declare that there is no conflict of interest for this project.

CONSENT FOR PUBLICATION

Written informed consent was obtained from the patients for publication of this case report and any accompanying images.

ACKNOWLEDGEMENT

We would like to show our gratitude to the Rasool Akram Medical Complex Clinical Research Development Center (RCRDC) for its technical and editorial assists.

AUTHOR CONTRIBUTIONS

Study concept and design: MG and AG

Acquisition of data: EB, AS, MR, NA, and AS

Drafting of the manuscript: MG, AG, and NS

Critical revision of the manuscript for important intellectual content: All authors

Study supervision: MG and AS

Histopathological examinations and reported images: NS and EB

All authors read and approved the final manuscript.

ETHICS APPROVAL

Institutional review board approval for case report is not required at our institution. To keeping ethical principles, name of the patient was not pointed in the paper. Written informed consent was obtained from the patient for publication of this case report and any accompanying images.

DATA AVAILABILITY

Data are available on reasonable request from the corresponding author.

REFERENCES

- Kossard S, Winkelmann RK. Necrobioticxanthogranuloma with paraproteinemia. *J Am Acad Dermatol.*, 1980; 3: 257-270.
- Mello RB, Vale ECS. Necrobioticxanthogranuloma associated with smoldering multiple myeloma: satisfactory response to cyclophosphamide, dexamethasone, and thalidomide. *Ann Bras Dermatol.*, 2019; 94(3): 337-340.
- Efebera Y. Necrobioticxanthogranuloma. *Clin Adv Hematol Oncol.*, 2011; 9: 700-701.
- Miguel D, Lukacs J, Illing T, et al. Treatment of necrobioticxanthogranuloma – a systematic review. *J Eur Acad Dermatol.*, 2017; 31: 221-235.
- Higgins LS, Go RS, Dingli D, et al. Clinical features and treatment outcomes of patients with necrobioticxanthogranuloma associated with monoclonal gammopathirs. *Clin Lymphoma Myeloma Leuk.*, 2016; 16: 447-452.
- Hilal T, Di Caudo DJ, Connolly SM, Reeder CB. Necrobioticxanthogranuloma: a 30 year single-center experience. *Ann Hematol.*, 2018; 97: 1471-1479.

- Wood AJ, Wagner MV, Abbott JJ, Gibson LE. Necrobioticxanthogranuloma: a review of 17 cases with emphasis on clinical and pathologic correlation. *Arch Dermatol.*, 2009; 145 (3): 279-284.
- Spicknall KE, Mehregan DA. Necrobioticxanthogranuloma. *Int J Dermatol.*, 2009; 48: 1-10.
- Winkelmann RK, Litzow MR, Umbert LJ, Lie JT. Giant cell granulomatous pulmonary and myocardial lesions in necrobioticxanthogranuloma with paraproteinemia. *Mayo Clin Proc.*, 1997; 72: 1028-1033.
- Umbert I, Winkelmann RK. Necrobioticxanthogranuloma with cardiac involvement. *Br J Dermatol.*, 1995; 133: 438-443.
- Novak PM, Robbins TO, Winkelmann RK. Necrobioticxanthogranuloma with myocardial lesions and nodular transformation of the liver. *Hum Pathol.*, 1992; 23: 195-196.
- Hunter L, Burry AF. Necrobioticxanthogranuloma: a systemic disease withparaproteinemia. *Pathology.* 1985; 17: 533-536.
- Finan MC, WinkelmannRK. Histopathology of Necrobioticxanthogranuloma with paraproteinemia. *J Cutanpathol.*, 1987; 14 (2) 92-99.
- Mehregan DA, Winkelmann RK. Necrobioticxanthogranuloma. *Arch Dermatol.*, 1992; 128: 94-100.
- Ugurlu S, Bartley GB, Gibson LE. Necrobioticxanthogranuloma: long-term outcome of ocularand systemic involvement. *Am J Ophthalmol.*, 2000; 129 (5) 651-657.
- Keorochana N, Klonarongrian K, Satayaseenturn K, Chainaninuy S. Necrobioticxanthogranulomascleritis in acase of granulomatosis (Wegener's granulomatosis). *Int Med Case Rep J.*, 2017; 10: 123-329.
- Lukacs J, Goetze S, ElsnerP. Periocular necrobioticxanthogranuloma successfully treated with intravenous immunoglobulin. *Acta DermVenereol.*, 2017; 97: 754-755.
- Edwards LR, Kidd LL, Gru AA, Wilson BB. Necrobioticxanthogranuloma in association with chronic myelomonocytic leukemia. *Br J Dermatol.*, 2017; 176:16.
- Vignan M, Placais L, Malphettes M, et al. Non-cirrhotic portal hypertension in necrobioticxanthogranuloma associated with monoclonal gammopathy. *JEADV.*, 2017.
- Mahendran P, Wee J, Chong H, Natkunarajah J. Necrobioticxanthogranuloma treated withlenalidomide. *Clin ExpDermatol.* 2018;43(3):345-347.
- Neguyen BD. Hepatobiliary and pancreatic: Hepatic necrobioticxanthogranuloma. *J Gastroenterol Hepatol.* 2017; 32(10): 1667.
- Olson RM, Harrison AR, Mattry A, Mokhtarzadeh A. Periorbital Necrobiotic Xanthogranuloma Successfully Treated With Intravenous Immunoglobulin. *Case Rep Ophthalmol.*, 2018; 9: 70-75.
- Goyal A, O'Leary D, Vercellotti G, Miller D, McGlave P. Intravenous immunoglobulin for treatment of necrobioticxanthogranuloma. *Dermatol Ther.*, 2019; 32(1): e12744.
- Sagiv O, Thakar SD, Morrell G, Tetzlaff MT, Esmaeli B. Rituximab monotherapy is effective in treating orbital necrobioticxanthogranuloma. *Ophthal Plast Reconstr Surg.*, 2018, 34(1): e24-e27.
- Fink C, Schneiderbauer R, Hartschuh W, Enk A, Toberer F. Necrobioticxanthogranuloma associated with chronic lymphocytic leukemia. *Int Dermatol.*, 2018; 57 (6): 719-720.
- Miola AC, Marques MEA Miot HA. Necrobioticxanthogranuloma (without paraproteinemia) in a patient with Pelger-Huet anomaly. *Int Dermatol.*, 2019; 58 (4): E93-E94.
- Schoenberg E, McGuinn K, Connolly D, Yang Sh. An atypical presentation of rare disease. *JAAD Case Heports.* 2019; 5: 255-257.
- Chakari W, Rangatchew F, Toyserkani NM, Pilt AA. Necrobioticxanthogranuloma misdiagnosed as a planocellularcarcinoma. *Ugeskr Laeger.* 2019; 181(14).
- Legrand A, Jullie ML, Ly S, Beylot-Barry M, Viallard JF, Calonje J, et al. Extrafacialnecrobioticxanthogranuloma and monoclonal gammopathy:

two cases. *Int Dermatol.*, 2019; 58 (6): e112-e114.

Ghanadan A, Kamyab K, Raezani M, et al. Indeterminate cell histiocytosis: report of the case. *Acta Med Iran.*, 2014; 52(10): 788-90.

Ghandi N, Daklan S, Goodarzi A, Kamyab K, Ghanadan A. Generalized eruptive histiocytosis: A case report. *Iranian J Dermatol.*, 2015; 18(1): 33-35.