

# EXPERIMENTAL INVESTIGATION ON THE ORAL AND TOPICAL APPLICATION OF ALOE VERA IN WOUND CARE

Wael Waleed Mustafa<sup>1</sup>, Samer Shukur Moahammed<sup>2</sup>

<sup>1,2</sup>Department of Pharmacology and Toxicology, Faculty of Pharmacy, Al-Rafidain University College, Baghdad, Iraq.

Email: wael.walid@ruc.edu.iq

DOI: 10.47750/pnr.2022.13.S01.54

## Abstract

The inherent medicinal properties of Aloe vera, has been deliberated on the wound healing process from centuries. The experimental and human evidences display the prompt utilization of the herb for several purposes like skin moisturizing, wound healing, frostbite and ischemic skin insults. The vasodilatory, anti-inflammatory, proliferative and antimicrobial actions were revealed in several experimental animal models in different invitro conditions. Accordingly prevailing studies explored substantial evidence for its clinical usefulness in wound care. The presented study has been motivated by the adorable characteristics of Aloe vera and investigated the topical and oral incorporation of the formulation briefly. For the purpose, 24 rats were categorized into four groups which are control, oral and topical (combined) treatment, oral treatment group and topical treatment group. After treatment the study compared the healing process within the four groups in terms of wound healing score, treatment alignment score, treatment maturity, vascularity and perivascular edema. The results revealed that combine effect of oral and topical formulation showed enhanced outcomes in nearing the normal stage. Hence the paper suggested that the integrated effect of oral and topical formulation will produce improved results in wound healing with aloe vera.

**Keywords:** Aloe vera, topical, oral, wound healing, vascularity OVID-19, Myalgia, Arthralgia, Neuropathic, Pain Symptoms, Prevalence, Iraq.

## 1. INTRODUCTION

Aloe barbadensis[1] consists more than two hundred compounds in which nearly 75 possess biological activity. Wound healing using Aloe Vera was observed mainly due to increased oxygenation and increased blood supply. These activities will be involved in the stimulation of collagen proliferation and fibroblast activity. Further wound healing is promoted by growth factors in aloe vera like auxin, gibberellins and mannose phosphate that binds to insulin like growth factor receptor. The leaves of the plant comprises a diversified compounds that includes anthrones, anthraquinones, carbohydrates, chromones, glycoproteins, proteins, organic acids, aminoacids, vitamins, sugars and minerals. The poly-morpho nuclear leukocytes in Aloe vera prohibits the synthesis of free oxygen radicals. The mannose 6 phosphate[2] is highly responsible for wound healing [3]and observed to be correlated with elevated levels of dermatan surface and hyaluronic acid. This compound is also responsible for the stimulation of collagen production and consequently for the formation of scar during healing[4]. The oxygen concentration at the infected site has been increased by the vitamin c components in aloe vera. Consequently Aloe vera has the ability to induce relief from swelling or bleeding of gums[5], and act as proven antiseptic and antifungal agent [6]. Additionally, acemannan consisting of long chain acetylated mannose activates the macrophages and stimulates the production of fibrogenic cytokines for healing. The carboxypeptidase in the plant deactivates the bradykinin and provided pain relief. C-glucosyl chromone can prohibit the cyclooxygenase pathway thereby reducing the synthesis of prostaglandin E2 from the arachidonic acid[7, 8]. The three aloesin derivatives such as isorabaichromone, p-coumaroylalosin and feruoylaloetin are observed to be responsible for the antioxidant activities. For adequate documentation of wound healing with the above described inherent properties of aloe vera,[9] [10, 11] two important formulation has been considered in this study. Topical formulation and oral formulation were experimentally analyzed in the present study to reveal the possible benefits of both the methods. Further the combination of oral and topical formulation was also analyzed to reveal its betterment. The main contribution of the study is to

- To categorize the study population into four groups which are control, oral and topical (combined) treatment, oral treatment group and topical treatment group.
- To reveal the treatment benefits of aloe vera formulation on the categorized groups.
- To compare the healing process within the four groups in terms of wound healing score, treatment alignment score,

treatment maturity, vascularity and peri edema.

- To enumerate the better mode of aloe vera application for wound healing.

## 2. MATERIALS AND METHODOLOGY

### 2.1. Aloe vera Gel Preparation and Injury induction

The study collected the completely matured leaves of aloe vera were cultivated in the botanical garden. The leaves were cut to remove the rind. After that the colorless parenchyma has been grounded with the help of blender and subjected to centrifugation at 4°C for 30 minutes for removing the fibers. Followed by this step the aloe vera was transformed to powder after freeze-drying. The powder transformation increases the shelf life of aloe vera. The aloe vera powder is dissolved in 0.9% sterilized saline water to form a solution with 50 mg concentration of aloe vera per milliliter of the saline. This solution has been utilized for in vivo experimentation of topical and oral application of the extract on the cutaneous wounds of mice. The study selected the particular concentration with reference to the inherent wound healing molecular property described in the previous studies.

#### Injury Induction

The animals were subjected to anesthesia via intra-muscular injection. For the purpose, 2 milligram/kilogram hydrochloric acid was used as the premedication and 60 milligram/kilogram of ketamine hydrochloric acid was used to become the rats to be anesthetized.<sup>33</sup> The anesthesia treatment inhibits the animal movement for at least 10 minutes after prior administration of the above-described anesthesia. This also confirms that the animals were left freely without restraint. The dorsum back hair was clipped and scrubbed before careful incision. A full thick rectangular skin (2 X 2 cm) comprising dermis, epidermis and subcutaneous fat has been removed by incision and dissection. This portion has been processed to create a wound infection on dorsum back of the investigated animals.

### 2.2. Study Design and Therapeutic Regimens:

The study animals were categorized randomly into four groups.

- Group 1: Control group – 6 rats that were treated on a daily basis by applying the isotonic 0.9% saline solution for a period of 10 days.
- Group 2: Oral treatment group – 6 rats, In this group, 50 mg/kg concentration of aloe vera were induced orally to the wound- infected rats.
- Group 3: Topical treatment group – 6 rats. In this group, 50 mg/kg concentration of aloe vera were induced orally to the wound - infected rats
- Group 4: Oral and Topical treatment group – 6 rats. In this group, 50 mg/kg concentration of aloe vera were induced orally and topically to the wound-infected rats

These animals were subjected to the topical application of high dosage aloe vera (50 milligrams/milliliter of saline) for a period of 10 days. Followed by this treatment the animals were euthanized through intra-cardiac administration of 50mg/kg of sodium thiopental and 1 mg/kg of pancuronium for inducing coma and death.

The study evaluated the gross morphology of the wounded area on a regular basis. Gross morphology of the wound area of all the animals was assessed daily.

### 2.3. Collection of sample

The full thickened skin samples has been dissected and being harvested from the wound region and investigated for biochemical and histological assessment.

### 2.4. Hematoxylin and eosin - staining procedure

Hematoxylin and eosin stain is considered as the principal staining method in the field of histology. It is extensively utilized in medical diagnosis and regarded as the gold standard for the determination of tissues. It also provide significant information regarding the shape, pattern and the cell structure. The steps employed are dewaxing, dehydration, processing with hematoxylin, cell differentiation, bluing, eosin, dehydration, clearing and cover with cover slip followed by visualization.

### 2.5. Histo-morphometric Analysis

After fixing the cells in 10% of neutral buffered formalin, the skin blocks were washed and de-hydrated in a grade series of ethanol solution. Consequently the tissues are cleared and being embedded in the paraffin wax and sectioned at 5 micrometer in thickness stained with eosin and hematoxylin. The processed tissues are then examined with the help of light microscope.

The following tables 1 to 5 represents the scoring standards for defining the tissue alignment, wound surface morphology, tissue maturation, vascularity and perivascular edema

**Table1:** Scoring standards of wound surface

Scoring value	Stage	Epidermis morphology	Wound edge distance in Mm
4	Highly immature	Formation of no epidermis	Less than 2000
3	Immature	20% of regenerated epidermis	Greater than 500
2	Mature	50% of the regenerated epidermis	Greater than 2000
1	Highly mature	80% of the regenerated epidermis	Greater than 1000
0	Near to normal	Fully regenerated	Greater than 500

**Table 2:** Scoring standards of tissue alignment

Scoring value	Stage	Collagen direction	Fibroblast direction
4	Highly immature	Diagnostic orientation has not been found	Orientation was not found
3	Immature	The orientation is immature. The collagen fibers possess certain orientation but are not longitudinal in pattern	Less than 50% of the tissues are in the direction of collagen fibers
2	Moderate Mature	The tissues are aligned in more than one longitudinal direction	Less than 50% of the tissues are in the direction of collagen fibers
1	Highly mature	The tissues are mostly aligned in one longitudinal direction. However certain areas are observed with un-identified collagen fibers	Less than 75% of the tissues are in the direction of collagen fibers
0	Near to normal	The tissues are aligned in one longitudinal direction	The collagen fibers are parallel

**Table 3:** Scoring standards for tissue maturation

Scoring value	Stage	Cell populations	Collagen fiber appearance
4	Highly immature	Predominant inflammatory cells	Small sized and non-dense collagen fibers are observed
3	Immature	Less than 75% of the fibroblasts	Medium sized and non-dense collagen fibers are observed
2	Moderate Mature	Less than 25% of the fibrocyte	Medium sized and dense collagen fibers are found in the range if less than 75%
1	Highly mature	Less than 50% of the fibrocyte	Large sized and dense collagen fibers are found in the range if less than 50%

0	Near to normal	Less than 75% of the fibrocyte	Large sized and dense collagen fibers are found in the range if less than 75%
---	----------------	--------------------------------	---

**Table 4:** Scoring standard for vascularity

Scoring value	Stage	Description
4	Highly immature	Small sized vessels within the range of less than 30 vessels
3	Immature	Consists of 21 to 30 vessels in which less than 20% are large sized. The remaining 80% are small sized.
2	Mature	Consists of 11 to 20 vessels in which 50% are large sized
1	Highly mature	Consists of 5 to 10 vessels in which 70% are large sized
0	Near to normal	Upto 4 vessels with same diameter

**Table 5:** Scoring standards of Peri-vascular edema (10 x observation)

Scoring value	Stage	Description
3	Immature	Edema was observed around large vessels
2	Moderate Mature	Edema was observed around medium vessels
1	Highly mature	Edema was observed around small vessels
0	Near to normal	Edema has not been observed around the vessels

### 3. RESULTS AND DISCUSSION

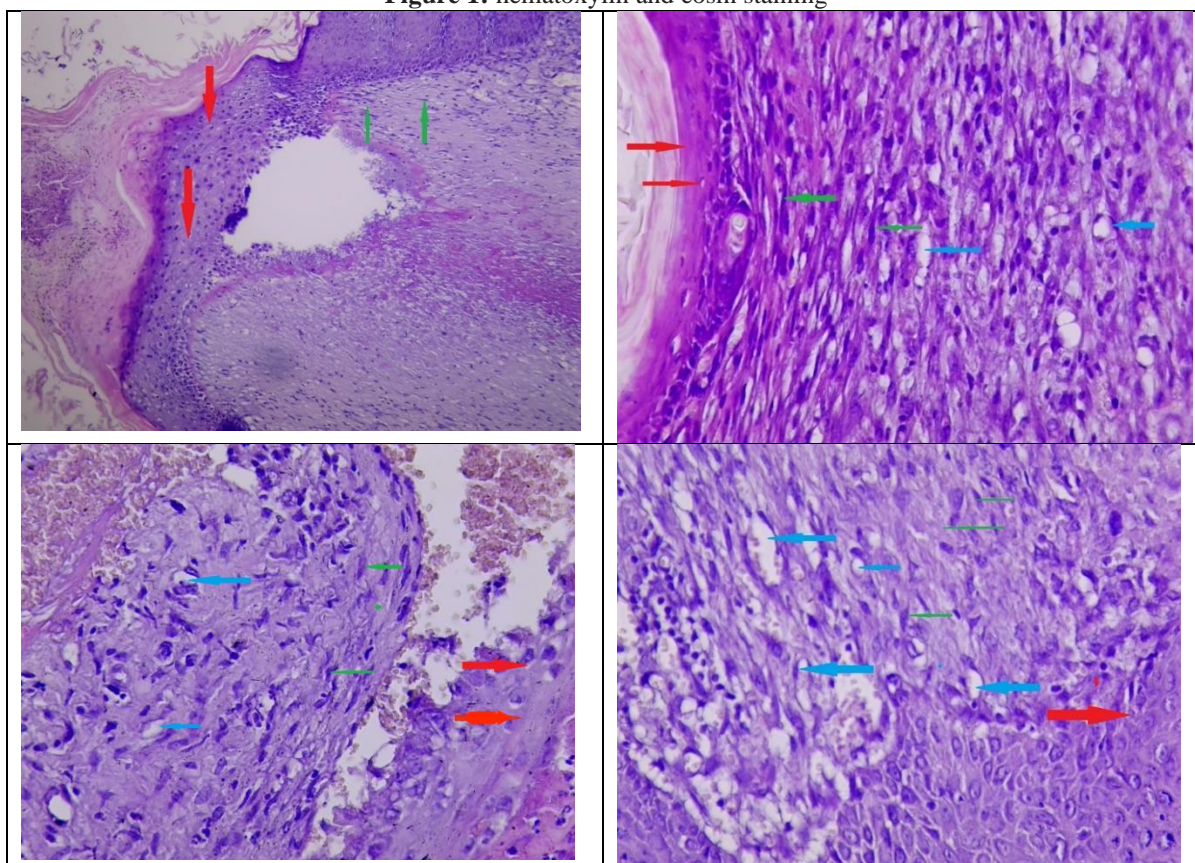
This section describes the result and discussion briefly. The major findings of the study relies on the scores of wound surface, tissue alignment and maturation, vascularity and perivascular edema. The table 6 deliberates the overall tabulation of estimated scores for control group (6 numbers), oral and treatment group (6 numbers), oral treatment (6 numbers), and topical treatment (6 numbers).

**Table 6:** Histomorpho-metric variable scoring

Group	Wound Surface	Tissue Alignment	Tissue Maturation	No. of Vessels	Perivascular edema
Control 1	2	2	1	1	1
Control 2	4	3	1	1	1
Control 3	2	1	1	2	1
Control 4	3	2	1	1	1
Control 5	2	2	1	2	1
Control 6	2	1	1	2	1
<b>ORAL GROUP</b>					
Oral 1	0	0	0	1	1
Oral 2	0	0	0	1	1
Oral 3	0	1	2	1	1
Oral 4	0	0	2	1	1
Oral 5	0	1	1	1	1
Oral 6	0	0	1	0	1

TOPICAL GROUP					
Topical 1	0	0	1	0	1
Topical 2	0	2	1	0	1
Topical 3	0	0	1	1	1
Topical 4	0	1	1	1	1
Topical 5	0	2	1	0	1
Topical 6	0	1	1	1	1
ORAL AND TOPICAL GROUP					
Topical and Oral1	1	0	0	0	0
Topical and Oral2	0	1	1	0	1
Topical and Oral3	0	1	1	0	1
Topical and Oral4	0	1	1	0	0
Topical and Oral5	0	0	1	0	0
Topical and Oral6	0	0	1	0	0

**Figure 1:** hematoxylin and eosin staining



The red color arrow mark displays the epidermis region and the green color arrow displays the collagen fiber and the fibroblast region. Further the blue color displays the granulation tissue or the capillaries. The result of hematoxylin and eosin staining represented that the combined oral and topical treatment decreased the cellularity and inflammation level. Further it increased

the granulation and epithelialization thereby enhanced the remodelling of the scar tissues by means of aligning the collagen fibres and hence the cells are enhanced the maturation and regeneration of the epithelial tissues and consequently decreased the scar tissue size at 30 DPI.

### 3.1 Histomorpho-metric variable scoring

The following table 7 represents the Histomorpho-metric variable scoring

**Table 7:** Wound surface assessment

Group	Wound Surface (Control)	Wound Surface (Oral)	Wound Surface (Topical)	Wound Surface (Oral and Topical)
1	2	0	0	1
2	4	0	0	0
3	2	0	0	0
4	3	0	0	0
5	2	0	0	0
6	2	0	0	0

The table7 deliberated the histomorphometric variable (wound surface) assessment in the control group in which the rats were treated with isotonic 0.9% saline for 10 days. When investigating wound surface majority of the control group exhibited the score 2, that implies the maturity of the maturity of the wounds, with a morphology of less than 50% regenerated epidermis. Further the distance between the edge and the wound is found to be greater than 2000 micrometer. Meanwhile two of the control group exhibited highly immature and immature wound surface. These observations depicted that the application of isotonic 0.9% saline for 10 days has no improvement towards positive treatment in the control group. The wound surface for the oral, topical and combined group stated that the properties of aloe vera treated effectively and recovered nearly to the normal surface. However the study observed no differentiation between oral topical and combined groups

**Table 8:** Evaluation of tissue alignment

Group	Tissue Alignment (Control)	Tissue Alignment (Oral)	Tissue Alignment (Topical)	Tissue Alignment (Oral and Topical)
1	2	0	0	0
2	3	0	2	1
3	1	1	0	1
4	2	0	1	1
5	2	1	2	0
6	1	0	1	0

The table8 displayed the tissue alignment among the investigated groups. It was observed that in control group, most of the rats acquired stage 2 which is moderately mature that represents the collagen tissues are aligned in more than one longitudinal direction. However worsened immature stage 3 have also observed in the control group. Accordingly the combined effect and oral group attained outperformance and attained near to normal stage. However no strongly treated outcomes has been revealed among topical group. The result suggest that tissue alignment has been attained to near normal stage in orally treated group and combined group.

**Table 9:** Evaluation of tissue maturation

Group	Tissue Maturation (Control)	Tissue Maturation (Oral)	Tissue Maturation (Topical)	Tissue Maturation (Oral and Topical)
1	1	0	1	0
2	1	0	1	1
3	1	2	1	1
4	1	2	1	1
5	1	1	1	1
6	1	1	1	1

The table9 deliberates the tissue maturation of the investigated groups and found that combined group possess greater adherence to normal stage when compared to other groups. Hence in combined group the tissues are aligned in one longitudinal direction effectively and the collagen fibers are observed to be parallel.

**Table 10:** Evaluation of vascularity

Group	No. of Vessels (Control)	No. of Vessels (Oral)	No. of Vessels (Topical)	No. of Vessels (Oral and Topical)
1	1	1	0	0
2	1	1	0	0
3	2	1	1	0
4	1	1	1	0
5	2	1	0	0
6	2	0	1	0

The table10 defines the vascularity among the investigated groups and observed that combined group outperformed the other groups to reach near normal. Meanwhile it is also observed that topical group has better result than the oral group.

**Table 11** Evaluation of Perivascular edema

Group	Perivascular edema (Control)	Perivascular edema (Oral)	Perivascular edema (Topical)	Perivascular edema (Oral and Topical)
1	1	1	1	0
2	1	1	1	1
3	1	1	1	1
4	1	1	1	0
5	1	1	1	0
6	1	1	1	0

The table11 provides information about the perivascular edema among the investigated groups and observed that combined group outperformed the other groups to reach near normal. Meanwhile it is also observed that topical group and the oral group obtained similar results.

## 4. DISCUSSION

The wound healing application of the medicinal plant Aloe vera was confirmed by the details reviewed in the articles, [12-14], the effects of oral administration of Aloe vera had evaluated for the excisional cutaneous injuries in Sprague Dawley rats. SD (Sprague Dawley) rats reminded perpetrated with the excisional injuries and treated with Aloe vera orally or the injuries kept untreated. In contrast to this the healthy rats kept as control group. From 7th to 21st day the injuries were measured. The rats treated with Aloe Vera, healed wounds earlier were the untreated rats shown a gradual improvement in the wound region and collagen content. VEGF and IGF-1 in skin were also improved by the use Aloe vera. Along with the indication of improved bone marrow in angiogenesis. The increased notation of genes for CXCR-4 and SDF-1 (chemotaxis) in bone marrow and skin are expressed from the RT-PCR analysis. Aloe vera improved the healing by increase of improving angiogenesis, chemotaxis and collagen content. The study [15] expressed that the Aloe vera enriched oral mucosa wound healing by the TGF  $\beta$ 1 marker. There was no substantial reduction of inflammatory cell. The study [16] examined the in vitro cell immigration of human gingival fibro-blasts and anti-microbial effects of an herbal toothpaste that contains sodium chloride and Aloe Vera. The oral health care promotion need to be consider the formulation of non-herbal toothpaste than the alternate usage of an herbal toothpaste. Moreover, before suggesting it for patients uses, further study on the clinical side need to be done. These statement are related to the results of our study. The research [17] examined whether the Aloe vera treated through oral have the efficacy to enhance the umbilical vein transplantation and inhibit the expression of matrix metallo-proteinases in injury healing of diabetic mice. Suggested that the efficacy of HUVEC transplantation on diabetic wound angiogenesis was enhanced by the oral Aloe vera, partly glycemic control were also improved. Via inhibition of MMP-9 and MMP-2 the oral Aloe vera endorsed the wound therapeutic in diabetic. The examine [18] expressed that Aloe vera showed effective result in chronic disease than the acute wounds. For treating the first and second degree burns the Aloe vera was used and this result in the recovery time reduced to 9 days. Than the current treatment, dressing once or twice with Aloe vera per day results better improvement in recovery, including 1% ointment of silver sulfadiazine, framycetion cream and dressing with petroleum jelly gauze. It has resulted in the lack of itching and redness, reduction in recovery time and the wound infection absence. From the past to present Aloe vera have been used for treating burns and it most commonly know as the first aid plant and burn tree. Due to the increased immune, anti-inflammatory, anti-viral effects, reduced histamine activity and anti-bacterial properties of Aloe vera and it speed up the curative progression of the burn wounds. The result of the present study showed that Aloe vera was solidly measured as the ideal dressing. Majority of the research were performed in the grade 1 and grade 2 ulcer, very few have performed on grade 3 ulcers. The latter might be owing to the complete chunkiness skin loss in grade 3 and likely onset of wound infection

The study [19] aimed to compare the result of triamcinolone acetonide 0.1% and Aloe vera gel in minor ulcer (aphthous stomatitis) affected person. After the informed consent 34 affected person with the symptoms of aphthous stomatitis and clinical signs were comprised for the randomized solitary blinded study. Topical Aloe vera gel were received by group A patients and (Kenacort oral paste) topical triamcinolone acetonide 0.1% were given to group B and treated 3 times per day for 7 days or till the complete heal of ulcer. At each, the parameters like burning sensation, pain and ulcer size are recorded. Aloe vera has a large spectrum of uses and unique properties. It was an auspicious mediator in oral-lesion treating on the oral medicine sector. It can also be used as a medicine to the patients those are found allergic to steroid medicine. The examine [20] conducted a randomized, double blind and controlled trial. Included the patients those were done split-thickness skin graft harvesting in thigh region. For the pain evaluation visual analogue scale score was used and assessed the complete epithelialization. Topical Aloe vera gel ominously established speeding up in split thickness skin graft contributor site curing but not much efficient in the pain relief. The research [21] explored the effect of skin wound healing by topical Aloe vera. The outcome represented that the 1% in topical application and 2% of Aloe vera gel effectively reduced the wound percentage, infiltration, leucocytes, CD8+ lymphocytes expression, and angiogenesis increased the thickness of epidermal and the CD4+ lymphocytes expression. There was no noteworthy variance in the amount of fibroblasts in all the measured groups. The 2% of Aloe vera cream and 1% of topical application have the potential of healing wound via their ability to increase the percentage of CD8+ and CD4+ lymphocytes in the injury region.

The study [22] examined the combination usage of the synergistic properties of hindering thromboxane and I<sub>2</sub> injecting prostaglandin presented outcome in an level advanced ratio of skin flap endurance by endorsing improved perfusion to ischemic flap tissue related to control. The greatest effect on wound healing, morbidity reduction in dermal wound with ailed ischemia, and tissue survival are shown in the use of Aloe vera combined with the another particular (methimazole) anti-thromboxane agent.

## 5. CONCLUSION

Wound healing is considered as an intricate process in which the tissues repairs itself after an injury. However this process sometimes fail due to interruption at any stage. There exists several factors that includes anaemia, diabetes, nutritional

deficiency, hematoma and local infections that disrupts the wound healing process. Several herbal plants has potential to heal the wound in which our study has been motivated by the greater medicinal characteristics of Aloe vera. The study divided 24 rats into four groups which are control, oral and topical (combined) treatment, oral treatment group and topical treatment group. The wound surface, treatment alignment score, treatment maturity, vascularity and perivascular edema were assessed to reveal the results. The results revealed that the combined effect of oral and topical formulation outperformed in wound healing.

## REFERENCES

1. Drudi, D., et al., Aloe barbadensis miller versus silver sulfadiazine creams for wound healing by secondary intention in dogs and cats: A randomized controlled study. *Research in veterinary science*, 2018. 117: p. 1-9.
2. de Jesus Azevedo, J.S., et al., Is aloe vera effective for wound healing? The state of the art.
3. Singh, B., et al., Phytoconstituents and biological consequences of: A focused review Aloe vera. *Asian Journal of Pharmacy and Pharmacology*, 2018. 4(1): p. 17-22.
4. Tiwari, M. and M. Upadhyay, The medicinal plant components and applications (Aloe vera). *Journal of Medicinal Plants Studies*, 2018. 6(3): p. 89-95.
5. Mazzarello, V., et al., Treatment of acne with a combination of propolis, tea tree oil, and Aloe vera compared to erythromycin cream: two double-blind investigations. *Clinical pharmacology: advances and applications*, 2018. 10: p. 175.
6. Al-Maweri, S.A., et al., Aloe vera in treatment of oral submucous fibrosis: A systematic review and meta-analysis. *Journal of Oral Pathology & Medicine*, 2019. 48(2): p. 99-107.
7. Almashhadani, H.A., et al., Corrosion inhibition behavior of expired diclofenac Sodium drug for Al 6061 alloy in aqueous media: Electrochemical, morphological, and theoretical investigations. *Journal of Molecular Liquids*, 2021. 343: p. 117656.
8. Kadhim, M.M., et al., Effect of Sr/Mg co-substitution on corrosion resistance properties of hydroxyapatite coated on Ti-6Al-4V dental alloys. *Journal of Physics and Chemistry of Solids*, 2022. 161: p. 110450.
9. Upadhyay, R.K., Nutraceutical, therapeutic, and pharmaceutical potential of Aloe vera: A review. *International Journal of Green Pharmacy (IJGP)*, 2018. 12(01).
10. Ranjbar, R. and A. Yousefi, Effects of aloe vera and chitosan nanoparticle thin-film membranes on wound healing in full thickness infected wounds with methicillin resistant *Staphylococcus aureus*. *Bulletin of Emergency & Trauma*, 2018. 6(1): p. 8.
11. Shekhawat, D., et al., Aloe vera-A miracle plant for dentistry. *Journal of Advanced Clinical and Research Insights*, 2021. 8(4): p. 94-100.
12. Farrugia, C.-J.E., et al., The use of Aloe vera in cancer radiation: An updated comprehensive review. *Complementary Therapies in Clinical Practice*, 2019. 35: p. 126-130.
13. Liang, J., et al., Aloe vera: a medicinal plant used in skin wound healing. *Tissue Engineering Part B: Reviews*, 2021. 27(5): p. 455-474.
14. Ali, F., et al., Oral administration of Aloe vera ameliorates wound healing through improved angiogenesis and chemotaxis in Sprague Dawley rats. *Current Pharmaceutical Biotechnology*, 2021. 22(8): p. 1122-1128.
15. Sugiaman, V.K., et al., Oral Mucosa Wound Healing Activities of Aloe vera Extract: in vivo Study. *Journal of International Dental & Medical Research*, 2018. 11(3).
16. Vajrabhaya, L.-o., et al., The efficiency of natural wound healing and bacterial biofilm inhibition of Aloe vera and Sodium Chloride toothpaste preparation. *BMC Complementary Medicine and Therapies*, 2022. 22(1): p. 1-10.
17. Kaewrsisung, S., et al., The effects of oral Aloe vera on the efficacy of transplanted human endothelial cells and the expression of matrix metalloproteinases in diabetic wound healing. *Heliyon*, 2021. 7(12): p. e08533.
18. Wu, J., et al., Safety evaluation of Aloe vera soft capsule in acute, subacute toxicity and genotoxicity study. *PloS one*, 2021. 16(3): p. e0249356.
19. Giroh, V.R., et al., Efficacy of aloe vera and triamcinolone acetone 0.1% in recurrent aphthous stomatitis: A preliminary comparative study. *Journal of Indian Academy of Oral Medicine and Radiology*, 2019. 31(1): p. 45.
20. Burusapat, C., et al., Topical Aloe vera gel for accelerated wound healing of split-thickness skin graft donor sites: A double-blind, randomized, controlled trial and systematic review. *Plastic and reconstructive surgery*, 2018. 142(1): p. 217-226.
21. Prakoso, Y.A., The effects of Aloe vera cream on the expression of CD4+ and CD8+ lymphocytes in skin wound healing. *Journal of tropical medicine*, 2018. 2018.
22. Yogesh Hole et al 2019 *J. Phys.: Conf. Ser.* 1362 012121
23. Zeng, W.M., et al., Aloe vera—Mechanisms of Action, Uses, and Potential Uses in Plastic Surgery and Wound Healing. *Surgical Science*, 2020. 11(10): p. 312.