

# A Study Of Sex Determination Of Human Hip Bone Using Coxal Index, Ischio Pubic Index And Greater Sciatic Notch

Sarath kumar S<sup>1</sup>, Gnanavel A<sup>2</sup>, S.Saravana kumar<sup>3</sup>, Maheswari K<sup>4</sup>, Lalitha R<sup>5</sup>, Thamarai selvi A<sup>6</sup>, Jeniffer deborah B<sup>7</sup>

Post graduate<sup>1</sup>, Department of Anatomy, Meenakshi Medical College Hospital & RI  
Associate professor<sup>2,5</sup>, Department of Anatomy, Meenakshi Medical College Hospital & RI  
Assisat professor<sup>3,6</sup>, Department of Anatomy, Meenakshi Medical College Hospital & RI  
Professor & HOD<sup>4</sup>, Department of Anatomy, Meenakshi Medical College Hospital & RI  
Senior resident<sup>7</sup>, Department of Anatomy, Meenakshi Medical College Hospital & RI

Corresponding Author:

Dr.A.Gnanavel, Associate Professor, Department of Anatomy, Meenakshni Medical College Hospital & Research Centre, Kancheepuram - 631552 Tamilnadu

DOI: 10.47750/pnr.2022.13.S01.265

## Abstract

Accurate sexing of skeletal remains is a vital part of any medicolegal investigation and a challenge to physical anthropologists. Hip bone is considered as the most reliable sex indicator in the human skeleton. Standards of morphometric sex difference in the skeleton may differ with the population. The ability to determine sex from unknown skeletal remains is important. The hip bone is considered as an ideal bone for sex determination as it provides the highest accuracy. The human skeletal remnants have been researched extensively in forensic anthropology for medico-legal significance (1). Coxal index, Ischio-pubic index and the width of greater sciatic notch are the reliable parameters for sex determination of hip bone. Therefore the study of sexual dimorphism of bones in human population is of interest not only for the anatomist but also forensic experts and anthropologists.(2)

**AIM :** To determine the sex of the individual from the hip bone using Coxal index, Ischio pubic index and the width of the greater sciatic notch,.

## MATERIALS & METHODS :

Dry human disarticulated hip bones were collected in the Department of Anatomy Meenakshi medical college and research institute. For the study 75 human dry Hip Bones(36 male and 39 female) of known sex were taken. Adult Dry hip bones which were ossified having no deformities and congenital anomalies were taken for the study. The Coxal index, Ischio pubic index and the width of the greater sciatic notch were calculated. The mean and standard deviation were calculated for its significance.

## RESULTS:

The mean value of Coxal index of male hip bone was  $69.65 \pm 5.1$  and in female  $71.8 \pm 4.7$  the sex differences in the mean value of female is more than male and it is significant. Similarly, the Ischio pubic index and the width of greater sciatic notch are significantly higher in female than male.

**CONCLUSION:** Hip bone is considered as the ideal bone for identification of sex next to the skull. Many parameters have been reviewed and found useful for the sex determination from the hip bone. Many studies emphasized the importance of the metric

parameters of the hip bone. Our study specifically highlighted the determination of the sex from the hip bone using Coxal index, Ischiopubic index and width of the greater sciatic notch in Indian population.

**Key Words:** Coxal index, greater sciatic notch, Ischio pubic index

**Abbreviations:** CI= Coxal index, GSN= greater sciatic notch.

---

## INRODUCTION

The individuals can be identified depending on their age, sex, ethnic background and stature. The features of any human skeletal remains the same even after death. The sexual dimorphism of the skeletal remnants is of great interest for anatomists, forensic experts and anthropologist. The average dimensions of each part of the innominate bones will help in early interpretation of disputed sex by forensic experts (16).

Hip bone is considered as the most reliable bone for sex determination. Traditional visual method of examination of hip bone will not given measurements of the bone. Hence a standard method needs to be adopted by the expert people to identify the sex of the individual with the skeletal remnants. (17) According to Gray's Anatomy, (18) The hip bone is irregular in shape and presents a constricted central part which carries a cupshaped depression, the acetabulum, on the outer surface. The bone is expanded above and below the acetabulum, and exhibits an oval or triangular obturator foramen below and in front of the acetabulum. The hip bone consists of one dorsal component, the ilium and two ventral components, the ischium and the pubis. The three components join at the acetabulum which is separated initially by a triradiate cartilage and the latter is then replaced by bone. The acetabulum articulates with the head of femur to form

the hip joint. The present study has been planned to measure Coxal index, Ischiopubic index and the width of the greater sciatic notch as the indicators for the identification of the sex of the person using hip bone. These indicators may significantly help in differentiating the sex of human hip bones which is useful for the experts. Measurements taken on both right and left sided bones indicate that there is bilateral asymmetry in hip bones. Similar studies have been conducted in different races. The present study will hence provide valuable information about the hip bones in Indian population.

## MATERIALS & METHODS:

Dry human disarticulated hip bones were collected in the Department of Anatomy, Meenakshi medical college and research institute. For the study 75 human dry Hip bones(36 male and 39 female) of known sex were taken.

**INCLUSION CRITERIA:** The adult dry human hip bones of known sex that were fully ossified without any bony deformities.

**EXCLUSION CRITERIA:** Deformed bones, malunited bones and bones with congenital anomalies.

### Length of the Hip Bone :

The length was measured from the most superior point on the iliac crest to a plane drawn along the inferior surface of ischium. The measurement was taken using osteometric board and the length was recorded in cms. The most superior point of the iliac crest was placed along the fixed side of the board and the inferior surface of ischium along the movable arm.

**Width of the Hip bone:** The maximum distance from the anterior superior iliac spine to posterior superior iliac spine was considered as the width of hip bone. The measurement was taken using an osteometric board and the length was recorded in cms. The posterior superior iliac spine was kept in contact with the fixed side of the board and anterior superior iliac spine along the movable arm.

**Coxal index:** (5,7) :  $\text{Width of hip bone} / \text{Length of hip bone} \times 100$

**Ischio-pubic index:** (3) :  $\text{Length of Pubis} / \text{Length of Ischium} \times 100$

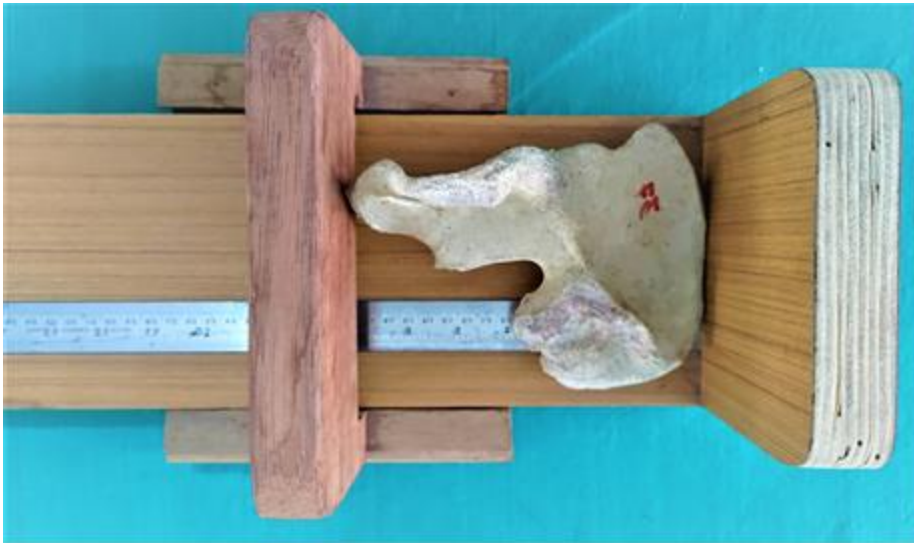**Length of pubic bone :** Length from the superior most aspect of the public symphysis to the nearest rim of the acetabulum, is measured by using sliding vernier caliper.

**Length of ischial bone :** The vertical distance from the anterior aspect of the ischial tuberosity to the nearest rim of the acetabulum, is measured by using sliding vernier caliper.

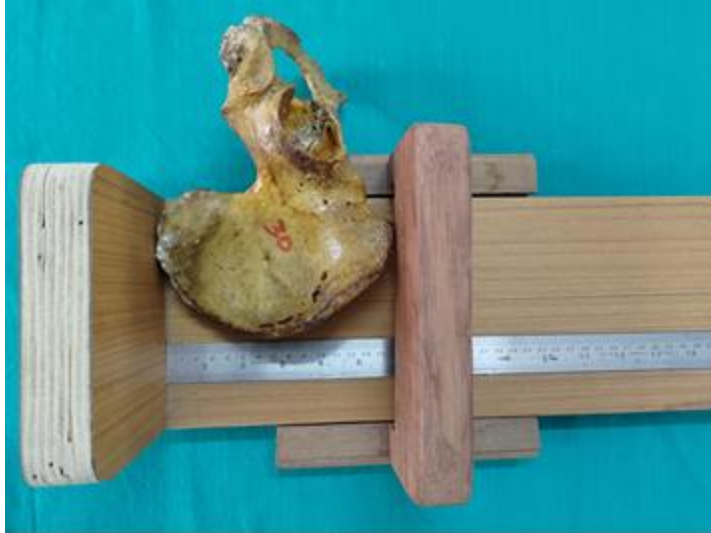**Width of greater sciatic notch:** (4)

It measured using the maximum distance between the pyriformis tubercle and tip of ischial spine.

the pyriformis tubercle is located at the posterior border of greater sciatic notch by joining the pyriformis tubercle and tip of ischial spine the width of greater sciatic notch can be obtained.



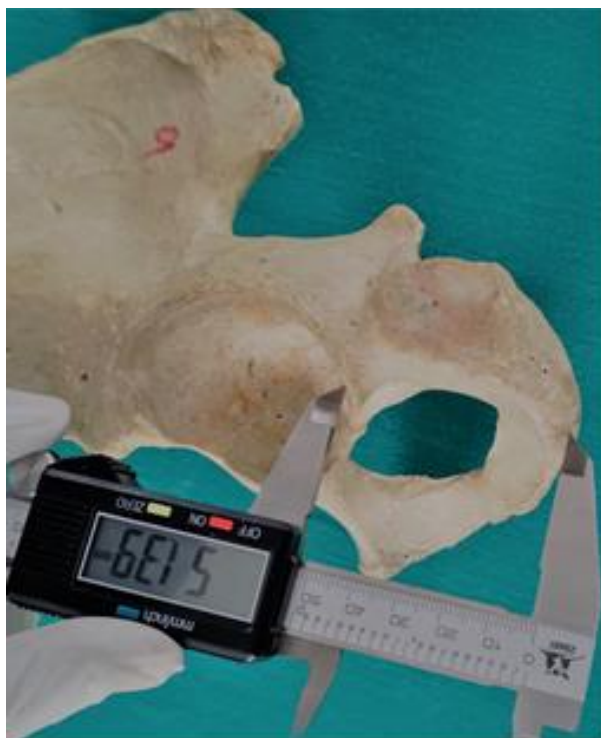**Figure.No.1 – Measuring the length of the hip bone**



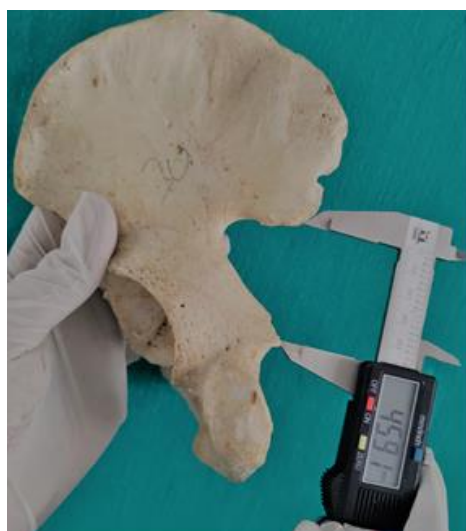
**Figure.No.2 – Measuring the width of the Hip bone**



**Figure.No.3 Measuring the length of Pubis**



**Figure.No.4 Measuring the length of ischium**



**Figure.No.5: Showing the width of the Greater sciatic Notch**

## STATISTICAL ANALYSIS

The results were expressed as Mean $\pm$  SD, and statistical analysis was performed using Student “t”test

## RESULTS

The average value of Coxal index of hip bone of male was  $69.65 \pm 5.1$  and in female  $71.8 \pm 4.7$  the sex differences in the mean value of Coxal index of hip bone of female is more than male and it is significant. The mean value of Ischio pubic index in male was 102.9 cm and in female was 125.4 cm. The width of the greater sciatic notch in male was

40.24 in female was 49.16. In all these parameters there is significantly increased numerical value in female than male hip bones. Among these parameters the width of greater sciatic notch is consider as a most reliable factor in identification of sexual dimorphism.

**TABLE NO:1-MEASURMENT OF COXAL INDEX**

GROUPS	Width of hip bone(cm)		Length of hip bone(cm)		Coxal index	
	Male	Female	Male	Female	Male	Female
Mean	13.73	13.91	19.54	19.6	69.15	71.81
Range	12.2-15.2	11.9-15.1	18.1-21.3	16.4-20.2	61.72-81.96	65.87-78.64
SD	0.71	0.74	0.85	0.90	5.109	4.789

**TABLE.NO.2 MEASURMENT OF ISCHIO PUBIC INDEX**

GROUPS	Length of pubis(mm)		Length of ischium(mm)		Ischio pubic index	
	Male	Female	Male	Female	Male	Female
Mean	50.045	57.49	45.82	46.086	102.957	125.43
Range	41.2-59.71	46.3-65.68	43.21-55.7	38.42-53.24	74.45-124.786	87.309-146.433
SD	5.721	4.45	3.141	4.543	13.357	12.326

**TABLE.NO.3- INTERPERATATION OF GREATER SCIATIC NOTCH**

GROUPS	Male	Female
Mean	40.24	49.163
Range	31.05-48.7	41.57-55.92
Standard deviation	4.635	4.385

### DISCUSSION:

The morphology of hip bone has unique feature as identifiactaion of sexual dimorphism which makes intrest in anatomical, forensic and anthropological point of view. In the present study various distinct features of morphological parameters are studied they are Coxal index, Ischio pubic index and width of greater sciatic notch.The general

identification of sexing in hip bones is weight which was consider to be heavier in male than compared to female, the pelvis is wider, shallow and larger in female than that of male these changes are seen during pubertal age due to effects of sexual hormones.

Davivongs et al ,(19) analysed 50 male and 50 female hip bones and discovered that the mean Coxal index in men is 74.77 and 78.04 in females he concluded the mean Coxal index is higher in female hip bones. Krishna R (21) observed in his study that the mean Coxal index was higher in female hip bone than in male hip bones. Derry et al (13), mean Coxal index in men is 67.7 and 70.08 in female. In our study, the mean value of Coxal index in male hip bone is 69.15 mm and 71.81 in female this shows Coxal index is higher in female than male and very well corelate with the above studies.

Washburn (7) analysed 100 hip bones, using the Ischio pubic index as a marker for the sexing of hipbone which was considerably higher in female than compared to male.

Simiarly Davivongs et al (19) also reoprtd the mean Ischio pubic index was greater in female hip bone, Rajangametal et al (4) concluded the mean Ischio pubic index in male was 121.05 and 138.41 in females. In the present study the mean Ischio pubic index in male was 102.95 and in female 125.43 in which the difference in male to female was 22.48 which is statically significant this shows there is positive correlation of forementioned authors, the sex determination of fragment of hip bone can be done using Ischio pubic index as a valuable parameter.

According to Davionsg et al (19) the greater sciatic notch was higher in females than compared to male disarticulated hip bones. Similarly, Patriquin et al (14) analyed the width of greater sciatic notch he observed the sciatic notch was wider in female hip bones than male. In the present study the mean value of greater sciatic notch was 49.16 cm in females and in males 40.24 cm respectively. The width of greater sciatic notch is significantly higher in females than males.

**TABLE.NO.4- SHOWING COXAL INDEX (cm)**

Reference	Male	Female
Derry (13)1923 et all.,	67.7	70.08
Davivongs (19)1963 et all	74.77	78.04
<b>Present study</b>	<b>69.15</b>	<b>71.81</b>

This indicates the Coxal index is considerably greater in females which is statistically significant p value <(0.001)

**TABLE.NO.5- ISCHIOCHO PUBIC INDEX (mm)**

Reference	Male	Female
Palet et al	100	89
Nirmale et al	116.87	128.14
Kushale et al	86.58	108.55
Rajangametal et al	121.05	138.41

<b>Present study</b>	<b>102.9</b>	<b>125.4</b>
----------------------	--------------	--------------

**TABLE.NO.6 SHOWING WIDTH OF GREATER SCIATIC NOTCH (mm)**

<b>Reference</b>	<b>Male</b>	<b>Female</b>
Davivongs et al	45.23	50.86
Rajangam et al	41.4	44.1
<b>present study</b>	<b>40.24</b>	<b>49.16</b>

Showing the width of greater sciatic notch and Ischio pubic index which is larger in females than males with p value (< 0.001)

### CONCLUSION:

The present study has provided a detailed study of the three statistically significant parameters such as Coxal index, Ischio pubic index and width of greater sciatic notch, which might serve in sex determination even when fragmentary remains of hip bone are available to comment upon the sex of the dead & decomposed skeletons remains. This will give a better guidelines for the forensic, archeological analysis and in solving medicolegal cases.

### CONFLICT OF INTEREST: NIL

### REFERENCES

1. Singh S. and Potturi B.R. – “Greater sciatic notch in sex determination.” J. Anat, (1978), 125, 3:619-624.
2. Rajashree Sheelawant Raut1 Role of Greater Sciatic Notch in Sexing Human Hip Bones Issue 3, 2013 pp 119-123
3. Dr. Rajendra Gupta, Dr. Anil Sastya Sex determination using Ischiopubic index in Gwalior region of Madhya Pradesh, India (anthropometric analysis) 2017; 3(7): 333-335
4. Rajangam S, Janakiram S, Thomas IM. Sexing of hip bones of Karnataka origin. J Anatsoc India 1991;40(2):105-08.
5. Pal GP, Bose S, Choudhary S. Reliability of Criteria used for Sexing of Hip Bones. J. Anat. Soc. India. 2004; 53(2):58-60.
6. Sudarshan Gupta KiranArora .study of significance of Total pelvic height and pelvic width in sex determination of Human Innominate Bone in Gujarat region . GCSMC J Med Sci ;2(2) July-December 2013: 38-41
7. Washburn SL. Sex differences in the pubic bone of Bantu and Bushman. Am J Phys Anthropol 1949; (7): 425-432.
8. Nirmale VK, Laeeque M, Diwan CV. Assesment of reliability of various criteria used in adult hip bone sex differentiation. Int J Anat Res. 2016; 4(4):3185-89.Singh G, Singh S, Singh SP. Identification of sex from tibia. J Anat Soc India 1975; 24: 20-24.
9. Raju PB, Singh S. Sexual dimorphism in scapula. J Indian Acad Forensic sci 1978; 17 (2): 23-33.
10. Khushale KD, Identification of Bhosal YJ, Shyamkishore K. the sex of the individual from Demarking Points of hip bone. Indian Journal of Clinical Anatomy and Physiology, October-December 2016; 3(4):518-525.
11. Dixit SG, Kakar S, Agarwal S, Choudhry R. Sexing of human hip bones of Indian origin by discriminant function analysis. J Forensic Leg Med 2007;14(7):429-35.Singh S, Raju PB. Identification of sex from the hip bone demarking points. J AnatSoc India 1977;26(2):111-17.
12. M.L. Patriquin, S.R. Loth and M. Steyn, Metric assessment of race from the pelvis in South Africans, Forensic Sci Int, 147, 2005, 104-13.
13. Derry DE. On the sexual and racial characters of the human ilium. J Anat 1923;58:71-83.
14. Paleta R., Albanese J. A metric method for sex determination using the hipbone and the femur. J forensic science 2003;48(2):26373.
15. Issac B. Biometry of the posterior border of the human hip bone: normal values and their use in sex determination. J Anat Soc India2002; 51: 43-46

16. Steyn M and İşcan MY. Metric sex determination from the pelvis in modern Greeks. *Forensic Sci Int* 2008;179(1):86.e1-6.
17. Pal GP, Bose S, Choudhary S. Reliability of criteria used for sexing of hip bones. *J Anat Soc India* 2004; 53: 58-60.
18. Standring's. *Gray's Anatomy*. 40thEd, Edinburgh. Elsevier Churchill Livingstone Publishers; 2008.p, 1379-1380.
19. Davivongs V. – "Pelvic girdle of the Australian Aborigine; sex differences and sex determination." *Am. J. Phys. Anthrop.*, (1963) 21(4):443-455.
20. Rajangam S., Jankiram S. and Thomas I. M. – "Sexing of hip bones of Karnataka origin." *J. Anat Soc. India*, (1991), 40(2):105-108.
21. Krishna S, Gursharan Singh Dhindsa et al. Morphometry of The Adult Human Dry Hip Bone, *Int J Pharm Pharm Sci*. 2013; 5(2):505-507.