

A Case Report Of A Very Rare Mixed Ovarian Tumour

Dr. GEETHANJALI.M¹, Dr. KALAMANI.SM², Dr. JAYANTHI.R.³

¹FINAL YEAR PG , DEPARTMENT OF OBG IN MEENAKSHI MEDICAL COLLEGE AND RESEARCH INSTITUTE.

²CHIEF AND PROFESSOR, DEPARTMENT OF OBG IN MEENAKSHI MEDICAL COLLEGE AND RESEARCH INSTITUTE.

³HOD AND CHIEF, DEPARTMENT OF OBG IN MEENAKSHI MEDICAL COLLEGE AND RESEARCH INSTITUTE.

DOI: 10.47750/pnr.2022.13.501.257

Abstract

A 30yr old female unmarried came to OPD with the complaints of lower abdominal pain for past 1 week. on systemic examination P/A : Soft, A cystic mass of size 5*4cm felt in left illiac fossa, mobile , mild tenderness present .L/E : Hymen intact P/R : Rectal mucosa free and same mass felt .Tumour markers are Ca125 12.73, AFP 2.27 and LDH 169.On CT abdomen and pelvis(plain) Uterus and right ovary normal. There is a evidence of well-defined ellipsoid multilocated cystic lesion measuring 7.95 (AP)* 11.5(TR)*9.3(CC) cm seen arising from left ovary occupying right adnexa and anterior placed to uterus . Impression : Left ovarian mass. Macro findings complex ovarian cystic tumour. Pathological discussion Multiple sections studied from from the solid and cystic areas of ovarian tumour shows tubular glands Impression: Suggestive of clear cells + mucinous cyst adenofibroma of borderline tumour – mixed cell type .

KEYWORDS: borderline mixed cell tumour , surgery, follow up

INTRODUCTION:

Ovarian cancer accounts for 30% of malignancies of the female genital tract. Ovarian tumor is not a single entity ,but a complex wide spectrum of neoplasms involving a variety of histological tissues ranging from epithelial tissues, connective tissues , specialised hormone secreting cells to germinal and embryonal cells. Taylor Borderline ovarian tumours or ovarian epithelial tumours were first described by Taylor in 1929. The most common are the epithelial tumours forming 80% of all tumours. 80% are benign and 20% are malignant. Ovarian malignancies are classified into epithelial, germ cell and sex cord stromal tumours. Risk factors are nulliparity, infertility, family history of breast or ovarian cancer and diet rich in animal fat. Epithelial tumors with cellular features of malignancy but without stromal invasion are classified as borderline tumours. They are managed by laprotomy and unilateral oophorectomy . Adjuvant therapy does not improve survival. Malignant epithelial tumours are asymptomatic in majority of women. They may present with weight loss, abdominal distention, loss of appetite and dyspnea. Diagnosis is by ultrasonography, Doppler flow studies and CA 125. Further evaluation with CT/MRI may be required for detection of nodal and distended metastasis.

CASE PRESENTATION:

A 30yr old female unmarried came to opd with the complaints of lower abdominal pain, pricking type of pain, on and off for past 1 week and which is increased in intensity and continuous for 1day. No h/o vomiting/ nausea. No h/o

burning micturition. No h/o white discharge p/v. No h/o fever, cough and cold. No h/o diarrhoea and constipation. menstrual history: regular cycles, 3-4/ 28 days, changes 4-5 pads /day , No h/o clots and dysmenorrhea. past medical history: not an known case of diabetes mellitus, hypertension, thyroid disorder, tuberculosis, bronchial asthma and epilepsy. No h/o food / drug allergy. No h/o blood transfusion. past surgical history: nil significant family history: nil significant personal history: mixed diet. normal sleep and appetite. normal bowel and bladder habits.

On examination patient thin build and moderately nourished ht: 156cm wt: 50.1kg bmi 20.5 no pallor, icterus, cyanosis, clubbing, lymphadenopathy and pedal edema .vitals bp: 110/70 mmhg pr: 70 bpm temp: 98.5f

b/l breast normal thyroid normal systemic examination: cvs: s1s2 rs : nvbs p/a : soft, a cystic mass of size 5*4cm felt in left illiac fossa, mobile , mild tenderness present . l/e : hymen intact p/r : rectal mucosa free. same mass felt.

INVESTIGATIONS • hb 11.9 • rbc count 3.90 • pcv 36 • mcv 93 • mch 31 • mchc 33 • n 44.7 • l 40.7 • e 6.5 • m 7.7 • b 0.4 • platelet count 3.6 • urine routine normal • total t3 106 • total t4 10.1 • tsh 2.36 • hiv negative • hbsag negative

TUMOUR MARKERS • Ca125 12.73 • AFP 2.27 • LDH 16

CT abdomen and pelvis(plain) liver: normal size, morphology and attenuation.margins are smooth. no focal lesions or calcification is seen in the hepatic parenchyma. no dilatation noted in the intrahepatic biliary radicals and the common ducts. portohepatis normal. portal vein, hepatic veins and ivc shows normal diameter gall bladder :normal wall thickness. smooth margins. lumen uniform fluid density no mass lesion ,calcification or stone is seen within the lumen. the fat around gall bladder normal. Cystic duct appear normal pancreas: normal in size, morphology and attenuation. pancreatic duct is not dilated. no peripancreatic fluid or fat stranding. spleen: normal size ,morphology and attenuation .no focal lesions seen. kidneys: both kidneys reveal normal size, shape ,position and attenuation. no mass lesion, calcification or stone is seen in the renal parenchyma or collecting systems on both sides. no signs of obstructive uropathy are detected. gut and peritoneal cavity: stomach is distended and is normal. the gastroesophageal junction appears normal. rectum and large bowel loops are well distended with fecal matter. no free fluid in peritoneal cavity. few subcentimeter mesentric lymph nodes are seen . urinary bladder is normal in wall thickness and lumen pelvis : the urinary bladder is normal in wall thickness and lumen uterus and right ovary normal. there is a evidence of well defined ellipsoid multilocated cystic lesion measuring 7.95 (ap)* 11.5(tr)*9.3(cc) cm seen arising from left ovary occupying right adenexa and anterior placed to uterus . there is a mild mass effect on adjacent bowel and bladder. there is no evidence of attenuationcomponents. lesion showing subtle diffusehemorrhagic areas. impression : left ovarian mass

Procedure done :left ovariectomy

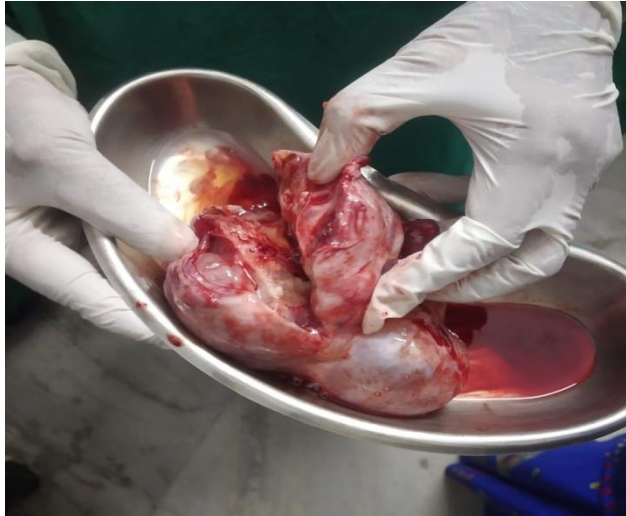

Fig A) COMPLEX OVARIAN CYSTIC TUMOUR

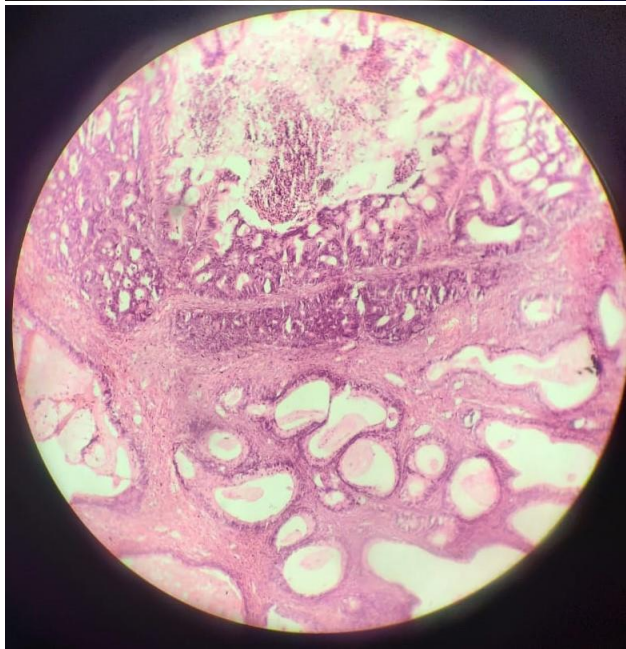


Fig b) OVARAIN MUCNOUS TUMOR

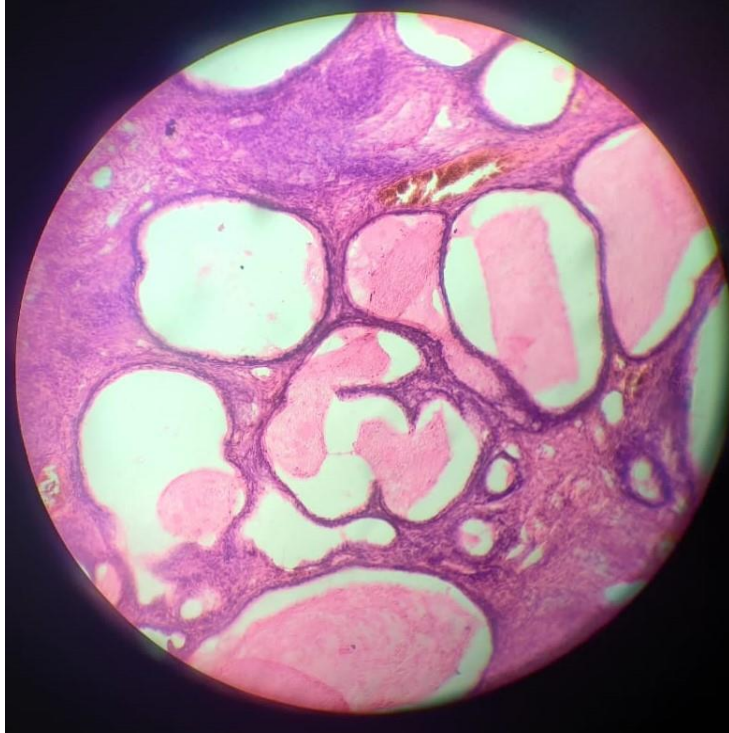


FIG B) OVARIAN CLEAR CELL ADENOFIBROMA

MACRO FINDINGS :complex ovarian cystic tumour 14* 12cm surface smooth glistening with congested vessels with attached fimbrial end , 2 to 3 loculated cyst.

PATHOLOGICAL DISCUSSION • Multiple sections studied from from the solid and cystic areas of ovarian tumourshows tubular glands, small and large cystically dilated glands with intracystic simple papillary and micro papillary patterns. The lining epithelium predominantly show simple mucinous columnar cells. In places show hobnail cells , clear cells, flattened cuboidal cells with focal atypia and stratification fibroplastic stroma and clear cells and nodules . In places show numerous close small glandular cysts with lining epithelial atypia and stratification. The capsule is thin and fibrous with congested vessels • Impression: Suggestive of clear cells + mucinous cyst adenofibroma of borderline tumour – mixed cell type.

DISCUSSION: • Borderline ovarian tumour occurs in young age group and mostly asymptomatic • It has low malignant potential . • Prevalance is 2.5/10,000 per year. • Characteristics of borderline tumours are 1)Patients have high survival rate. 2)Tumours run a typical indolent course. 3) Spontaneous regression of periteneal implants is known to occur. 4) Diagnosis must be based exclusively on the examination of ovarain tumour . 5) Multiple sections must be examined to exclude invasion.

CONCLUSION:

This patient presented as a special case with acute onset of symptoms in young age which is a characteristic for borderline tumours of ovary .In our patient conservative surgery was chosen because of macroscopic and microscopic aspect of tumour.. As they occur in younger women are present at an early stage & have a favourable prognosis but symptomatic recurrence and death may be found as long as 20 years after therapy in some patients. However it should be emphasised that the most the most important negative prognostic factors for recurrence in just the use of

conservative surgery ,but without any impact on patient survival because most recurrent diseases are borderline type easily curable with an excellent prognosis. Special attention should be paid to remaining ovary and regular follow up should be done. The follow up is done by doing tumour markers like LDH, Ca125& USG abdomen.

REFERENCES:

1. kirmisdóttir I, Garmo H, Wilander E and Holmber Borderlinovarian tumors in Sweden 1960–2005: trends in incidence and age at diagnosis compared to ovarian cancer. *Int J Cancer*. 123:1897–1901. 2008.
2. Taylor H: Malignant and semi-malignant tumors of the ovary. *Surg Gynecol Obstet*. 48:204–230. 1929
3. Zanetta G, Rota S, Chiari S, et al: Behavior of borderline tumors with particular interest to persistence, recurrence, and progression to invasive carcinoma: a prospective study. *J Clin Oncol*. 19:2658–2664. 2001
4. Gottlieb WH, Soriano D, Achiron R, et al: CA 125 measurement and ultrasonography in borderline tumors of the ovary. *Am J Obstet Gynecol*. 183:541–546. 2000
5. Prat J and De Nictolis M: Serous borderline tumors of the ovary: a long-term follow-up study of 137 cases, including 18 with a micropapillary pattern and 20 with microinvasion. *Am J Surg Pathol*. 26:1111–1128. 2002
6. Morice P, Camatte S, Rey A, et al: Prognostic factors for patients with advanced stage serous borderline tumours of the ovary. *Ann Oncol*. 14:592–598. 2003.
7. Serov SF, Scully RE and Solvin LH; World Health Organization. Histological typing of ovarian tumors. *International Histologic Classification of Tumors*. World Health Organization; Geneva: pp. 37–41. 1973
8. Bostwick DG, Tazelaar HD, Ballon SC, Hendrickson MR and Kempson RL: Ovarian epithelial tumors of borderline malignancy. A clinical and pathologic study of 109 cases. *Cancer*. 58:2052–2065. 1986.
9. Trillsch F, Ruetzel JD, Herwig U, et al. Surgical management and perioperative morbidity of patients with primary borderline ovarian tumor (BOT) *J Ovarian Res*. 2013;6:48. doi: 10.1186/1757-2215-6-48.
10. Loizzi V, Selvaggi L, Leone L, Latorre D, Scardigno D, Magazzino F, Cormio G. Borderline epithelial tumors of the ovary: Experience of 55 patients. *Oncol Lett*. 2015 Feb;9(2):912-914. doi: 10.3892/ol.2014.2758. Epub 2014 Dec 2. PMID: 25621067; PMCID: PMC4301501.