

Ameloblastoma Or Dentigerous Cyst- A Diagnostic Quandary

Shalini Dixit¹, Binita Srivastava², Nidhi gupta^{3*}, Natasha Gambhir, Rashisingh

¹FMS International Dental Clinic, Hyderabad, ²Private Practitioner

³Department of Pediatric & Preventive Dentistry, Santosh Dental College & Hospital, Santosh Deemed to be university, Ghaziabad

^{4,5} Department of Pediatric & Preventive Dentistry, Santosh Dental College & Hospital, Santosh Deemed to be university, Ghaziabad.

Corresponding author: Dr Nidhi Gupta

DOI: 10.47750/pnr.2022.13.S04.233

Abstract

Orofacial swellings are a major concern these days as they are first interrogated by a pediatric dentist in younger age group. The range of swelling varies from orofacial infections to tumors. Ameloblastoma is rare to be seen in younger age group but still plays an important role in pediatric dentistry. Ameloblastoma is benign and odontogenic and nature most importantly they are recurrent in nature. Unicystic ameloblastoma is majorly confused with keratocyst, due to which it becomes a quandary in diagnosis. It mostly effects mandible and female predilection is higher. In this case report, we present a unicystic ameloblastoma with mural proliferation in 8 years old child.

Keywords: Ameloblastoma, recurrent, Quandary.

INTRODUCTION

Orofacial swellings are the major health care problems in young adults. Generally, it is very easy to focus strictly on the chief complaint and remain oblivious to other oral findings. We as pediatric dentist holds the responsibility to care and maintain the dento – cranial system of a growing child. Common intra-oral swellings are generally diagnosed in pediatric patients are Odontomes, dentigerous cyst, eruption cyst odontogenic keratocyst, ameloblastoma and cysts or swellings of non-odontogenic origin. According to the studies ameloblastomas are commonly benign and odontogenic in nature. It has a very high tendency of recurrence rate.^{1,2} In this report, we describe 8 years old girl who was diagnosed with unicystic ameloblastoma with mural proliferation.

GENERAL CHARACTERISTICS OF UNICYSTIC AMELOBLASTOMA

ETIOLOGY

Unicystic ameloblastoma seems to appear mostly from remaining primitive dental lamina which is present in not fully erupted, gingiva, alveolar bone, and teeth apices. Term ameloblastoma in 1934 was first used by Churchill.³Falkson in 1879 gave a descriptive variant and divided into four variants-

1. Classic solid/multicystic ameloblastoma
2. Unicystic ameloblastoma
3. Peripheral ameloblastoma
4. Desmoplastic ameloblastoma including the so-called hybrid lesion

INCIDENCE AND PREDILECTION

Robinson defined the tumor as 'non-functional, unicentric, anatomically benign, intermittent in growth, and clinically persistent'. Unicystic ameloblastoma shows 5-15% prevalence and mostly occurring in a younger generation.^{3,4} Common predilection site for AMELOBLASTOMA is mandible⁵. Huge population of Asian patients which are affected with ameloblastoma are under the age of 20 years. ^{6,7,8}

HISTOLOGY

The histology of cystic ameloblastomas are actually illusive. Major characteristic features of ameloblastoma as intercellular edema and basal palisade. Histologically it is classified into plexiform type, follicular type, acanthomatous, granular, desmoplastic, basal cell type, unicystic, plexiform unicystic. The plexiform variant constitutes of basal cells arranged inconspicuous stellate reticulum with anastomosing strands in a peculiar fashion. The stroma is usually delicate with cyst like degenerating appearance. ^{9,10,11} UA variant on gross examination, has similar characteristic cyst but not histologically. Histopathologically they are divided as the luminal and the mural variant.

CASE REPORT

Since two to three months, an eight-year-old girl has been complaining of swelling in her left lower back region. The past medical history was insignificant, and patient was in good general health. On recording past dental history, we encountered that the swelling began 2-3 months earlier as an asymptomatic enlargement at left lower jaw but disappeared and this is the second episode of swelling. Swelling increase gradually and attained this size.

EXTRAORAL EXAMINATION

On extraoral examination swelling was 5cm in diameter. It was diffused on the left lower border of the mandible. There was no complain of pain, difficulty during mouth opening, chewing, and even not at the time of articulation. The skin above the swelling appeared smooth and typical in color upon examination. On palpation swelling was bony hard in consistency. The lymph nodes in the neck (cervical) were not palpable. The patient was calm, conscious, and cooperative during examination.



Figure 1: Patient Profile Pictures

INTRAORAL EXAMINATION

On Intraoral examination dentition present was 16 55 54 53 12 11 21 22 63 64 65 26 46 85 83 42 41 31 32 73 74 75. Swelling observed on left lower cortical plates and an ulcerative opening was seen distal to 74. Buccal and lingual cortical plate were expanded, extended from distal boundary of 74 to anterior border of ramus.

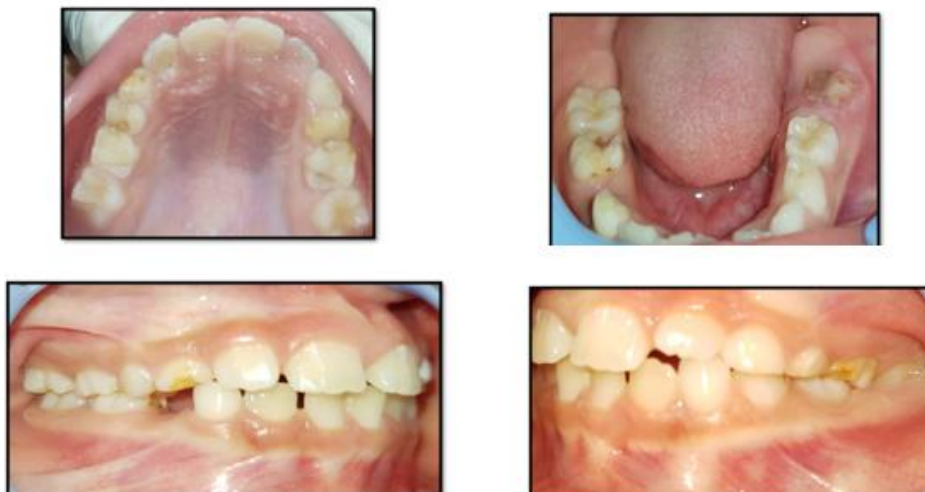

Figure2: Intra-oral images

INVESTIGATION

- OPG
- BIOPSY

DIFFERENTIAL DIAGNOSIS

- Dentigerous cyst
- Ameloblastoma

PROVISIONAL DIAGNOSIS

The OPG revealed large multilocular radiolucency on left side of mandible. The cystic lesion was noticed from distal surface of 74 extending up to anterior border of ramus. The cavity walls margins were well defined, multilocular, which suggests provisional diagnosis as Dentigerous cyst.

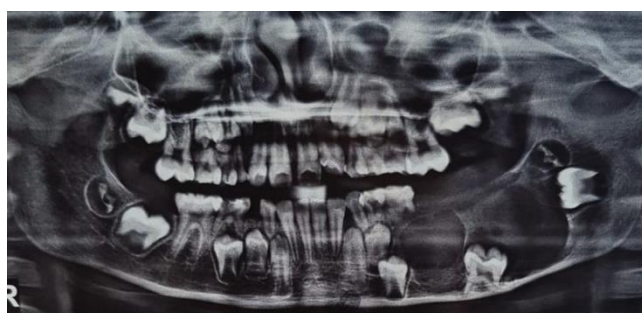

Figure3: OPG reveals provisional diagnosis of Dentigerous cyst

HISTOPATHOLOGICAL REPORTS

Histopathological report revealed that the given H&E stained, section presented anastomosing cords and sheets of odontogenic epithelium bound by columnar epithelium cells. The surrounding stroma is loosely arranged and also surrounded with a cystic lining that consist of ameloblast like cells with overlying stellate reticulum. The histological features are suggestive of [unicystic ameloblastoma with mural proliferation of plexiform ameloblastoma](#).

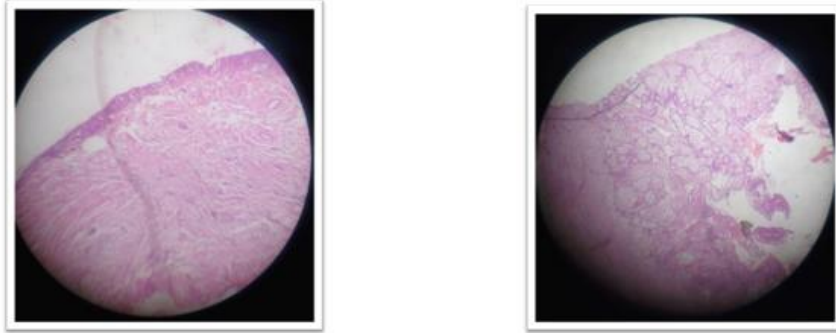


Figure4: Histological features suggested as Unicystic ameloblastoma

TREATMENT

Treatment planning was done, and patient was subjected for surgery under LA. During the procedure thinning of buccal plate was observed, carefully marsupialization was done with preservation of Inferior alveolar nerve and cortical plates (as it helps in healing and remodelling). During marsupialization bud of 37 was removed with the pathological mass as it was involved with the cystic lining. The sutures were given and IODOFORM gauge was packed inside the cystic cavity. Patient was recalled weekly for iodoform gauge dressing and follow ups.

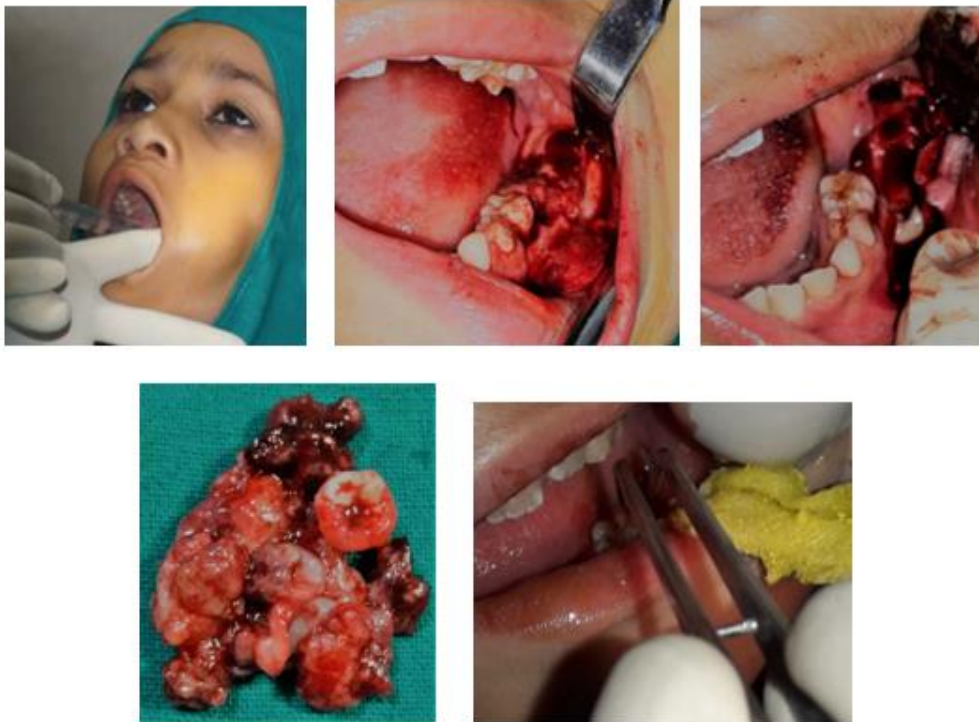

Figure5: Inter-operative photographs

HISTOLOGICAL FINDINGS

The pathological mass was sent for histopathological findings. The H&E stain revealed the section presented anastomosing cords and sheets of odontogenic epithelium bound by columnar epithelium cells. The surrounding stroma was loosely arranged and also surrounded with a cystic lining that consist of ameloblast like cells with overlying stellate reticulum. The histological features were suggestive of Unicystic ameloblastoma with mural proliferation of plexiform ameloblastoma. Hence the final diagnosis achieved was Unicystic ameloblastoma with mural proliferation of plexiform ameloblastoma.

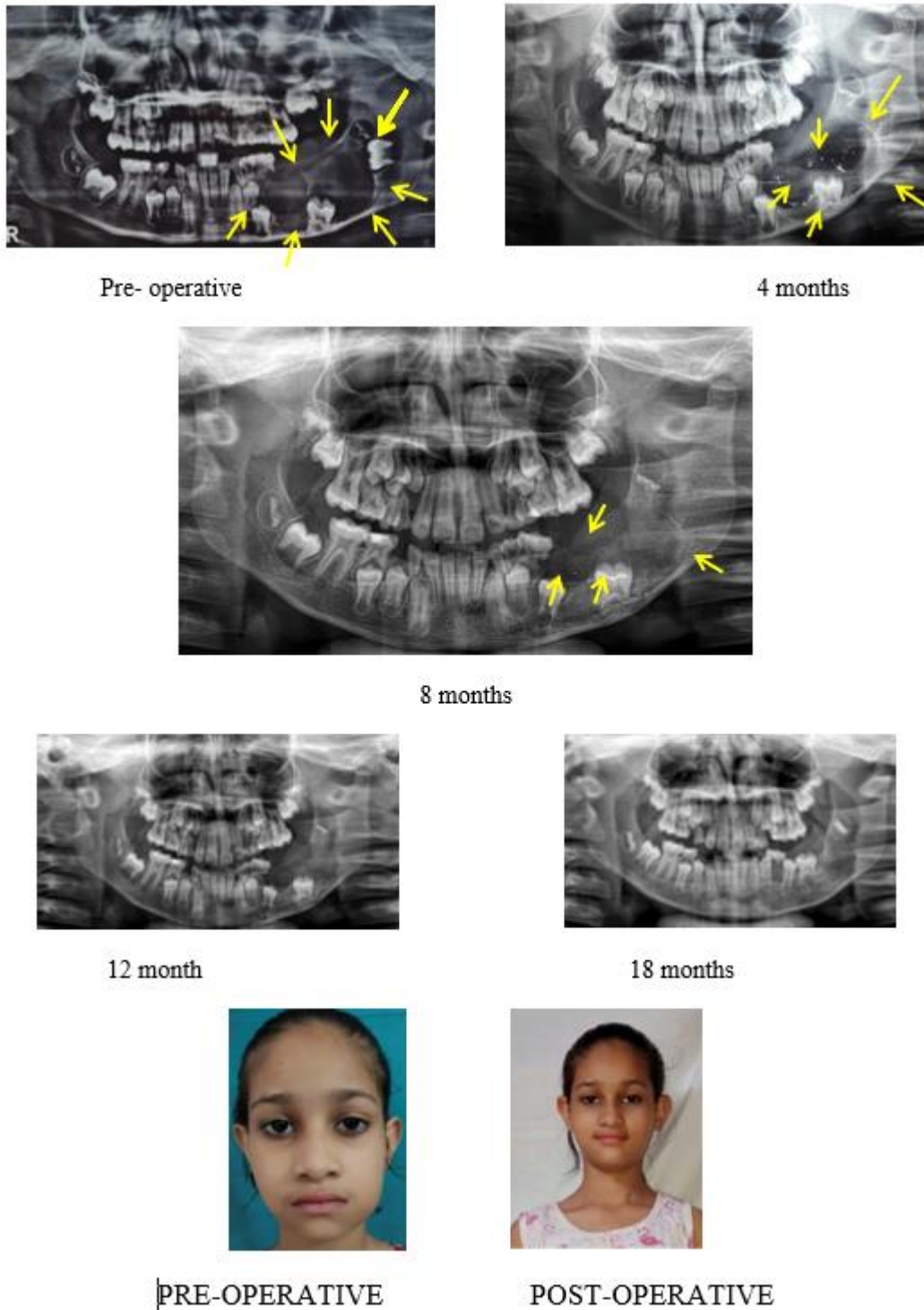


Figure6: Post-operative follow-up radiographs and photograph

DISCUSSION

Ameloblastoma is a benign odontogenic tumor which arises from epithelial cellular element and dental tissue(ameloblast) at different stages of advancement. Solid or multicystic ameloblastoma accounts for more than 80% of all ameloblastoma, while unicystiameloblastomas accounting for the remaining twenty percent of instances, as well as peripheral ameloblastomas. It is divided into 3 types:Unicystic, Multicystic,Peripheral.

Ameloblastomas in peripheral subtypes accounts for two percent. And unicystic accounts for six percent of all occurrences in children and adults. The plexiform unicystic variant was first described by Robinson and Martinez in the year 1977. In children it is considered as an uncommon entity. Ameloblastoma accounts around 10-15% of all cases reported. It affects all age groups and accounts for 13-56% of all jaw tumors with high incidence in third and fourth decade of life. Both clinically and radiographically, this tumor has a lot in common with dentigerous cyst.

Traditional solid or multicystic ameloblastoma has been shown to have less destructive biological traits and a reduced recurrence tendency. In pediatric patients, the tumor is regarded unusual. Its frequently linked to the existence of impacted molar because the lesion grows slowly, the periosteum has time to build a thin bone shell ahead of the developing lesion, which causes the bony cortices to enlarge. Crepitus, sometimes known as “eggshell crackling”, is a key diagnostic characteristic.

Because radiation and chemotherapy are unsuccessful in these circumstances, there have been reports of developing sarcomas due to radiation. The most common therapy for this tumor is surgery.¹² Because of its invasive nature, it is frequently advised to remove the margins surgically and make it free from disease. Treatment often necessitates the removal of significant sections of the jaw, followed by reconstruction. Despite the facts that these tumors are rarely malignant or metastatic and grow slowly, the lesion that arises can cause serious facial and jaw deformities. Partial maxillectomies and segmental excision of the mandible is majorly included in treatment plan.

Recurrence rate for resection were 3.6 percent, 30.5 percent for enucleation alone with 16 percent for enucleation followed by Carnoy solution, and eighteen percent for marsupialization with or without further therapy in a second phase in another trial.¹³

CONCLUSION

These kinds of lesions are usually identified as a dentigerous cyst as its characteristics are very similar both clinically and radiologically. However, in this case also preoperative provisional diagnosis was dentigerous cyst. The histological diagnosis was completed later, and finally concluded it as unicystic ameloblastoma with mural proliferation of plexiform ameloblastoma.

BIBLIOGRAPHY

1. Olaitan AA, Adekeye EO. Clinical features and management of ameloblastoma of the mandible in children and adolescents. *Br J Oral Maxillofac Surg.* 1996; 34:248-51.
2. Raptis AD, Andrassakis DD, Stavrianos SD, Faratzis G, Arno-2, Giannakiliappi N, Lagogiannis GA. Ameloblastomas of the jaws; clinicopathological review of 11 patients. *Eur J Surg Oncol.* 2004; 30:998-1002.
3. Kessler HP, Schwartz-Dabney C, Ellis E 3rd. Recurrent left mandibular enlargement. *J Contemp Dent Pract.* 2003;4:127-37.
4. Ord RA, Blankaert Jr RH, Nikitakis NG, Sauk JJ. Ameloblastoma in children. *J Oral Maxillofac Surg.* 2002;60(7):762-71.
5. Yavagal et al.: Unicystic plexiform ameloblastoma. *J Indian Soc Pedod Prevent dent.* 2009; 27(1):70-4.
6. Gold L, Upton GW, Marx RE. Standardized surgical terminology for the excision of lesions in bone: An argument for accuracy in reporting. *J Oral Maxillofac Surg* 1991;49:1214.
7. Robinson L, Martinez MG. Unicystic ameloblastoma: A prognostically distinct entity. *Cancer* 1977;40:2278.
8. Sirichitara V, Dhiravarangkura P. Intrabony ameloblastoma of the jaws: An analysis of 147 Thai patients. *Int J Oral Surg* 1984; 13:187
9. Deonjag Hertag et al. Histopathology of ameloblastoma of the jaws; some critical observations based on a 40 year single institution experience *Med Oral Patol Oral Cir Bucal.* 2012; 17(1):e76-e82.
10. Reichart PA, Philipsen HP, Sonner S. (March 1995). “Ameloblastoma: biological profile of 3677 cases”. *Eur J Cancer B Oral Oncol.* 1995; 31B(2):86-99.
11. Pogrel MA, Montes DM. Is there a role for enucleation in the management of ameloblastoma? *Int J Oral Maxillofac Surg.* 2009 Aug;38(8):807-12.
12. Jitesh S, Madhulaxmi M. Management of unicystic ameloblastoma - a review. *Int J Sci Dev Res.* 2021; 6(3): 517-20.
13. Lau SL, Samman N. Recurrence related to treatment modalities of unicystic ameloblastoma: a systematic review. *Int J Oral Maxillofac Surg.* 2006 Aug;35(8):681-90.