

# A Novel Technique to Restore a Large Maxillary Defect- A Case Report

Surabhi Duggal<sup>1</sup>, Shailesh Jain<sup>2</sup>, Prashanti Wahengbam<sup>3</sup>, Anu Sharma<sup>4</sup>, Maitreyi Ranjan<sup>5</sup>, Sahba Hassan<sup>6</sup>

<sup>1</sup>Assistant Professor, Department of Prosthodontics and Crown & Bridge, School of Dental Sciences, Sharda University, Greater Noida, Uttar Pradesh, India

<sup>2</sup>Associate Professor, Department of Prosthodontics and Crown & Bridge, School of Dental Sciences, Sharda University, Greater Noida, Uttar Pradesh, India

<sup>3</sup>Private Practitioner (Prosthodontist) at Crown Capital Dental Clinic and Implant Centre, Imphal, India

<sup>4</sup>Lecturer, Department of Prosthodontics and Crown & Bridge, National Dental College, Derabassi, Punjab, India

<sup>5</sup>Assistant Professor, Department of Microbiology, School of Dental Sciences, Sharda University, Greater Noida, Uttar Pradesh, India

<sup>6</sup>Post Graduate Student, Department of Prosthodontics and Crown & Bridge, School of Dental Sciences, Sharda University, Greater Noida, Uttar Pradesh, India

Email: surabhiduggal92@gmail.com

DOI: 10.47750/pnr.2022.13.S06.450

## Abstract

The causes of maxillary defects can be congenital or acquired in nature and management of these defects often require surgical removal of a part or almost the whole of the maxilla. This may result in establishment of oro-antral communication which ultimately hampers the daily routine activities of the patients such as speaking, swallowing, sneezing and coughing. Improvement of the defects with obturator prosthesis has been found to be beneficial to the patients. However, one of the main obstacles in restoring a large defect is the heaviness of the prosthesis which makes it non-retentive. To conquer these difficulties, diverse techniques are used to build up hollow bulb obturators. Here we report a case of large maxillary defect in a 75 year old male with Class I Aramany's defect which was restored by a provisional obturator designed in the shape of a close hollow bulb using a clear and streamlined method for fabrication.

**Keywords:** Maxillary Neoplasm, Maxillofacial Prosthesis, Palatal Obturators.

## INTRODUCTION

Patients with maxillary defects often encounter problems with mastication and speech owing to the occupancy of an oroantral communication. Postsurgical prosthodontic therapy chiefly aims at closing the oro-nasal compartments thereby reducing the nasal regurgitation and hypernasal speech.[1] An obturator prosthesis helps in rehabilitating such situations.[2] "The Glossary of Prosthodontic Terms", (part 9), specifies obturator as "A maxillofacial prosthesis used to close a congenital or acquired tissue opening, primarily of the hard palate or contiguous alveolar or soft tissue structures".[3] Depending upon the phases of rehabilitation, the obturator can be surgical, interim, or definitive. The closed type hollow design of the obturator significantly reduces the overall weight, prevents the entry of oral and nasal secretions, and helps in better retention.[4,5] The degree of extension of an obturator in the defect site confides to the extent of the defect, resiliency of the underlining tissue, and the need for achieving basic functional requirements like support, retention, and stability.[6] This article presents a modified yet simple process for construction of an interim closed hollow bulb obturator constructed using a single base-double counter pour technique intending to restore the subject's native dentition, facial and palatal tissue forms. Custom frozen saline was used for the fabrication of the hollow bulb. A sheet of hard carding wax was put to use for replicating the tissues in the presurgical form in affected maxillary arena.

## CASE REPORT

An individual aged 75 approached the Oral and Maxillofacial Surgery department with a complaint of swelling on left side of face and difficulty in breathing since 6 months (Figure 1a). After thorough clinical examination, followed by radiographic and histopathological investigations, a final diagnosis of squamous cell carcinoma of left maxillary sinus was arrived at. Since the lesion was huge extending superiorly to the floor of the orbit, posteriorly to medial and lateral pterygoid plates, medially it crossed the midline involving the hard palate and laterally till the zygomatic arch. Surgical removal of whole of the malignant lesion along with safety margin was planned. During the surgical removal of malignant tissue, establishment of oro-antral communication was anticipated since the lesion had invaded the palate and hence initially a temporary surgical obturator was inserted immediately after surgery (Figure 1b) and a closed hollow bulb obturator was recommended at a later stage after healing of the tissues.

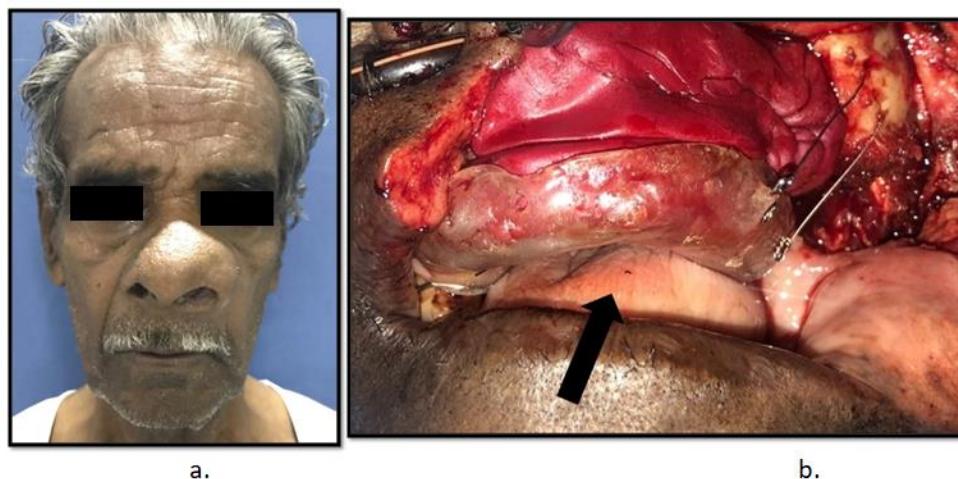


Figure 1a: Clinical picture of patient showing extraoral swelling on face and Figure 1b: Placement of temporary surgical obturator (black arrow)

One and a half months later the patient came to the 'Department of Prosthodontics' for the restoration of maxillofacial defect that was created following surgery. The patient presented with dressing in the maxillofacial defect region which was removed to examine the area of interest thoroughly (Figure 2a). The patient's oral cavity and visceral structures were cleansed with an antiseptic dipped cotton and saline immersed gauze and the nasal and mucosal discharges were removed using gauze. After examining clinically, the defect was categorized as Aramany Class II[6] of the maxillary arch (Figure 2b) The maxillary right first and second molar were the only teeth that were present in maxillary arch while in mandibular arch, all the teeth were present.

### TECHNIQUE

Firstly, an impression of the maxillary defect was taken with a 'thermoplastic material' (impression compound) using a plastic sectional stock tray. With the help of an 'irreversible hydrocolloid' (Zelgan plus, Dentsply India Pvt. Ltd, Gurgaon), the impression of the defect near the area of the orbital rim and nasal floor was obtained, which was built upon by impression compound (Figure 3). The impression was carefully duplicated with the help of putty. Once the putty was set, a custom tray was prepared using self-curing acrylic resin (DPI-RR Cold cure, Dental Products of India, Mumbai). Greenstick tracing compound (DPI Pinnacle Tracing sticks, Dental Products of India) was used for border molding, following which 0.5 mm of the material was tossed out from its surface. Tray adhesive component was then combined onto the surface of acrylic resin and green stick compound. Furthermore, a secondary impression using light body addition silicone substance was taken (Reprosil, Dentsply International, Milford). The definitive impression thus obtained was flowed using Type IV gypsum compound to acquire the master cast.

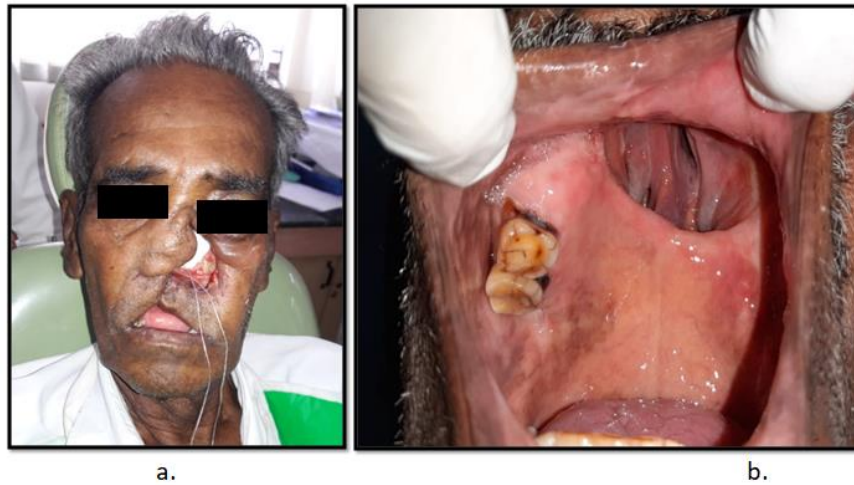

Figure 2a: Presentation of the patient to the department with dressing and Figure 2b: Clinical picture of patient showing maxillofacial defect intraorally

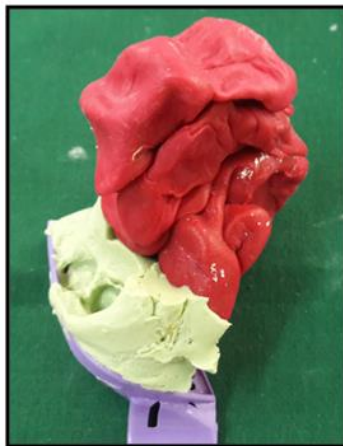


Figure 3: Preliminary impression made using thermostatic and irreversible impression material of intraoral defect site

Later, the master cast was duplicated using reversible hydrocolloid material, agar-agar, (Castogel, BEGO, and Co, Germany) after blocking out the unfavorable undercuts. The occlusal rim was created over a self-polymerized acrylic denture base resin (DPI-RR Cold cure, Dental Products of India) by blocking out the defect region completely in the duplicated master cast using aluminum foil. Jaw relation was obtained and teeth setting was executed in the anterior region for restoring aesthetics. Likewise, a flat occlusal table was added on the posterior level with wax.

#### Fabrication of the Hollow Bulb utilizing the First Counter Pour

For easy removal of the master cast, the non-favorable undercuts around the defective lesion as well as the teeth were blocked out using Type II plaster after the flasking step. The use of putty consistency addition silicone along the walls and within the defect space and over the dentulous portion of the cast ensured a smooth and even finish of the inner portion of the hollow bulb (Figure 4a). This step helped in maintaining a thin space for the heat polymerized resin and also facilitated the easy removal of the counter portion of the flask from the defect space during the flasking and processing stages (Figure 4b). Flasking of the master cast up to the base was completed using Type-II Dental Plaster. Separating medium (Cold mold seal, DPI, Mumbai) was applied and the first counter was poured. Once the plaster was set the counter portion of the flask was separated from the base pour. The putty silicone which was adapted over the defect site was then removed (Figure 4c). Both the divisions of the flask were covered twice with separating medium after which it was spared to dry. Heat-polymerized acrylic resin (Heat cure acrylic, Dental Products of India, India) was placed over the defect area and a procedure of trial closure was accomplished to extract the additional material continuing further the defect margin (Figure 4d). The first counter portion of the flask was

switched over the base of the flask and clamps were secured. Preparation of the bulb portion was done by conditioning it to a short curing cycle (74° C for 2 hours and 100 °C for an additional one hour). Past the processing time the flasks were retrieved from the bath and bench cooled for thirty minutes followed by a quick wash under cool tap water for fifteen minutes. Thereafter, thorough recovery of the counter portion of the flask from the master cast was carried out.

#### Fabrication of Obturator via the Second Counter Pour

The trial base with the artificial teeth was transferred onto the master cast present in the base of the flask and waxed up. Waxed up denture base and the clasps were then sealed onto the master cast that contained the previously cured hollow bulb (Figure 5a). After application of separating medium to the base pour, the second counter pour was carried out and flasking was concluded using Type II dental plaster. The dewaxing procedure was completed by placing the flask in boiling water for 4 minutes after which the counter and base portions of the flask were separated. The bulb portion was suffused with saline and kept for freezing in a refrigerator. The use of chilled saline reduced the freezing point of frozen water making it colder and reduced the rate at which the ice melted. This helped in prolonging the working time for maintaining the hollowness of the obturator (Figure 5b). Separating medium was applied to both parts of the flask and allowed to dry. Heat polymerized acrylic resin was placed on the second counter containing the denture teeth and the base of the flask was placed over it and tightly secured with help of a clamp. Processing of the resin was carried out by following a short curing cycle. After the bench curing the final prosthesis was carefully retrieved from the master cast, finished and polished (Figure 6a). The finished and polished interim obturator was introduced in the patient's oral cavity (Figure 6b). The patient is under regular follow up since one year without any complains till date.

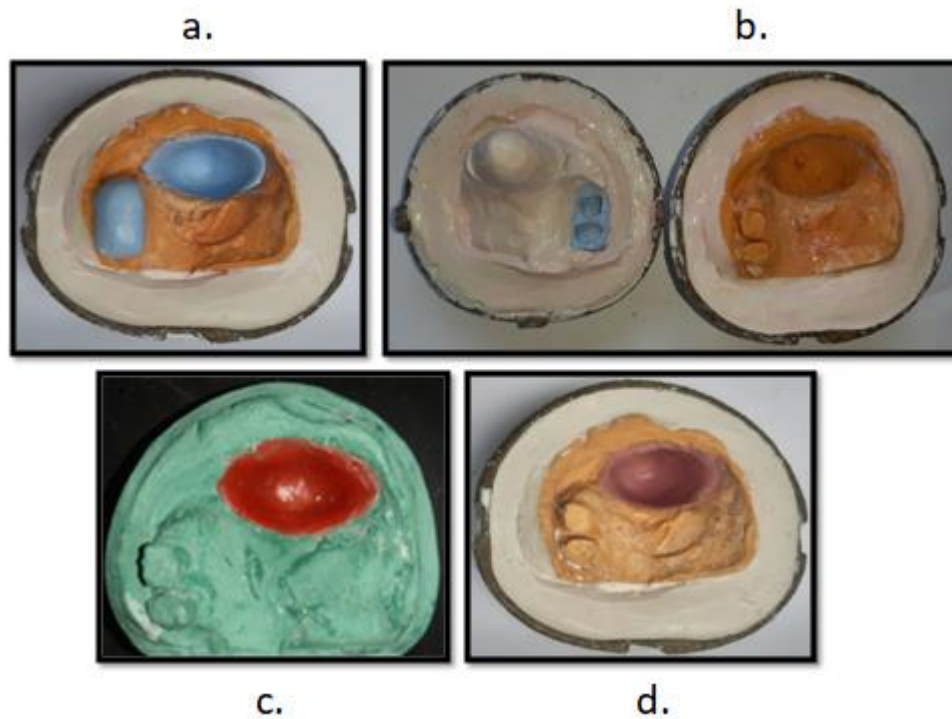


Figure 4a: Defect site and natural teeth blocked out with putty silicone, Figure 4b: Molds after dewaxing, Figure 4c: Defect blocked out with wax, Figure 4d: Heat cure acrylic resin packed into the mold

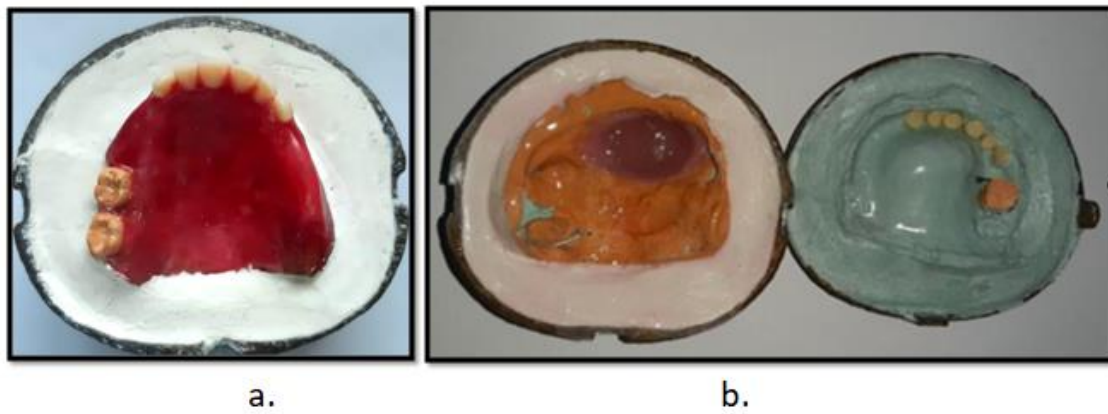


Figure 5a: Waxed up denture ready for processing and Figure 5b: Hollow bulb filled with frozen saline and counter lid containing acrylic teeth and clasps

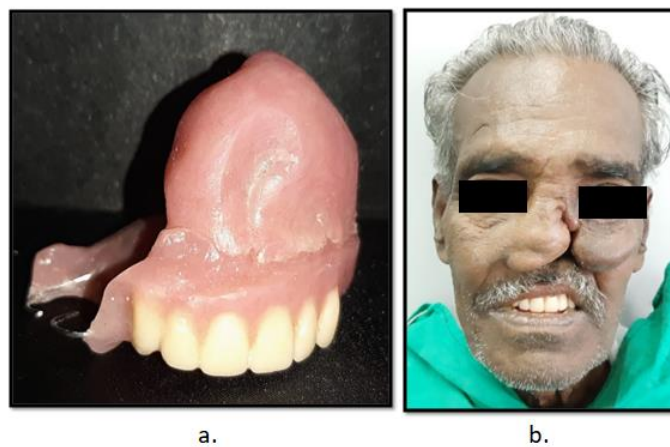


Figure 6a: Final prosthesis and Figure 6b: Clinical picture of patient with prosthesis.

## DISCUSSION

Management of oral malignancy or any imperfection in the orofacial region demands the replacement of entire or a portion of the maxillary arch surgically, abandoning the entity with a deformity that jeopardizes the virtue and activity of the oral cavity. This can be debilitating as it hinders the regular form and function of the stomatognathic setup. Such defects can be congenital or acquired in nature.[1] Patients who have undergone maxillectomy go through an aesthetic as well as a functional deformity. As a representative of the surgical group, the prosthodontist involved, can help in recreation and restoration of the maxillectomy subject by constructing and fixing a surgical obturator. The instantaneous post-operative renovation of form and function minimizes resumption period in the health institution and hastens the patient's entrance to society as an active component. The obturator upholds soft tissues after surgery and diminishes scar contracture and disfigurement by that shaping a beneficial impact on the patient's mental make-up. A factitious substitute of teeth and palate benefits communication, deglutition, aesthetics, as well as self-esteem. In a dentate victim, surgical obturator schemes can transform from a prosthesis with an acrylic resin record base having no teeth, with or without wrought-wire clasps, to a clasped acrylic resin prosthesis that repairs the arch form. It is advised that posterior occlusal contacts need not be set on the amputated side until the surgical wound is patched up. Commonly accepted approach is the ablative surgical treatment for the control of abnormal growths in the oral cavity and other malignancies. The postsurgical effect can be serious as there is a disturbance by the loss of form and function and also the facial contour. An obturator serves the purpose of an obstruction to prevent the discharge from the oral and sinonasal cavities to mix. A maxillary obturator is the best option and the first choice of the dentist and the victim as it is easy to fabricate, light in weight, and requires minimal maintenance.[7] It serves as an easy and best alternative to surgical reconstruction. The extent of the obturator depends on the dimensions of the defect as well as its location. Wu YL et al[8] in their study found that there is a

reduction in the prosthesis weight from 6.55% to 33.06% by using hollow bulb obturators and hence in the present case hollow bulb obturator was fabricated keeping in mind the large size of the defect to be restored. Obturator bulb extensions come in the shape of solid, open hollow, or closed hollow. The closed hollow design obturator is preferred as it stops fluid and food accumulation followed by allowance for a maximum amount of extension, which ultimately makes the design comfortable for the patient.[9] Several materials such as heat cure resin, light cure resin, and sometimes even metal have been used to fabricate obturators.[10] For the hollow in the prosthesis, many authors made use of materials like sugar, ice, and frozen water. For obturator prosthesis with artificial teeth techniques as the modification of a surgical obturator, a denture duplicator, use of a matrix made of celluloid, heat polymerized acrylic resin and light cure resin is beneficial.[10] The obturator prosthesis thus made holds up the soft tissues post surgery, tries and helps to reduce scar contracture, as well as lessens deformity. This contributes to the positive mental being of the patient along with an improved aesthetic appearance. The wire clasps included in the prosthesis provide a bracing effect, giving a satisfied and confident feel to the patient. The inclusion of posterior teeth in the obturator has been disproved by many authors due to their excessive stress on the unhealed region and a delay in wound healing. Missing anterior teeth are built up with the intent of prohibiting serious psychological ache to the individual and cooperates in restricting scar contracture. The facial flange extensions guide and encourage the facial soft tissues to sustain the patient's aboriginal facial aesthetic presentation. Zone developed between the flanges of the facial tissue and hard palate can effortlessly be engaged for employing the surgical pack right away succeeding surgery. In this manner, the obturator administers a steady mode for the surgical pack. The processing of the bulb portion can be done with the oral portion of the prosthesis or can be independently fabricated and joined later on with light or chemically polymerizing acrylic resin.[11,12] In the present case, the portion of bulb was initially built and used as a carrier for the custom frozen saline which was used for maintaining the hollowness and joined with the oral portion using heat polymerized resin. The obturator which was entirely fabricated of heat polymerized acrylic resin minimized staining, reduced effusion, as well as increased the longevity and durability of the prosthesis. Various techniques have been used in the fabrication of obturator in one piece or two pieces.[13] A one-piece obturator benefits in being hygienic and no visible lines of demarcation are seen between the bulb portion and the denture base portion. A number of constituents were put to use to recreate the hollowness. The application of ice in its crushed form to build up a matrix in the bulb was first described by Schneider. It served to maintain the hollowness during the processing procedure.[14] The use of sugar was advocated by Matalon V et al[15] and Parel SM et al[16]. Srinivasan J et al[17] in their research, fabricated the hollow bulb portion using the lost salt technique. A shim of acrylic resin in the defect site was made use of by Chalian while Tanaka et al included polyurethane foam.[18,19] The custom-made frozen saline space built in this methodology allowed uniform space to be maintained in the bulb portion.[14] Charles DP et al[20] in their study used frozen water for creating the hollowness of the bulb. But in tropical weather conditions, it is difficult to maintain the hollowness of the bulb as frozen fresh water melts at a relatively faster rate. The use of frozen saline helped in achieving suitable working time as it reduced the freezing point of ice by making it colder and melt at a lower rate. However, the reduction in the freezing point of ice meant a longer time duration for the freezing process to complete.

## CONCLUSION

To restore the ambiguity of the facial structures and bring back routine functional activities the prosthetic dentist must apply his knowledge and restore the patient with the best of the techniques and materials available. The modified technique using custom frozen saline described in this article can be employed for the production of a light-weight closed hollow bulb obturator prosthesis utilizing heat polymerized acrylic resin especially in patients with larger maxillofacial defects.

## REFERENCES

1. Jalan S, Barmaan J. Rehabilitation of hemimaxillectomy patient with definite hollow characterized obturator prosthesis. *Int J Oral Care Res* 2016;4:216-9.
2. Kornblith AB, Zlotolow IM, Gooen J, Huryn JM, Lerner T, Strong EW, et al. Quality of life of maxillectomy patients using an obturator prosthesis. *Head Neck* 1996;18:323-34.
3. Glossary of Prosthodontic Terms. *J Prosthet Dent* May 2017;117(5S):e62.
4. Brown KE. Clinical considerations improving obturator treatment. *J Prosthet Dent* 1970;24:461-6.
5. Desjardins RP. Obturator prosthesis design for acquired maxillary defects. *J Prosthet Dent* 1978;39:424-35.
6. Aramany MA. Basic principles of obturator design for partially edentulous patients. Part I: Classification. *J Prosthet Dent* 1978;40:554-7.
7. Patil PG, Patil SP. A hollow definitive obturator fabrication technique for management of partial maxillectomy. *J Adv Prosthodont* 2012;4(4):248-53.
8. Wu YL, Schaaf NG. Comparison of weight reduction indifferent designs of solid and hollow obturator prostheses. *J Prosthet Dent* 1989;62(2):214-7.
9. Habib BH, Driscoll CF. Fabrication of a closed hollow obturator. *J Prosthet Dent* 2004;91:383-5.
10. Rani S, Gupta S, Verma M. Hollow bulb one-piece maxillary definitive obturator - A simplified approach. *Contemp Clin Dent* 2017;8:167-70.
11. McAndrew KS, Rothenberger S, Minsley GE. An innovative investment method for the fabrication of a closed hollow obturator prosthesis. *J Prosthet*

Dent 1998;80:129-32.

12. Asher ES, Psillakis JJ, Piro JD, Wright RF. A technique for quick conversion of an obturator into a hollow bulb. *J Prosthet Dent* 2001;85:419-20.
13. Sridevi JR, Kalavathy N, Jayanthi N, Manjula N. Techniques for fabricating hollow obturator: Two case reports. *SRM J Res Dent Sci* 2014;5:143-6.
14. Schneider A. Method of fabricating a hollow obturator. *J Prosthet Dent*. 1978;40(3):351. doi: 10.1016/0022-3913(78)90046-x. PMID: 279681.
15. Matalon V, LaFuente H. A simplified method for making a hollow obturator. *J Prosthet Dent* 1976;36(5):580-2.
16. Parel SM, LaFuente H. Single-visit hollow obturators for edentulous patients. *J Prosthet Dent* 1978;40(4):426-9.
17. Srinivasan J, Babu Rajan K, Smesh V. Fabrication of Interim Hollow Bulb Obturator Using Lost Salt Technique - A Case Report. *Journal of Scientific Dentistry* 2011;1(1):37-8.
18. Chalian VA, Barnett MO. A new technique for constructing a one-piece hollow obturator after partial maxillectomy. *J Prosthet Dent* 1972;28(4):448-53.
19. Tanaka Y, Gold HO, Pruzansky S. A simplified technique for fabricating a lightweight obturator. *J Prosthet Dent* 1977;38:638-42.
20. Charles DP, Rajendran A, Nandini V, Ramanujam C. Technique for the fabrication of interim closed hollow bulb obturator in a patient with Class II Aramany's defect, *Karnataka Prosthodontic Journal* 2017;1(3):6-12.