

Assessment of serum alkaline phosphatase and calcium levels during bone fracture healing in dogs stabilized with a bone plate after being treated with an amniotic membrane loaded with platelet rich plasma

Ali A. Ghadban¹, Bassim K. Khashjoori²

¹Post graduate student, College of Veterinary Medicine, Basrah University, Iraq

²Assistant Professor, Department of Surgery and Obstetric, College of Veterinary Medicine, Basrah University, Iraq

Email: alialsurgery@gmail.com

DOI: 10.47750/pnr.2022.13.S06.427

Abstract

Background/aim: The goal of the present study was to investigate the effects of an acellular amniotic membrane loaded with autologous platelet-rich plasma on bone healing biochemically by measuring serum factors including calcium and alkalinity in a dog model. **Materials and methods:** Fifteen dogs were used in the current study. The animals were divided into three groups of five dogs each. A transverse osteotomy was induced in the midshaft of the left tibia of all animals. The first group was treated with acellular amniotic membrane only by wrapping it around the fracture site. The second group was given acellular amniotic membrane and platelet-rich plasma to treat them, while the third group (the control) was left alone and not treated

Whole blood was drawn from all groups on the 0th day prior to surgery as well as on the 14th, 28th, 42nd, and 56th days following surgery. Physiological data was then reported. In order to estimate calcium and alkaline phosphatase at various phases of fracture healing. Results: the results of the present study illustrated that the serum alkaline phosphate and calcium levels increased ($p \leq 0.01$) on days 14 and 28, followed by a decreasing trend after day 28 to day 56. And their levels were higher in group AM+PRP than in other groups (39.4 ± 1.21 , 15.79 ± 0.66 respectively). When compared to the control and AM groups, the rate of formation of new bone tissue in Group AM+PRP was the fastest. It was concluded that serum alkaline phosphatase and calcium were found to be helpful biochemical indicators for evaluating bone development and contributed to proving the superiority of using the amniotic membrane loaded with platelet-rich plasma in promoting bone healing. These biochemical parameters, in conjunction with clinical and radiographic examinations, provide reliable information about the degree of bone healing.

Keywords: Amniotic membrane, Platelet rich plasma, Alkaline phosphate, Calcium.

INTRODUCTION

An incomplete or full break in the bone is known as a fracture in medicine. Long bone fractures frequently occur in small animal orthopedics. (Prabhukumar et al., 2019).

The ultimate goal of fracture repair is for patients to heal more quickly and walk sooner (Minar et al., 2013). Therefore, monitoring the rate and pattern of fracture healing is essential to identifying issues early on and implementing the appropriate interventions. According to, (Joshi et al. 2022) serum biochemical analysis is one of the monitoring procedures that can detect fracture complications, fracture illnesses, and early signs of fracture healing

Several treatments have been tried to improve bone healing such as bone morphogenetic proteins (BMPs), parathyroid hormone, and bisphosphonate. (Aspenberg, 2013). As well as platelet-rich plasma, and amniotic membrane which considers a gold standard for treating bone abnormalities and have had positive results. The amniotic membrane (AM), a naturally occurring high-molecular-weight biological component, is composed of the basement membrane (BM), an avascular collagenous stroma,

a single layer of epithelial cells, and underlying fibroblasts. Fibronectin, laminin, elastin, type I and type II collagens, and type IV collagen are all common in the extracellular matrix (ECM). Because it has positive effects on cell migration, proliferation, differentiation, and survival, ECM is an essential component for tissue regeneration or organ creation. It can also offer mechanical assistance and add a variety of biophysical and pharmacological stimuli. (Mobasheri et al., 2017; Khashjouri et al., 2019)

Fresh AM does have several drawbacks, though, like the immunogenicity of the tissue, inappropriate preservation techniques, and difficult shipping. Decellularized amniotic membrane scaffolds have been created successfully and used in the regeneration of tissues. It is derived from a fresh amniotic membrane by removing the cellular components. AAM scaffolds contain several characteristics in common with fresh AM, such as a network structure, an abundance of collagen fibers, and a particularly high concentration of Col-II. AAM has been shown in some tests to lessen acute liver injury and speed bone repair. (Jun et al., 2022).

(AM) has developed into a desirable biological tissue. AM is a freely available, placenta-derived biomaterial that poses no moral dilemmas. AM is a source of growth factors and has been shown to have anti-cancer properties as well as low immunogenicity. AM has been utilized in medicine for the treatment of wounds for more than a century. Only a small number of researchers, meanwhile, have examined the potential of AM in orthopedic surgery. It expresses anti-inflammatory proteins and growth factors including VEGF and TGF-1. Lastly, several publications observed that AM had osteogenic properties. (Fenelon et al., 2021)

Platelet-rich plasma (PRP) therapy is one of the alternative autologous treatments that has become more and more popular in recent years for bone healing. (Roffi et al., 2017; Hashim et al., 2021; Alkhalifa et al., 2019; Al-Derawi et al., 2018)

Studies have demonstrated that growth factors derived from thrombocytes released by platelet-rich plasma during bone healing may promote angiogenesis and stimulate the growth and chemotaxis of chondrocytes, osteoblasts, and mesenchymal cells. (Gracia et al., 2012).

The development of nonunion has been attributed to a deficiency in these growth factors, which has been shown to expedite bone repair in high concentrations. Therefore, in theory, platelet concentrates high in growth factors offer osteoinductive therapy for the biological improvement of bone healing. (Esther et al., 2021)

Vascular endothelial growth factor (VEGF), transforming growth factor (TGF beta 1 and 2), Platelet-derived growth factor (PDGF), insulin-like growth factor (IGF-1), and transforming growth factor (TGF beta 1 and 2) are necessary for tissue regeneration and repair. An easy and economical technique to achieve high concentrations of these growth hormones is through autologous platelet concentrations. (Endersen et al., 2021)

Radiological evaluation and clinical assessment are the base of bone healing. Additional techniques for clinically examining the state of the bones include measurements of bone mineral density, radionuclide scans, biochemical bone, and histomorphometry. Only biochemical markers can provide a dynamic picture of the underlying process driving bone resorption, including its etiology, turnover, and the potential to distinguish between normal and delayed repair. Furthermore, they can be used to monitor the immediate effects of therapy and provide an early warning of any harm to the healing process. The biochemical markers' assay techniques are affordable and can be carried out repeatedly on a single animal. (Kumar et al., 2018)

Therefore, the present study was designed to investigate the effects of acellular amniotic membrane loaded with autologous platelet-rich plasma on bone healing biochemically in a dog model

Materials and methods:

The Animal Ethics Committee of the veterinary college at Basrah University approved the current study, and all experiments described in it were carried out strictly with the guidelines for using animal in research released by the mentioned college. The animals were set up under common circumstances and in the shade. Aseptic procedures were used during the operation. Before and after surgery, blood was drawn from the cephalic vein for regular diagnostics. In addition, anti-parasitic medications

(Ivermectin, Levamisole) were given, and each dog received an injection of the rabies vaccine. Manual feeding was used. Additionally, the water and diet were easily accessible as well.

Study Design:

Fifteen mongrel dogs weighing 20–23 kg, aged between 1–1.5 years (irrespective of sex), were used in this study.

All dogs underwent a clinical examination and a complete blood count (CBC) to determine if they had any systemic disease.

The animals were divided into three groups (n = 5 per group). A transverse osteotomy was induced in the midshaft of the left tibia of all dogs and then treated with bioscaffold and platelet-rich plasma before being fixed by a bone plate with screws as the following:

The first group was treated with acellular amniotic membrane only by wrapping it around the fracture site. Acellular amniotic membrane accompanied by platelet-rich plasma was used to treat the second group, while the third group (control) was left untreated.

During the experiment, animals were housed separately in cages.

The Amniotic Membrane Preparation:

The placenta was obtained from a pregnant cow after natural parturition and rinsed three times in a sterile physiological saline solution to dislodge the clots. Immediately after being separated from the chorion, the amnion was thoroughly washed in phosphate-buffered saline (PBS) that contained 100 U/ml penicillin and 100 g/ml streptomycin.

The modified medium (Dulbecco's modified Eagle's medium) and glycerol in a volume ratio of 1:1 were used to store the amniotic membrane at -80°C. The amniotic membrane was defrosted, washed three times with sterile PBS containing the antibiotic, and then sliced into roughly 10 x 10 cm pieces just before use. After two hours of incubation with 0.02 percent ethylenediamine tetra acetic acid at 37°C and gentle scraping with a cell scraper, the overlying amniotic epithelial cells were removed. (Nakase, et al. 2008).

Preparation of The Autologous PRP :

Each dog in the second group (AM+PRP) had 10 ml of blood taken and placed into biochemistry tubes containing citrate-phosphate dextrose solution before being centrifuged for 10 min. at 1500 rpm. Following centrifugation, three layers were produced. After collecting the top plasma layer in a different centrifugation tube and undergoing second centrifugation for 10 minutes at 3000 rpm, two layers—the upper layer being platelet-poor plasma (PPP) and the lower layer being PRP—were obtained. This platelet-rich plasma was used in fracture sites of our experiment on the dogs. (Khalifa et al., 2021)

Surgical Procedure:

After a 12-hour fast, each dog was given the prophylactic antibiotic cefazolin (22 mg/kg intravenously) half an hour before the surgical procedure. Regardless of the length of the operation, further dosages were given every two hours throughout general anesthesia. and they were then anesthetized with xylazine hydrochloride 2% at a rate of 5 mg/kg body weight I/M and ketamine hydrochloride 10% at a rate of 10 mg/kg body weight I/M. the animals were placed in lateral recumbency. The skin on the medial surface of the right hind limb was prepped by hair clipping, then washed with povidone-iodine and draped for sterile surgery from the level of the greater trochanter to the level of the metatarsal. As a surgical technique, the cranio-medial aspect was used. The periosteum was split along the mid-shaft of the right tibia by 4 cm after an incision was made in the leg to expose its medial surface. The tibial diaphysis center underwent a transverse osteotomy by using a charrier bone saw. The fracture site was then flushed several times with normal saline solution (0.9% NaCl) and irrigated with Gentamycin solution. Then AM was applied by wrapping it around the site of the fracture and securing it to the surrounding tissues with many stitches. Then 2 ml of PRP solution which was prepared just before the beginning of the operation, was divided into two parts. One ml was injected into the site of the defect while the second ml of PRP was applied to the acellular amniotic membrane. The procedure was continued for two minutes, allowing the platelets to adhere to the tissues.

The bone segments were immobilized by a five-hole dynamic compression plate size of 2.00 mm which was applied to the tibia medial surface. The four outer holes were created by drilling (with a 2.0-mm drill) into both cortices in a mediolateral location and were used to implant the screws. The hole closest to the fracture site was left empty.

The surgical wound was stitched shut as usual using polyglactin 910 sizes (0) for a close approximation of the adjacent tissues by continuous suture pattern, then S/C tissue with the same suture and pattern, and finally skin was closed by simple interrupted pattern using suture material nylon size (0). All dogs were confined to individual cages throughout the designed duration of the study. Following surgery, animals should receive daily wound care and dressings as well as a 4-day intramuscular course of penicillin-streptomycin at doses of 10000 IU and 20 mg/kg B.W., respectively. No external immobilization was used. The animals were allowed unrestricted weight-bearing after the procedure. The wound sutures were removed 10 days postoperatively. All dogs were subjected to, biochemical examinations till the day 56th.

Biochemical analysis:

Blood samples (10 ml) were collected from each dog before and after surgery on days 0, 14th, 28th, 42th and 56th then serum was separated then sent to the biochemistry lab for assessment of enzyme activity during fracture healing, such as serum calcium and serum alkaline phosphatase.

Serum alkaline phosphatase (IU) was estimated by DGKCSCE's recommended procedure using a semi-auto biochemical analyzer with an alkaline phosphatase kit. While the level of calcium (mg/ dl) in serum was estimated by a modified OCPC method using a semi-auto biochemical analyzer with a commercially available kit. Standard statistical analysis was performed on the serum biochemical parameter data..

Results and discussion:

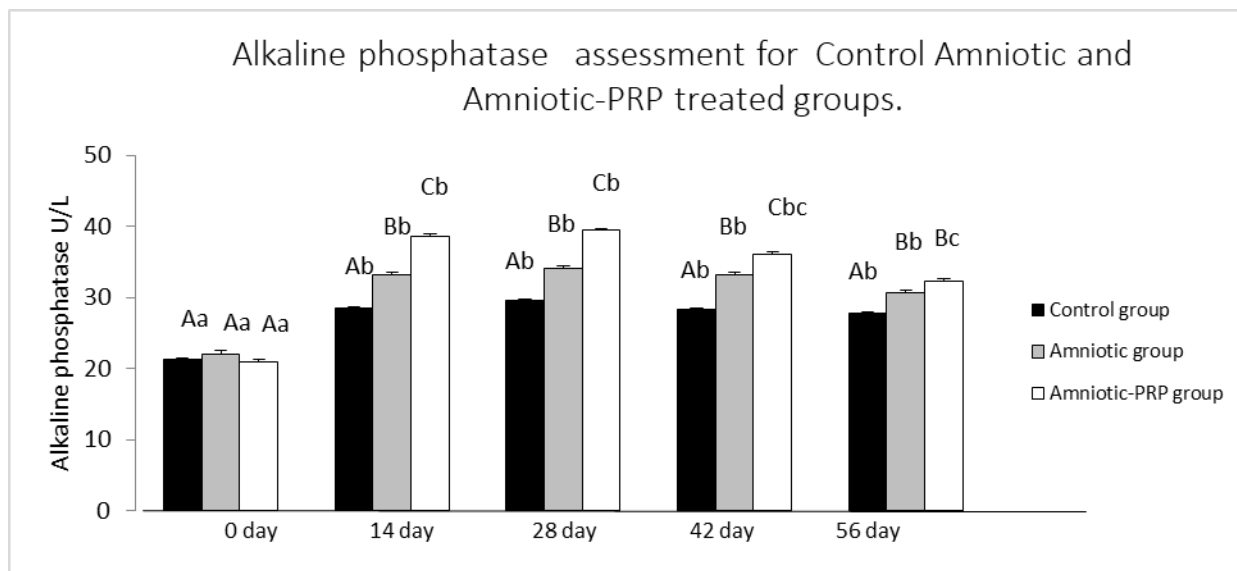
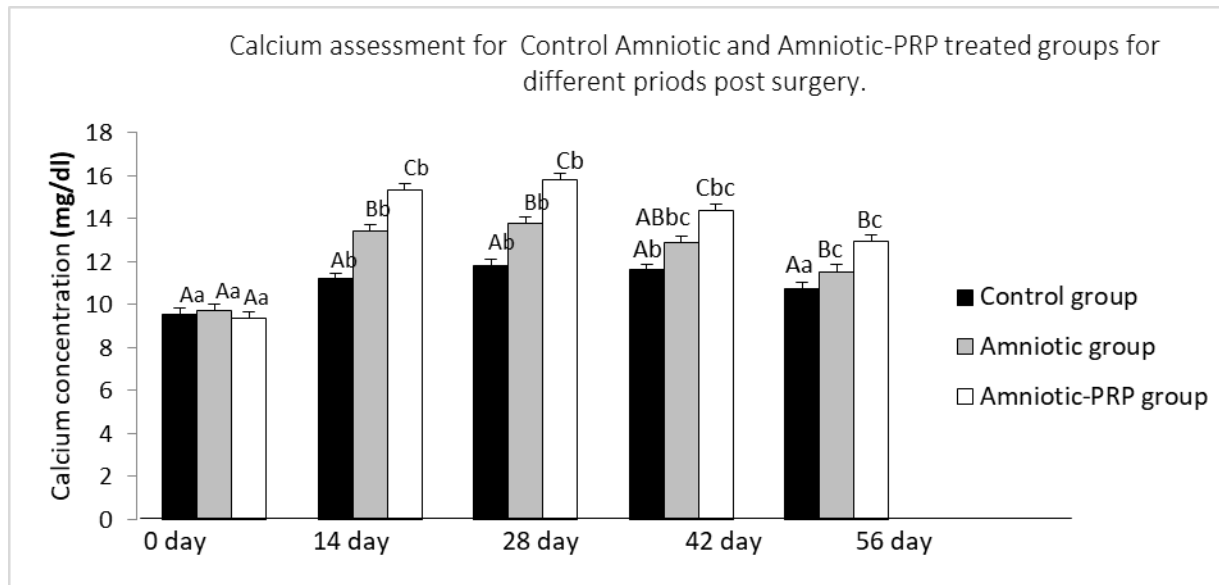


Figure 1: Biochemical study showed alkaline phosphatase concentration for control, Amniotic membrane, and Amniotic membrane + Platelet-rich plasma groups during different periods (0, 14, 28, 42, and 56 days post-surgery). ABC Different letters among groups indicate significant differences ($P < 0.05$). abc Different letters within the group indicate significant differences ($P < 0.05$).

Table 1: Alkaline phosphatase concentration for control, Amniotic membrane, and Amniotic membrane + Platelet-rich plasma groups during different periods (0, 14, 28, 42, and 56 days post-surgery). (means and standard errors).

Groups	0 days	14 days	28 days	42 days	56 days
Control	21.29±1.15 ^{Aa}	28.55±0.86 ^{Ab}	29.51±1.37 ^{Ab}	28.35±0.67 ^{Ab}	27.8±0.5 ^{Ab}
AM	22.11±1.02 ^{Aa}	33.18±1.24 ^{Bb}	34.14±0.66 ^{Bb}	33.25±0.103 ^{Bb}	30.71±1.8 ^{Bc}
AM + PRP	21.02±0.92 ^{Aa}	38.61±0.92 ^{Cb}	39.4±1.21 ^{Cb}	36.07±1.7 ^{Cbc}	32.29±0.7 ^{Bc}

ABC Different letters within each column indicates significant differences (P<0.05). abc Different letters within each row indicates significant differences (P<0.05).



Amniotic membrane + Platelet rich plasma groups during different periods (0, 14, 28, 42 and 56 days post-surgery). ABC Different letters among groups indicates significant differences (P<0.05). abc Different letters within group indicates significant differences (P<0.05)

Table 2 : Calcium concentration for control, Amniotic membrane , and Amniotic membrane + Platelet rich plasma groups during different periods (0, 14, 28, 42 and 56 days post surgery). (means and standard errors).

Groups	0 days	14 days	28 days	42 days	56 days
Control	9.522±0.29 ^{Aa}	11.19±0.21 ^{Ab}	11.79±0.4 ^{Ab}	11.61±0.38 ^{Ab}	10.72±0.06 ^{Aa}
AM	9.72±0.31 ^{Aa}	13.44±0.22 ^{Bb}	13.79±0.36 ^{Bb}	12.86±0.45 ^{ABbc}	11.54±0.09 ^{Bc}
AM + PRP	9.34±0.3 ^{Aa}	15.33±0.52 ^{Bbc}	15.79±0.66 ^{Cc}	14.4±0.4 ^{Bbc}	12.94±0.1 ^{Bc}

ABC Different letters within each column indicates significant differences (P<0.05). abc Different letters within each row indicates significant differences (P<0.05).

In dogs, the normal ranges for alkaline phosphatase and serum calcium were 9.1–11.7 mg/dL and 1-114 IU/L, respectively (Latimer, 2011).

Calcium levels (mg/dL):

In group dogs, serum calcium level significantly increased ($p \leq 0.01$) from the 14th to 28th day when compared to pre-operative day 0. It gradually came back to normal by day 56. In control, amniotic membrane, and amniotic membrane with platelet-rich plasma groups, the serum calcium level increased ($p \leq 0.01$) on days 14 and 28 followed by a gradually decreasing trend after day 28 to day 56. (11.19 ± 0.21 - 11.79 ± 0.4), 13.79 ± 0.36 , (15.33 ± 0.52 - 15.79 ± 0.66) respectively. Table 2.- 13.44 ± 0.22

When groups were compared, it was shown that the serum calcium level was significantly ($p \leq 0.05$) high on day 28 in all groups but it was higher in group AM+PRP as compared to other groups as well as the level of calcium of group AM was higher than the level in the control group. Figure 2 displays the Mean \pm SE calcium (mg/dL) values for each group.

When a fracture heals, calcium is crucial for the process of mineralization, which turns a soft callus into a hard callus (Claes et al., 2012).

It was possible to explain the initial increase and subsequent fall in serum calcium levels by the crystalline salt deposition in the organic matrix, which was primarily made up of calcium and phosphates. (Fischer et al., 2018) ..

Alkaline phosphatase levels (IU/L):

Table 1 shows the variations in serum alkaline phosphatase mean \pm SE values throughout various periods.

The levels of serum alkaline phosphatase varied considerably ($P 0.01$) between postoperative days at all times (0 day, 14 day, 28 day, 42 day, and 56 day) of the group AM+PRP, group AM, and group control.

The highest values (39.4 ± 1.21), (34.14 ± 0.66), and (29.51 ± 1.37) of all groups were observed respectively at the 28th day postoperative whereas the lowest values

(32.29 ± 0.7), (30.71 ± 1.8), and (27.8 ± 0.5) were recorded respectively on the 56th day.

On day 28, the serum alkaline phosphatase level in the AM + PRP group was significantly ($p \leq 0.05$) greater than that in the amniotic membrane and control groups.

When compared to the pre-operative level, the alkaline phosphatase enzyme level significantly ($p \leq 0.05$) rose in all animal groups from day 14 to day 28.

When all groups were examined, it became clear that the animals in the group AM + PRP had significantly greater ($p < 0.05$) alkaline phosphatase levels on days 14 and 28 than the animals in the group AM and control group. (figure 1).

Serum alkaline phosphatase levels rose from the day before surgery to the 28th day, then dropped and returned to normal levels by the 56th day.

On the 28th postoperative day, serum alkaline phosphatase was found to be at its highest level. (Gracias et al., 2022).

The increased chondroblastic proliferation, which occurs in bone production during shattered bone repair, was the source of the rise in blood alkaline phosphatase levels in group AM + PRP. The majority of the rise was also due to the periosteum breaking down bone, which is a significant source of serum alkaline phosphatase. The outcomes corroborated those of Kumar et al. (2018), who reported that the majority of internal fixation surgeries utilizing the compression technique showed an elevation in alkaline phosphatase due to osteoblastic activity...

The mineralization process at the osteotomy site may be to blame for the rise in serum calcium levels as mentioned by Bhavani et al (2022).

The gradual decrease in serum calcium level might be due to the deposition of the excessive calcium at the site of the fracture and a further increase in its value on the 42th to 56th day attributed to the remodeling phase.

However, compared to animals in the control group without biomaterial, calcium levels fluctuated more in the animals in the AM + PRP and AM groups. The findings presented here support those made by Komnenou et al (2005).

On days 14 and 28 following surgery, there was a significant increase in serum alkaline phosphatase ($p < 0.05$) and it decreased in all three groups of animals on days 42 to 56 after surgery. This may be caused by the amniotic membrane being wrapped around the fracture site and loaded with platelet-rich plasma biomaterials, which further boosts osteoblastic activity according to Chaurasia et al (2009).

Alkaline phosphatase, which is involved in matrix production and mineralization, is secreted in significant amounts by osteoblasts. Alkaline phosphatase is thought to either boost the amount of inorganic phosphate or inorganic pyrophosphate in the area, both of which are essential for fracture healing. Based on the aforementioned results, it can be inferred that variations in hematobiochemical parameters at various postoperative days are closely associated with the various stages of fracture healing. (Chaurasia et al., 2019).

Alkaline phosphatase is an important marker for bone formation as it is secreted by osteoblasts. This enzyme stimulates the mineralization of the osteoid by raising the local concentration of calcium phosphate as mentioned by Anaraki et al (2021).

In proportion to the degree of callus formation, there was a correlation between the activity of alkaline phosphatase increasing, decreasing, or being unchanged. The little callus production as a result of the fracture's stable and rigid fixation could be the cause of the minor or nonexistent change in alkaline phosphatase activity (Muljadic et al., 2013).

Platelet-derived growth factors (PDGF) and other proteins released by platelets are closely correlated with osteoblast differentiation, proliferation, and metabolic activity, which activate intracellular signaling pathways for matrix formation and cellular differentiation. The early inflammatory phase of fracture healing, which includes the development of a fracture hematoma and the proliferation of mesenchymal stem cells produced from the bone marrow, is significantly influenced by platelet-rich plasma (Canbeyeli et al., 2018).

Elevated ALP levels are typically an indication of a liver or bone problem because ALP is most prevalent in the bones and liver. ALP levels will increase if the liver is damaged or obstructed. This will also happen if the activity of bone cells increases (Mahmood and Chawshli, 2019).

Increased chondroblastic proliferation to promote bone formation during shattered bone repair may be to blame for the rise in serum alkaline phosphatase levels. Additionally, the periosteum of destroyed bone, which was a rich source of serum alkaline phosphatase, contributed the most. The conclusions agreed with those of Tembhurne (2006). Alkaline phosphatase activity was found to increase up to the 21st postoperative day before decreasing down to the nearly base level on the 60th post-operative day, according to Rani et al (2012).

One crucial aspect that provides an early indicator of the degree of fracture healing in injured animals is the monitoring of serum calcium levels. When compared to its pre-experimental value, a significant ($P < 0.05$) rise in serum calcium value was seen in the current investigation on days 14 and 28 of the postoperative period.

Increased chondroblastic proliferation to promote bone formation during shattered bone repair may be to blame for the rise in serum alkaline phosphatase levels. Additionally, the periosteum of destroyed bone, which was a rich source of serum alkaline phosphatase, contributed the most. The conclusions agreed with those of Tembhurne (2006).

Alkaline phosphatase activity was found to increase up to the 21st postoperative day before decreasing down to nearly base level on the 60th post-operative day, according to Rani et al (2012).

One crucial aspect that provides an early indicator of the degree of fracture healing in injured animals is the monitoring of serum calcium levels. When compared to its pre-experimental value, a significant ($P < 0.05$) rise in serum calcium value was seen in the current investigation at days 14 and 28 of the postoperative period.

This might be due to the deposition of calcium to the site of the segmental defect in response to stimulation of the thyroid gland to secrete calcitonin which is a normal physiological phenomenon during fracture healing. In agreement with the present study

Kumari et al (2021) also reported that high levels of calcium in the blood and extracellular fluids trigger the deposition of calcium phosphate crystals in the osteoid and make it harder.

This may be the result of calcium deposition at the segmental defect site as a result of stimulation of calcitonin secretion by the thyroid gland, a physiological process that occurs normally during fracture healing. In keeping with the findings of the current investigation, Kumari et al. (2021) also noted that the osteoid becomes tougher as a result of the deposition of calcium phosphate crystals in the blood and extracellular fluids.

Growth factors included in PRP directly aid in fracture healing. growth factors generated from activated platelets to promote mitogenesis, angiogenesis, bone remodeling, and the phagocytosis of injured tissue during fracture healing, PDGF binds to transmembrane receptors on osteoblasts, osteoclasts, chondrocytes, fibroblasts, and macrophages..

(Liebig et al., 2020)

It has been demonstrated that transforming growth factor beta TGF controls progenitor cell adhesion, chemotaxis, proliferation, and differentiation in the wound bed. Furthermore, mesenchymal stem cell MSCs quickly upregulate the expression of type II collagen due to the potent contraindicative growth factor TGF. The fact that chondrogenic proliferation and endochondral ossification are when TGF immunostaining is at its strongest supports the assumption that TGF plays a substantial part in the process of repairing bones. Chondrocytes and osteoblasts are also rich in TGF receptors. (Liebig et al., 2020)

It has been demonstrated that platelet-derived growth factor promotes the proliferation of osteoblastic and trabecular bone cells. (Castillo – Cardiel et al .,2017).

PRP promotes fracture repair by inducing osteogenic differentiation in bone marrow stem cells. (2017) Roffi et al.

Numerous growth factors found in PRP have been proven to promote osteogenesis. In contrast to VEGF and FGF-2, which have enhanced angiogenesis and revascularization in bone, platelet-derived growth factor (PDGF), vascular endothelial growth factor (VEGF), and fibroblast growth factor-2 (FGF-2) have been demonstrated to boost osteoblastic progenitor cell proliferation. (Rai et al., 2007).

It has been demonstrated that PRP-treated fracture sites recover at a pace that is 2–3 times faster than those treated without PRP.

Growth factors, such as PDGF, insulin-like growth factor (IGF), and TGF- β , regulate the bone-regenerating effects of PRP. (Kanthan et al., 2011).

In addition, 2 members of the TGF- β superfamily, TGF- β 1 and bone morphogenic proteins (BMPs) stimulate osteoblastic differentiation as well as the synthesis of new bone marrow matrix. (Roldan et al., 2004)

Therefore, the components that compose PRP result in enhanced bone healing and regeneration, leading to improved osteoid bridging and bone union.

As a result, the components of PRP promote increased osteoid bridging and bone union by enhancing bone healing and regeneration.

As a result of PDGF's ability to constantly improve wound healing and stimulate bone production, bone regeneration is improved. The promotion of mesenchymal stem cell proliferation and subsequent osteogenic differentiation have both been linked to transforming growth factor- β . (Watabe et al., 2009)

The bone plate allowed for more secure and stiff fixation of the fracture and accelerated fracture healing. (Joshi et al., 2002)..

The scaffold helped to localize the platelet-released cell-signaling chemicals in PRP that may encourage osteogenesis. (Kanthan et al., 2011).

In addition to having possible positive effects on the rate of healing and the histology caliber of osseous repair, platelet-rich plasma also affected the biomechanical caliber of the bone. PRP demonstrated increased bone strength, torsion, and torque in addition to improved load bearing. In the clinical situation, this might help with the rehabilitation of the bone injury. Fewer adhesions are related to earlier mobilization and weight bearing. (Gianakos et al., 2015).

When AM was implanted over the defect, bone growth was dramatically accelerated as opposed to the defect being left unfilled. Compared to bone reduction without membrane, circumferentially wrapping AM around the fracture line greatly accelerated fracture healing. (Fenelon et al., 2020).

The AM scaffold offered an osteoconductive environment for cell migration and angiogenesis and was integrated alongside host bone resorption without eliciting an inflammatory or immunological response or accelerating scaffold biodegradation. For AM to become osseointegrated, either direct bone deposition onto the scaffold was used, resulting in a mineralized contact between AM and the freshly produced bone, or the collagenous AM was incorporated into the newly deposited bone.

As a substrate for cell motility, adhesion, proliferation, and matrix deposition, AM collagen's presence aided the osteogenic process.

Endogenous periosteal cells surround the scaffold and support neovascularization from the defect, facilitating osteoconduction. (Dziedzic et al., 2021).

The findings of the current study showed that Group AM+PRP had the best results in terms of the production of new bone tissue when compared to Groups Control and AM. (Dziedzic et al., 2021).

The findings of the current study showed that Group AM+PRP had the best results in terms of the production of new bone tissue when compared to Groups Control and AM.

According to Phaneendra et al. (2017), the identification of particular biochemical markers of bone formation in serum, such as alkaline phosphatase activity, can be clinically helpful in assessing the healing process progress and acts as an additional tool in identifying fractures that are likely to develop a non-union.

It was concluded that serum calcium and alkaline phosphatase can be used as useful biochemical markers in assessing bone formation and contributed to proving the superiority of using the amniotic membrane loaded with platelet-rich plasma in promoting bone healing. These biochemical parameters, in conjunction with clinical and radiographic examinations, provide reliable information about the degree of bone healing.

REFERENCES

- 1- Prabhukumar, M.D., Dileepkumar, K.M., Devanand, C.B., Syam, K.V., Raj, I.V., Anoop, S., Nair, S.S. and Philip, L.M. (2019). Haemato-biochemical observations on treatment of long bone fracture using elastic stable intramedullary nailing in dogs. *J. Indian Vet. Assoc. Kerala*.17, 45-49.
- 2- Joshi, S., Venugopal S., Nair, S., Sunilkumar, N., and Martin, K. (2022). Evaluation of serum calcium, phosphorus and alkaline phosphatase levels during long bone fracture repair in dogs stabilized with string of pearls plating technique. *Journal of Veterinary and Animal Sciences*.53 (1), 27-31.
- 3- Aspenberg, P. (2013). Special Review: Accelerating fracture repair in humans: a reading of old experiments and recent clinical trials. *Bonekey Rep*. 2 (24).
- 4- Mobasheri, A., Rayman, M., Gualillo, O., Sellam, J. Kraan, P. (2017). The role of metabolism in the pathogenesis of osteoarthritis. *Nature Reviews Rheumatology* volume 13, 302–311.
- 5- Jun, Z., Yuping, W., Yanran, H., Ziming, L., Yuwan, L., Xizhong, Z. (2022). Human acellular amniotic membrane scaffolds encapsulating juvenile cartilage fragments accelerate the repair of rabbit osteochondral defects. *Bone & Joint Research*. 11 (6).
- 6- Fenelon, M., Etchebarne, M., Siadous, R., Grémare, A., Durand, M. (2021). Comparison of amniotic membrane versus the induced membrane for bone regeneration in long bone segmental defects using calcium phosphate cement loaded with BMP-2. *Materials Science and Engineering J*. 124.
- 7- Roffi, A., Matteo, B., Krishnakumar, G., Kon, E., Filardo, G. (2017). Platelet-rich plasma for the treatment of bone defects: from pre-clinical rational to evidence in the clinical practice. A systematic review. *International Orthopaedics*. 41, 221–237.
- 8- Garcia, P., Pieruschka, A., Klein, M., Tami, A., Histing, T., Holstein, J.H., Scheuer, C., (2012). Temporal and spatial vascularization patterns of unions and nonunions: role of vascular endothelial growth factor and bone morphogenetic proteins. (Platelet-rich plasma and fibrin glue-coated bioactive ceramics enhance growth and differentiation of goat bone marrow-derived stem cells. *The Journal of Bone & Joint Surgery*. 94 (1), 49-58.
- 9- Esther M.M., Van Lieshout, V., Hartog, D. (2021). Effect of platelet-rich plasma on fracture healing. *Injury*. 52 (2), 58 – 66.
- 10 - Andersen, C., Wragg, N., Shariatzadeh, M., & Wilson, S. (2021). The Use of Platelet-Rich Plasma (PRP) for the Management of Non-union Fractures. *Current Osteoporosis Reports*. 19, 1–14.

- 11- Kumar, K., Prasad, V., Lakshmi N.D., and Raju N. (2018). Evaluation of biochemical parameters for assessment of fracture healing in dogs. *The Pharma Innovation Journal*. 7 (3), 577-580.
- 12- Latimer, K.S. (2011). *Duncan and Prasse's Veterinary Laboratory Medicine: Clinical Pathology*. John Wiley & Sons, Canada, 515p.
- 13- Claes, L., Recknagel, S., Ignatius, A. (2012). Fracture healing under healthy and inflammatory conditions. *Nat. Rev. Rheumatol.* 8, 133-143.
- 14- Fischer, V., Haffner-Luntzer, M., Amling, M. and Ignatius, A. (2018). Calcium and vitamin D in bone fracture healing and post-traumatic bone turnover. *Eur. Cell. Matr.* 35, 365-385.
- 15- Swathi, B. (2019). Clinical studies on string of pearls plating and positive profile end threaded intramedullary pinning or long one distal third diaphyseal fracture in dogs. M.V.Sc thesis, Sri Venkateshwara Veterinary University, Tirupati, 110p.
- 16- Patil, M., Dilipkumar, D., Shivaprakash, B. V., Kasaralikal, V.R., Tikare, V.P. and Ramesh, B.K. (2017). Physiological and haemato-biochemical changes during repair of femur fracture in dogs. *Pharma Innovation J.* 6: 381-385. P.
- 17- Muljadic, A., Poljak-Guberina, R., Zivkovic, O., Bilic, V. and Guberina, M. (2013). Course and rate of post-fracture bone healing in correlation with bone-specific alkaline phosphatase and bone callus formation. *Collegium antropologicum*. 37: 1275-1283.
- 18- Mahmood, T., Chawshli, O. (2019). The Effect of Submucosal Injection of Plasma-Rich Platelets on Blood Inflammatory Markers for Patients with Bimaxillary Protrusion Undergoing Orthodontic Treatment. *Int. J. Inflam.* 2019.
- 19- Canbeyli, I., Akgun, R., Sahin, O., Terzi, A., and Tuncay, L. (2018). Platelet-rich plasma decreases fibroblastic activity and woven bone formation with no significant immunohistochemical effect on long-bone healing: An experimental animal study with radiological outcomes. *Journal of Orthopaedic Surgery*. 26 (3) 1-10.
- 20- Joshi, E., Venugopa, S., Nair, S., Sunilkumar, S., and Martin, K. (2022). Evaluation of serum calcium, phosphorus and alkaline phosphatase levels during long bone fracture repair in dogs stabilized with string of pearls plating technique. *Journal of Veterinary and Animal Sciences*. 53 (1) : 27-31.
- 21- Phaneendra, M., Lakshmi, N., Raghunath, M., Raju, N., and Adilaxamma, K., (2017). Evaluation of Biochemical and Haematological Parameters for Assessment of Compound Fracture Healing in Dogs with Local Antibiotic Treatment. *International journal of livestock research*. 8 (4) , 138 – 143.
- 22- Gracias, R., Dilipkumar, D., Bhagavantappa, B., Kasaralikal, V., Waghe, P., Manjunath Patil, M., (2022). Evaluation of tibial fracture healing by estimation of biochemical and physiological parameters in dogs. *The Pharma Innovation Journal*. 11 (2) : 1654-1657.
- 23- Chaurasia, A., Jawre, S., Singh, R., Shahi, A., Pathak, R., Das, B., and Kumar, N., (2019) Evaluation of Haemato-Biochemical Parameters using Different Biomaterials in Fracture Healing of Dogs. *Int. J. Curr. Microbiol. App. Sci.* 8 (5) : 2265-2271.
- 24- Kumari, V., Houzha, R., Sharma, M., Kandpal, M., Shukla, S.K., (2021). Study on haematobiochemical changes in induced segmental defect in rabbits. *The Pharma Innovation Journal*. 10 (8) : 591-594.
- 25- Anaraki, N., Beyraghi, A., Raisi, A., Davoodi, F., Farjanikish, G., and Sadegh, A., (2021). The effect of aqueous extract of *Prunus dulcis* on tibial bone healing in the rabbit. *Journal of Orthopaedic Surgery and Research*. 16 (362).
- 26- Komnenou, A., Karayannopoulou, M., Polizopoulou, ZS., Consantinidis, TC., Dessiris, A., Correlation of serum alkaline phosphatase activity with the healing process of long bone fractures in dogs. *Veterinary Clinical Pathology*. 34 (1) : 35-38.
- 27- Bhavani, D., N Krishna, NVV., Sreenu, M., and Naidu, G., (2022). Evaluation of biochemical parameters for assessment of long bone fracture healing in young dogs subjected to bone plating. *The pharma innovation journal*. 11 (7) : 642 – 644.
- 28- Liebig, B., Kisiday, J., Bahney, C., Ehrhart, N., Goodrich, L., (2020). The platelet-rich plasma and mesenchymal stem cell milieu: A review of therapeutic effects on bone healing. *Journal of orthopedic research*. 38 (12) : 2539-2550.
- 29- Castillo-Cardiel, G., Medina-Quintana, V., Lomelí-Enríquez, M., Medrano-Munoz, F., Guerrero-Velazquez, C., Contreras-Lopez, C., (2017). Platelet-rich plasma and its effect in bone regeneration in mandibular fractures. *Controlled clinical trial Gac Med Mex J*. 153 : 421-426.
- 30- Roffi, A., Matteo, B., Krishnakumar, G., Kon, E., & Filardo, G., (2017). Platelet-rich plasma for the treatment of bone defects: from pre-clinical rational to evidence in the clinical practice. *A systematic review. International Orthopaedics*. 41, 221-237.
- 31- Rai, B., Oest, M., Dupon, K., Ho, K., Teoh, S., Guldborg, R., (2007) Combination of platelet-rich plasma with polycaprolactone-tricalcium phosphate scaffolds for segmental bone defect repair. *J Biomed Mater Res A*. 81 (4) : 888 -899.
- 32- Marx, R., Carlson, E., Eichstaedt, R., Schimmele, S., Strauss, J., Georgeff, K., (1998). Platelet-rich plasma: growth factor enhancement for bone grafts. *Oral Surg Oral Med Oral Pathol Oral Radiol Endod.* 85 (6) : 638 - 646.
- 33- Roldán, J., Jepsen, S., Miller, J., et al. (2004). Bone formation in the presence of platelet-rich plasma vs. bone morphogenetic protein-7. *Bone*. 34 (1) : 80 - 90.
- 34- Watabe, T., Miyazono, K., (2009). Roles of TGF-beta family signaling in stem cell renewal and differentiation. *Cell Res*. 19 (1) : 103 - 115.
- 35- Kanthan, S., Kavitha, G., Addi, S., Choon, D., Kamarul, T., (2011). Platelet-rich plasma (PRP) enhances bone healing in non-union critical sized defects: a preliminary study involving rabbit models. *Injury*. 42 (8) : 782 – 789.
- 36- Gianakos, A., Zambrana, L., Savage-Elliott, I., Lane, J., Kennedy, J., (2015). Platelet-Rich Plasma in the Animal Long-Bone Model: An Analysis of Basic Science Evidence. *Orthopedics*. 38 (12).
- 37- Fenelon, M., Etchebarne, M., Siadous, R., Gremare, A., Durand, M., Loic Sentilhes, L., et al., (2020) Assessment of fresh and preserved amniotic membrane for guided bone regeneration in mice. *Journal of Biomaterial Research*. 108 (10) : 2044 – 2056.
- 38- Dziedzic, D., Francisco, J., Mogharbel, B., Irioda, A., Stricker, P., Floriano, J., et al., (2021). Combined Biomaterials: Amniotic Membrane and Adipose Tissue to Restore Injured Bone as Promoter of Calcification in Bone Regeneration: Preclinical Model. *Calcified Tissue International* 108, 667-679.
- 39- Hashim, A., Abd, H., Hellal, M., (2021). Histopathology Study of the Platelet Rich Plasma on the Wound Healing in Rabbits. *Medico-legal Update*. 21 (2).
- 40- Al-Dirawi, A., Sharifi, D., Bokaei, S., Mokhtari, R., Alireza Bashiri, A., Shad, H., (2018). Clinical and Radiological Evaluation of Transplanted Fresh Ear Cartilage Impregnated with the Mesenchymal Cells & PRP in Treatment of Growth Plate Injury in Lamb. *Iran J Vet Med.* 12 (4) , 283-292
- 41- Khashjooi, B., Ghamsari, S., Dehghan, M., Mohajeri, S., Gholami, H., Golshahi, H., (2019). Evaluation of the Effects of Adipose Derived Mesenchymal Stem Cells Cultured on Decellularized Amniotic Membrane in Wound Healing of Distal Part of the Limbs in Horse. *Iranian Journal of Veterinary M23- edicine*. 13 (1) . 11-25.
- 42- Al-Khalifah, R., Sharifi, D., Bokaei, S., Bashiri, S., Shad, H., (2019). Evaluation of the Hydroxyproline Content in the Frozen Allograft Tendon Impregnated with the Mesenchyme Cells & PRP in Lamb. *The 13th Iranian Symposium of Veterinary Surgery (ISVS)* p 28.