

Brodie's Abscess Of The Distal Tibia: A Case Study Analysis

Dr Prabhav dessai^{1*}, Dr Nandini Padte², Dr Praneet Patil³, Dr Amit sarkar⁴

¹Senior resident, Department of orthopaedic surgery, Goa medical College, India Email: dessaiprabhav@gmail.com

²Senior resident, Department of orthopaedic surgery, Goa medical College, India, Email: zenincaster@gmail.com

³Junior resident, Department of orthopaedic surgery, Goa medical College, India, Email: p.praneet38@gmail.com

⁴Junior resident, Department of orthopaedic surgery, Goa medical College, India Email: rekrastima@gmail.com

*Corresponding Author: - Dr Prabhav dessai

*Senior resident, Department of orthopaedic surgery, Goa medical College, India Email: dessaiprabhav@gmail.com

Doi: 10.47750/pnr.2022.13. S05.138

Abstract

Brodie's abscess is a condition involved with a localised osteomyelitis and a collection in the metaphysis of the long bones, mainly seen in the distal tibia area among male children. The aim of the study is to analyse relevant case studies of brodie's abscess of the distal tibia and the treatment methods for complete recovery without long-term recurrence. The study uses a thematic analytical approach to analyse the case studies involving the surgical treatments of a 17-year and 12-year-old male and a 14-year-old female to indicate that surgical management with or without antibiotics is the most successful treatment. Use of radiology for diagnostic analysis is also discussed along with a detailed description of the methods of surgery.

Keywords: Brodie's abscess, surgical management, diagnosis, radiology, orthopaedic infection

INTRODUCTION

Brodie's abscess is a localised osteomyelitis comprising a collection in the metaphysis of the long bones. As the result of a chronic infection situated in the bones and causing localised abscess typically found in children (male) which was first described in 1832 in the medical literature, it is characterised by pain, localised tenderness and a delayed pain onset or absence of systemic inflammatory symptoms. The most common bone affected by brodie's abscess is the tibia, for which the most common treatment method is only surgery (17%) or surgery and antibiotics (77%), that leads to favourable recovery (Van der Naald *et al.* 2019). Thus, the study aims at conducting a comprehensive case study analysis of brodie's abscess of the distal tibia and the treatment methods for complete recovery without long-term recurrence.

LITERATURE REVIEW

Incidents of brodie's abscess

The impact of brodie's abscess is seen majorly among the children, defined by the presence of prominently defined abscess in cancellous bone. As stated by Foster *et al.* (2019), around 5 in 100,000 children per year are recorded with incidents of subacute osteomyelitis in high-income countries. The presence can be higher in low and medium-income countries as well, however, lack of proper survey and recording of incidents limits the ability for an accurate global assessment. On the other hand, adult males can also suffer from this condition despite its rarity among the adult population. As studied by Chen *et al.* (2021), Staphylococcus aureus osteomyelitis was diagnosed causing brodie's abscess in a 50-year-old man who had a childhood history of fracture of right tibia. After suffering from pain, warmth/inflammation and swelling for several months, resulting in a 0.7×1.2cm proximal tibial fluid collection along with a penumbra sign and peripheral enhancement diagnosed through an MRI (Chen *et al.* 2021). Thus, the recorded incidents of brodie's abscess are seen extensively among children and in rare cases adult men, demanding early diagnosis.

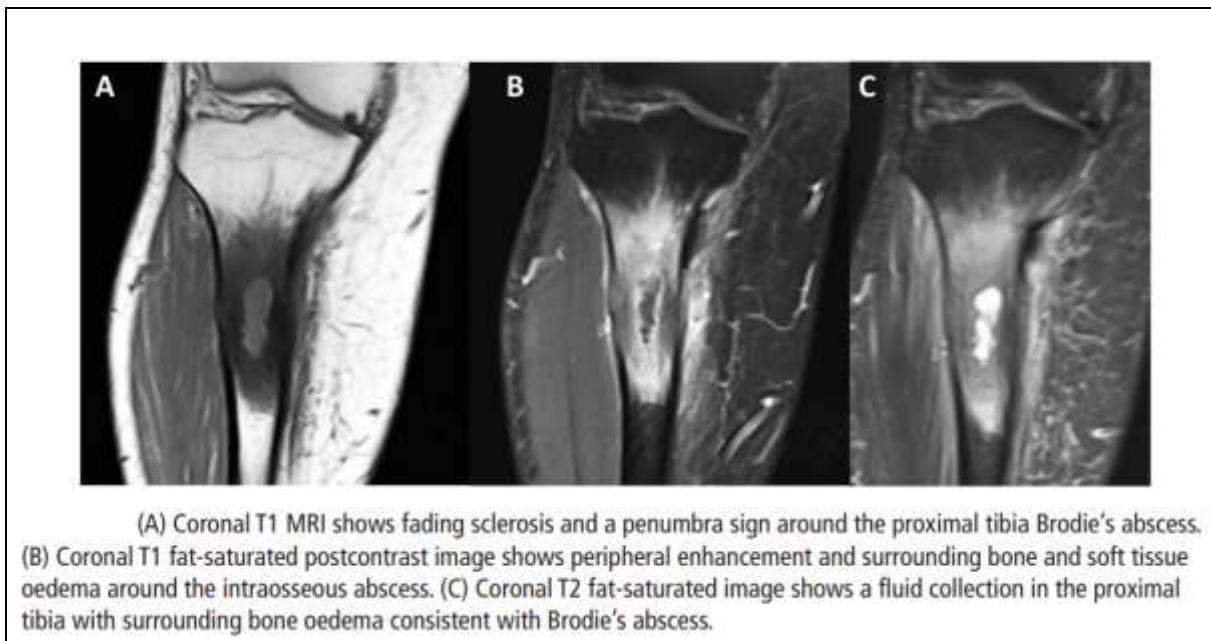


Figure 1: MRI of the 50-year-old patient
(Source: Chen *et al.* 2021)

DIAGNOSIS AND TREATMENT METHODS FOR BRODIE'S ABSCESS

The most effective treatment method for brodie's abscess is a surgical removal of the infected bone. The treatment procedure varies due to the condition of the patient. As per the words of Van der Naald *et al.* (2019), 94% treatment methods consist of surgery with 77% combined with antibiotics prescriptions while only 11 cases reviewed in the study showed recovery with antibiotics alone. A study of microbiological culture analysis of reported brodie's abscess illustrates 65% staphylococcus aureus followed by 25.8% of no growth (Naald *et al.* 2019). Hence, the treatment procedures must focus on the growth culture for long-term recovery. On the other hand, Hogeia *et al.* (2021) state that the identification process for brodie's abscess for a 21-year male, refusing medical care consisted of computer tomography (CT), X-Ray and MRI, followed by treatment with intense debridement, reconstruction of defects, and prescription of long-term specific antibiotics based on the culture harvested intra-operatively. Thus, the diagnosis and treatment procedure are complex and dynamic for each patient, enhancing criticality of the condition.

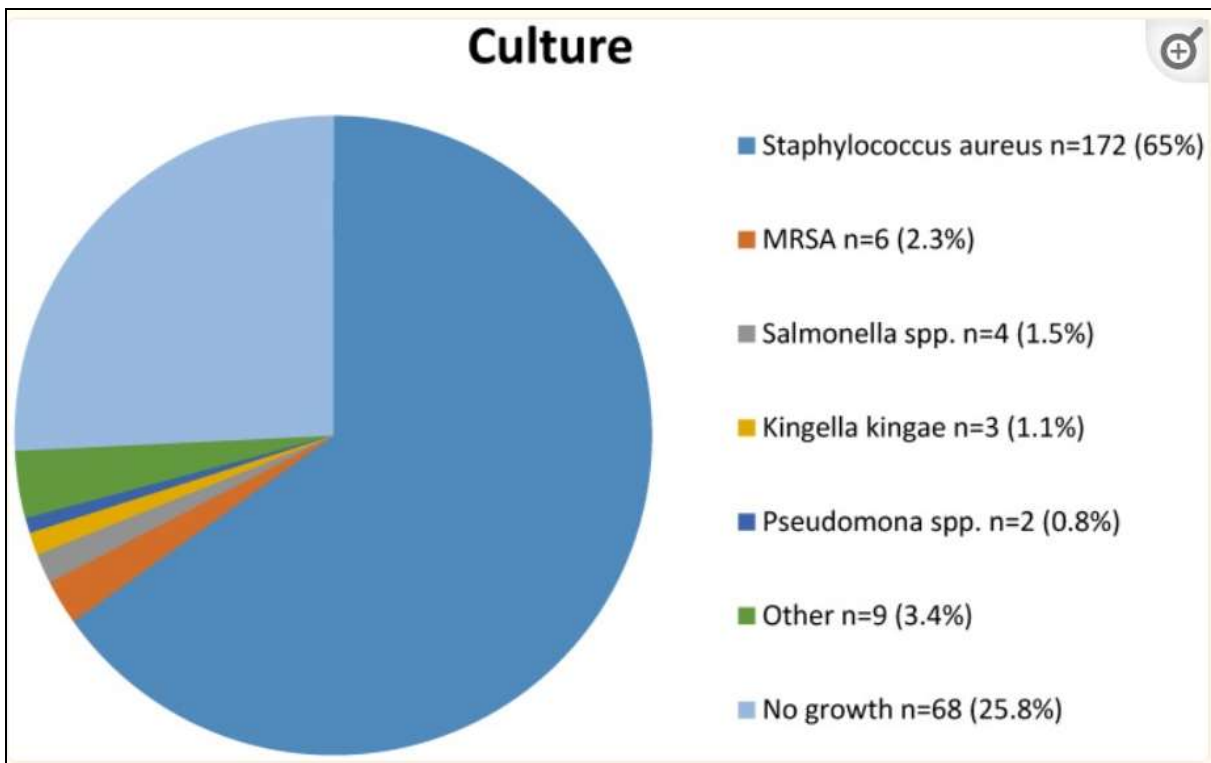


Figure 2: Microbiological analysis of cultures from brodie's abscess
(Source: Naald *et al.* 2019)

CHALLENGES OF TREATMENT METHODS FOR BRODIE'S ABSCESS

Diagnosis process for brodie's abscess can be challenging as patients often disregard the symptoms of intermittent pain and inflammation for several months before seeking treatment. For example, a case of a 14-year-old girl was challenging to diagnose as the associated symptoms were mild, without any weight loss or fever yet the condition was found to be worsening and acute leading to progressive atraumatic knee pain (Lowe *et al.* 2020). On the other hand, successful treatment may be challenging as after full-recovery, recurrences are seen as well. As studied by Van der Naald *et al.* (2019), 15% recurrence was reported while chronic osteomyelitis related recurrence was lower than 20%. Thus, the challenges are to be mitigated by the adoption of advanced diagnosis and treatment methods.

METHODOLOGY

The study conducts a case study analysis, reviewing medical literature related to recorded incidents of brodie's abscess. Based on a deductive approach, the study collects secondary qualitative data, reviewing multiple case studies to identify the common themes and patterns associated with the brodie's abscess. The data collection process involved a targeted search in various databases such as Google Scholar and ProQuest to acquire peer-reviewed journal articles and relevant case studies based on a purposive sampling method. A thematic analysis is conducted on the gathered data, forming a systemic and empirical study. Thus, the overall analysis of reliable and valid secondary qualitative data is successful in making informed conclusions on the topic.

FINDINGS AND ANALYSIS

Theme 1: Case study analysis of brodie's abscess

A primary case study, of a 17-year-old boy with successful diagnosis and surgical management is first analysed. The patient was feeling pain in the distal part of the since for a prolonged period of 2 years. The diagnosis process indicated a Positive CRP, ESR 45 mm/ and Total count 7,800 (N-65% L- 15%). Differential diagnoses further revealed the following: eosinphilic granuloma of tuberculosis, Langerhans cell histiocytosis, Osteoid osteoma and chondrasarcoma. The operative procedure included an excision curettage of abscess and insertion of stimulan with antibiotic. Management of lesion was done by creating a cortical window, with cavity and curettage obliteration using Stimulan with vancomycin and gentamicin. The treatment was successful with full recovery in 6 months, with serial radiological studies indicating no recurrence.

Another case of a 14-year-old is reviewed, presented in the study by Naald *et al.* (2019), where the origin of brodie's abscess is associated with a chronic wound treated previously by wound dressings and antibiotics. A cystic lesion with rim enhancement was seen in the metaphysis of the distal tibia X-Ray and MRI. The surgical treatment process included an insertion of gentamycin beads and primary closure in the first phase. In the second phase, performed ten days later, a removal and defect filling process with autologous bone graft was done successfully. The follow-up check-up ten days post-surgery was deemed successful with no further symptoms.

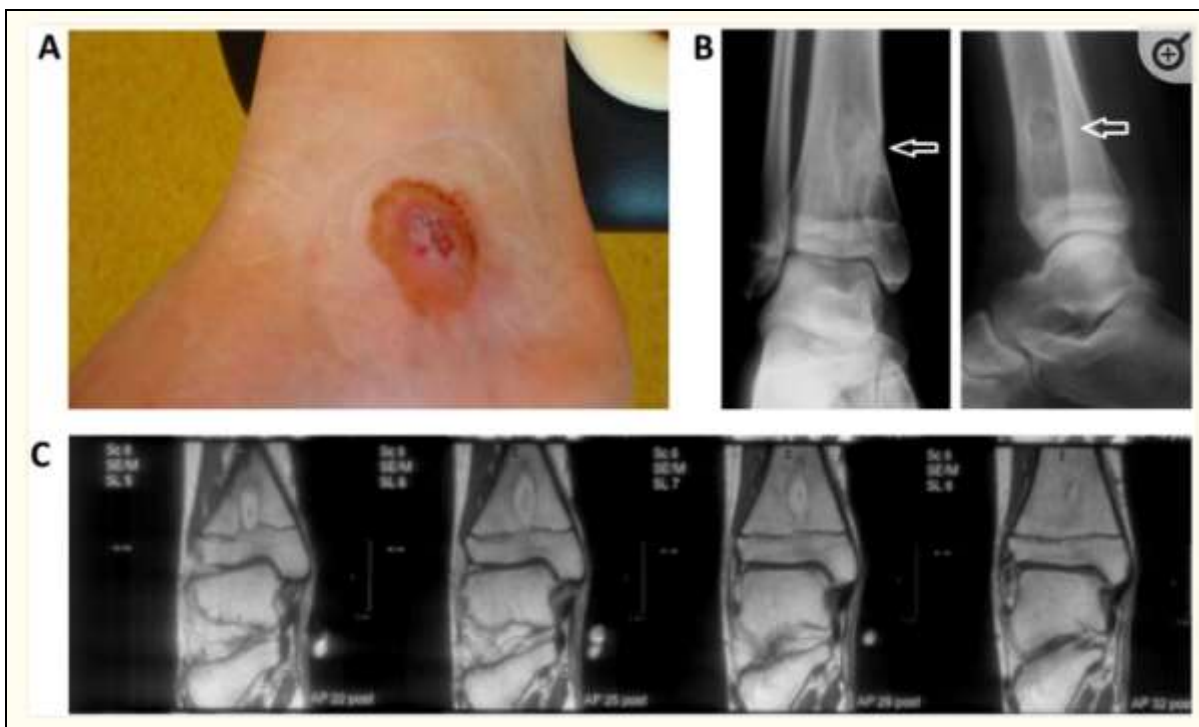


Figure 3: Case study of a 14-year-old girl diagnosed with brodie's abscess
(Source: Naald *et al.* 2019)

Another case, presented in the study by Cossio *et al.* (2019), illustrates the treatment procedure for a 12-years-old with Brodie's abscess of the tibia. It was prominent in the distal growth plate that led to the admission of the patient to the

Paediatric Department to receive a conservative treatment. The condition was first treated with antibiotic therapy which was interrupted due to intolerance manifestations. The patient was then recommended for surgical management using bioactive glass BAG-S53P4 (BonAlive, BonAlive Biomaterials Ltd., Biolinja, Finland), that ultimately led to successful results. The study shows the benefits of BAG-S53P4 in such cases, as an effective bone substitute, indicating no side effects even among children. Recovery of the patient was without any incident or recurrence as indicated in the follow-ups.

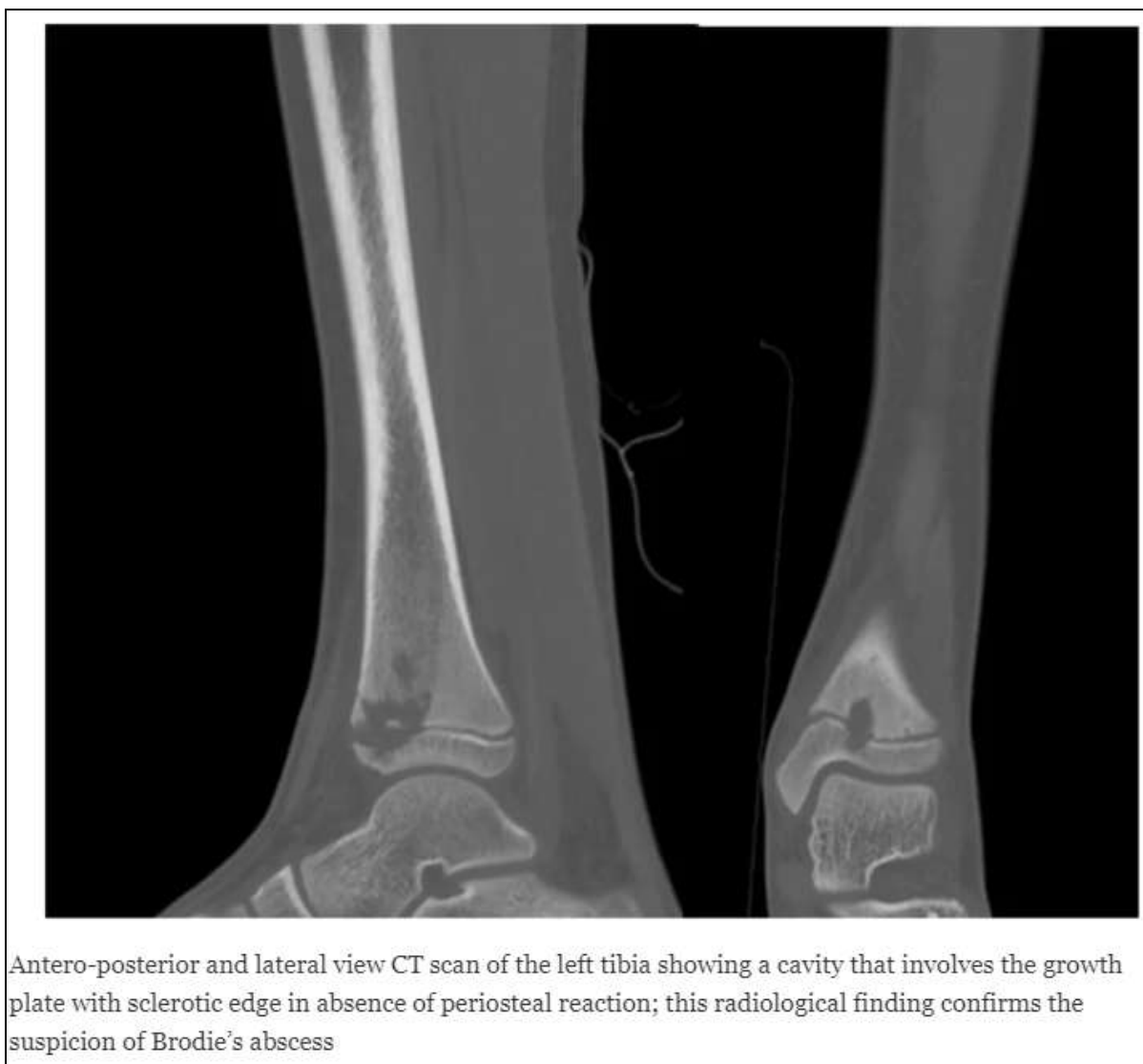

Figure 4: Case study of a 12-year-old boy diagnosed with Brodie's abscess
(Source: Cossio *et al.* 2019)

Theme 2: Benefits of surgical management procedure of brodie's abscess

Surgical management of the condition is the most popular approach for treating Brodie's abscess. The surgical removal of infections and reconstruction of the bone provides long-term and successful results for the patients. According to Khonglah *et al.* (2020), rare cases such as Brodie's abscess with a femoral head was treated successfully with arthroscopically assisted curettage of the lesion in combination with culture-directed antibiotics. In order to minimise the probabilities of recurrence, the treatment involved a lateral approach for arthroscopic curettage under fluoroscopic guidance. On the other hand, Sambri *et al.* (2021) articulated that orthopaedic imaging is essential for an accurate diagnosis process. Proper imaging using MRI and X-Ray, provides a clear direction to the surgical management process that is accepted as the procedure with the least recurrent incidents among the patients.

Theme 3: Use of radiology imaging for recurrence identification of brodie's abscess

The use of radiology for accurate imaging of brodie's abscess helps the post-operative check-up process to ensure that patients can recover fully. Use of X-Ray and MRI along with laboratory tests are standard diagnosis processes involved in brodie's abscess identification. However, as stated by Sambri *et al.* (2021), imaging-guided biopsy aids the identification of microorganisms for proper diagnosis of infectious diseases. Use of radiology for understanding the extent and severity of infectious diseases as well as monitoring the treatment process is highlighted for accurate treatment. Furthermore, Ushijima and Arai (2020) affirm that as Brodie's abscess occurrences can be diagnosed with

MRI for penumbra sign identification. Thus, the use of radiological examinations using advanced methodologies in the field of orthopaedic infection diagnosis provides sufficient support to the treatment process.

ANALYSIS

Based on the above thematic discussion, it can be stated that the Brodie's abscess can be a critical condition to diagnosis, especially in the early stages of infection due to the intermittent pain and inflammation. The infection is seen to spread a wide area before the pain is intensified. On the other hand, without proper laboratory tests and radiological diagnosis, these conditions are difficult to diagnose. The case study analysis of a 17-year-old male, 14-year-old girl and 12-year-old boy indicates the importance of surgical management with or without antibiotics. Adult people are also affected by this condition due to a history of fracture or intense injury that went undiagnosed. Based on the case study analysis, it is seen that surgical process involves lesion of the affected area to remove it and use reconstruction or filling up to avoid any scope of recurrence. BAG-S53P4 is an effective bone replacement that is used in surgery. The surgical management methods are the most successful with minimal instances of recurrence.

CONCLUSION

The study reviews case study of children patients from ages 17, 14 and 12 to indicate the surgical management practices involved in the successful treatment of Brodie's abscess. The diagnosis process involving MRI, X-Ray and other laboratory procedures are followed by surgical management for 94% of cases with 77% cases involving surgery in combination with antibiotics. Based on the above discussion, it can be concluded that the success rate of surgical management has led to the acceptance of it in treating Brodie's abscess successfully.

REFERENCE LIST

1. Chen, B.C., Kobayashi, T., O'Rourke, H. and Sekar, P., 2021. Staphylococcus aureus osteomyelitis causing Brodie's abscess of the tibia in an adult man. *BMJ Case Reports*, 14(1).
2. Cossio, A., Graci, J., Lombardo, A.S., Turati, M., Melzi, M.L., Bigoni, M. and Zatti, G., 2019. Bilateral tibial Brodie's abscess in a young patient treated with BAG-S53P4: case report. *Italian Journal of Pediatrics*, 45(1), pp.1-5.
3. Foster, C.E., Taylor, M., Schallert, E.K., Rosenfeld, S. and King, K.Y., 2019. Brodie abscess in children: a 10-year single institution retrospective review. *The Pediatric Infectious Disease Journal*, 38(2), pp.e32-e34.
4. Hoge, B.G., Patrascu Jr, J.M., Lazarescu, A.E., El Mehdi, L., Bolovan, A.D., Hoge, L.M., Ilie, A.C., Andor, B.C. and Patrascu, J.M., 2021. Rare Intercondylar Distal Femoral Brodie's Abscess in a 21-Year-Old Man Who Refused Medical Care for Three Years after Initial Symptoms. *Medicina*, 57(6), p.544.
5. Khonglah, T.G., Borgohain, B. and Ahmed, K.A., 2020. Arthroscopic assisted evacuation of a rare Brodie's abscess in the femoral head of an adolescent girl—A case report. *Indian Journal of Orthopaedics*, 6(1), pp.50-53.
6. Lowe, J., Bridwell, R.E., Matlock, A.G., Cibrario, A. and Oliver, J., 2020. A Case of Brodie's Abscess With Tibial Erosion and Extravasation Into Surrounding Soft Tissue. *Cureus*, 12(6).
7. Sambri, A., Spinnato, P., Tedeschi, S., Zamparini, E., Fiore, M., Zucchini, R., Giannini, C., Caldari, E., Crombè, A., Viale, P. and De Paolis, M., 2021. Bone and joint infections: The role of imaging in tailoring diagnosis to improve patients' care. *Journal of Personalized Medicine*, 11(12), p.1317.
8. Ushijima, T. and Arai, K., 2020. Treatment for Brodie's abscess of the radius in an adolescent: A case report. *International Journal of Surgery Case Reports*, 73, pp.134-140.
9. Van der Naald, N., Smeeing, D.P., Houwert, R.M., Hietbrink, F. and Govaert, G.A., 2019. Brodie's abscess: a systematic review of reported cases. *Journal of bone and joint infection*, 4(1), pp.33-39.