

INCIDENCE OF SUPERNUMERARY TEETH IN UCLP PATIENTS VISITING SAVEETHA DENTAL COLLEGE AND HOSPITAL

¹B. Vivek Babu, ²Arvind Sivakumar, ³A. Sumathi Felicita, ⁴Prasanna Arvind T.R.*

¹Saveetha Dental College, Saveetha Institute of Medical and Technical Sciences Saveetha University, Chennai 600077, India

²Associate Professor, Department of Orthodontics, Saveetha Dental College, Saveetha Institute of Medical and Technical Sciences Saveetha University, Chennai 600077, India

³Professor, Department of Orthodontics, Saveetha Dental College, Saveetha Institute of Medical and Technical Sciences Saveetha University Chennai, Tamil Nadu, India- 600077

⁴*Senior Lecturer, Department of Orthodontics, Saveetha Dental College, Saveetha Institute of Medical and Technical Sciences Saveetha University Chennai, Tamil Nadu, India- 600077

DOI: 10.47750/pnr.2022.13.S06.347

Abstract

Introduction: Cleft lip and palate (CLP) is the most common orofacial congenital malformation in live births. CLP can occur individually or in combination with other congenital deformities. Affected patients experience a number of dental, aesthetic, speech, hearing, and psychological complications and have a higher incidence of severe dental conditions.

Aim: The objective of the study was to determine the incidence of supernumerary teeth in unilateral cleft lip and palate patients.

Materials and Method: A cross sectional retrospective study of, study population will 28 patients visiting Saveetha Dental College and Hospital with oral Candidiasis. Their antibiotic prescription was found. The data was tabulated and analyzed. SPSS by IBM was used for data analysis

Result: From the conducted study we see that there was less incidence of supernumerary teeth in unilateral cleft lip and palate patients out of 28 of them only 2 of them had a supernumerary teeth (7.1%) and 26 of them did not have supernumerary teeth or hyperdontia (92.9%), maybe there are probability of hypodontia.

Conclusion: There is a less incidence of supernumerary teeth on unilateral cleft lip and palate patients. Since the OPG for pediatric patients cannot be taken so identification of supernumerary teeth is difficult.

KEYWORDS: Cleft Lip, Cleft Palate, Supernumerary, Unilateral.

INTRODUCTION:

Cleft lip and palate are anomalies which develop due to lack in the fusion of two processes, the lateral nasal process and the middle nasal processes with the maxillary processes. And for cleft lip, there is a lack of fusion of the lateral palatal processes among each other or the fusion with the nasal septum or the primary palate as would be in case of cleft palate (1). The overall incidence of cleft lip and palate (CLP) is approximately 1 out of 700 live births (2), which makes CLP the most common congenital malformation of the orofacial region (3). CLP is accompanied by a wide variety of dental anomalies, which also have a long-term impact on the patient's facial structure, anatomy and self-esteem (4). Dental anomalies are considered one of the contributing factors in formation of clefts (5,6).

The incidence of dental anomalies is relatively increased in children suffering with CLP as compared to the general population (7). Generally, the specific anomaly varies according to the type of CLP occurring (8,9). Previous studies have proved that both permanent and deciduous teeth can be affected, and dental anomalies are found to occur more frequently on the cleft affected side (10,11). The maxillary lateral incisors are found to be the most susceptible to

dental anomalies within the cleft area (4). According to the severity of the cleft, there are three most common dental anomalies which are missing maxillary lateral incisors, supernumerary teeth, and missing lower incisors (8).

They appear separately or are seen together and may be unilateral or sometimes bilateral. They can originate during the fourth to seventh month of intrauterine life. The lack of fusion between the mid nasal processes and maxillary processes is the possible reason for a deficiency of mesenchymal mass which can cause the disorder associated with etiological factors and can be genetic or environmental (12,13). Dental anomalies are more frequently seen in the case of children with cleft lip and / or cleft palate than in normal populations, they affect both dentitions (10,14). Hypodontia and hyperdontia may be seen among these anomalies; they are most commonly found in or near the fissured areas (15). Other additional circumstances found are changes in the position of the tooth, alterations in the tooth shape and size of the tooth, as well as delayed tooth eruption and late development of tooth (10,12,13).

Supernumerary teeth is defined as an increase in the number of teeth when compared to the normal dental formula (16–18). They are mainly observed (90- 98%) in the upper jaw, exhibiting predilection for the premaxillary area (17,19). Development of these teeth is capable of causing complications like crowding, delayed eruption, displacement or root resorption of adjacent teeth, diastema, rotations, cystic lesions, or eruption into the nasal cavity (16,20).

A study conducted by Qureshi WA et. al, compared prevalence of dental anomalies in deciduous and permanent dentition of the patients with unilateral cleft lip and palate (UCLP) and bilateral cleft lip and palate (BCLP). In which from the total of 96 collected cases, 67 of the cases were UCLP patients and 29 of them were BCLP patients were examined, and they observed that there was a high prevalence of dental anomaly in both deciduous and permanent dentitions. A total of 93% UCLP patients and 96% BCLP patients presented with a minimum of one dental anomaly, and the patient groups showed significant differences in the prevalence of single missing tooth UCLP had 39% and BCLP had 14%, in multiple missing teeth UCLP had 22% and BCLP had 54%, and for anterior malocclusion, UCLP was 15% and BCLP had 41% (21,22).

The objective of the study was to evaluate the incidence of supernumerary teeth in unilateral cleft lip and cleft palate patients.

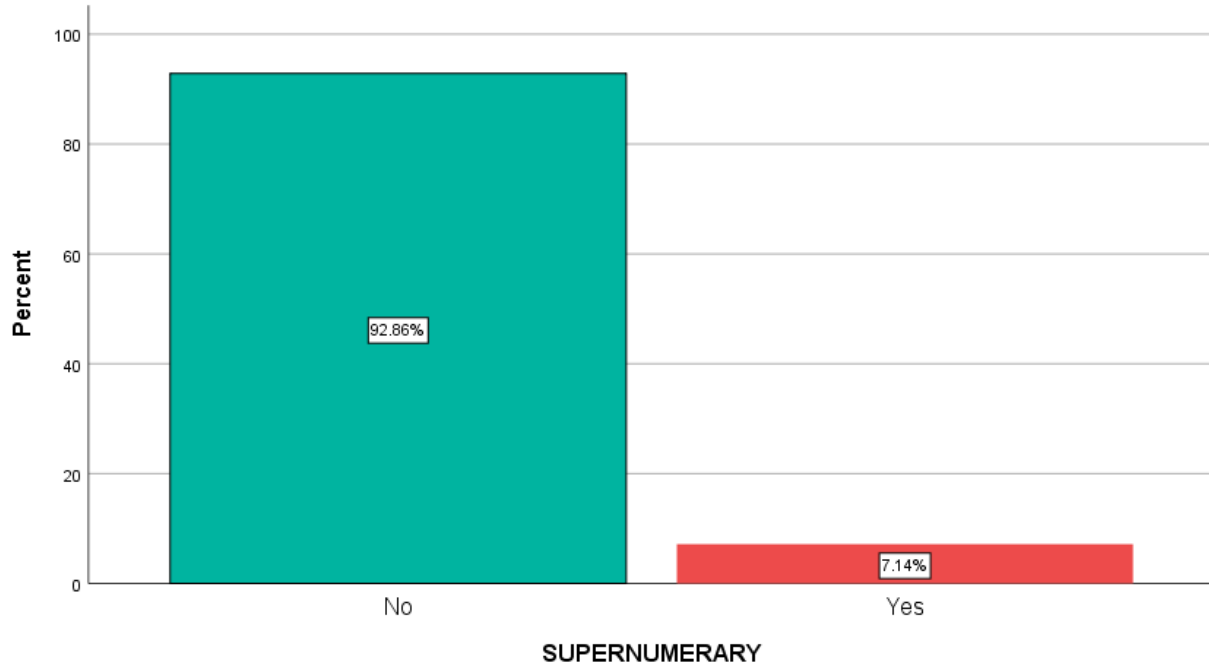
MATERIALS AND METHODS:

The study design was a prevalence study in OPD Department in a private dental institution in Chennai. The study sample was of 28 outpatients attending the OPD department with incidence of cleft lip and cleft palate. The sample was collected owing to the nature of the study design and setting, a convenience sampling method was used, and the data was collected. An online platform called DIAS was used to collect the data and the data of patients with unilateral cleft palate and cleft lip. Patients suffering from unilateral cleft lip and palate were included in the study. Syndromic patients were excluded from the study. Ethical clearance of the study was obtained prior to the study, ethical clearance was obtained from the institution ethical committee of Saveetha University. The collected radiographs were analyzed by the peer reviewers for interexaminer bias. The responses from the Google Forms were transferred into excel and were then imported to SPSS by IBM software, (version 25). Descriptive statistics were done using frequency and percentage. Inferential statistics were done using the Chi-square test. Interpretation was based on a p value less than 0.05, which was considered statistically significant. Comparisons were done between independent variables like age, gender, occupation and knowledge, attitude, practice responses by the participants.

RESULTS AND DISCUSSION:

Patients with craniofacial clefts are often affected by various dental anomalies, such as tooth agenesis, supernumerary teeth, microdontia, taurodontism, dilaceration, ectopic eruption, impacted teeth and late dental development (23). From the collected data there were a total of 28 unilaterally affected cleft lip and palate patients 26 of them did not have any supernumerary teeth (92.9%) and 2 of them had supernumerary teeth (7.1%) (22). Among the following, hypodontia was found to be the most common type of dental anomaly. In a study conducted by Liesa Heidi Möller et. al, 50% of the cleft patients analyzed, had congenital missing teeth (24). In a study conducted by Liesa Heidi Möller et. al, supernumerary teeth were observed in 33.3% of cleft individuals. Which contraindicated the results of our study (25). The same investigation revealed that in the UCLP group, right-sided clefts were statistically significantly more

often affected by supernumerary teeth than left-sided clefts, which is in accordance with the study finding of Stahl et al., Byloff-Clar and Droschl (5,26). In the study of Liesa Heidi Möller et. al, all supernumerary teeth found, were located in the maxillary anterior region. This is consistent with many other studies (24,27). Except this, only Stahl et al. also found a supernumerary lateral incisor in the lower jaw (5,28).



Graph 1: Graph showing the prevalence of supernumerary tooth out of 28 cleft lip and palate patients 26 of the did not have any supernumerary teeth (92.9%) and 2 of them had supernumerary teeth (7.1%)

A high prevalence of dental anomaly hypodontia and supernumerary teeth was found in a study, with 205 CLP patients. Hypodontia was observed in 144 patients from the total population (70.2%), and the maxillary lateral incisor showed the highest occurrence of missing teeth. The lesion was primarily located distal to the cleft (25%) when both the lateral incisors were intact (43%). Supernumerary teeth were seen in 11.7% of patients (29,30).

In another study, Al-Kharboush (31) observed that hypodontia was the most common dental anomaly to be observed, affecting 134 out of 288 cleft patients (46.5%), which is followed by microdontia (91 patients, 31.6%), ectopic eruption (30 patients, 10.4%), supernumerary teeth (26 patients, 9%), and macrodontia (7 patients, 2.4%). In a study assessing the craniofacial morphology of Japanese patients with UCLP, pushback palatoplasty was the frequently selected repair for maxillary and dentoalveolar malformation (32,33).

In a study conducted by Al Jamal GA for Jordanian subjects, they found that the prevalence incidence of dental anomaly was higher in case of CLP patients than in normal subjects. 66.7% of patients were observed with missing teeth, out of which maxillary lateral incisor was the most commonly affected tooth. 16.7% of patients were seen with supernumerary teeth, other findings included microdontia for 37% of the patients, taurodontism was seen in 70.5% of the patients, transposition or ectopic teeth was observed in 30.8% of the patients, dilacerations was seen in 19.2% of cases, and hypoplasia in 30.8% of the cases (34). This does not support our study which shows only 7.1% of them reporting with supernumerary teeth.

CONCLUSION:

From the study we conclude that the incidence of supernumerary teeth in unilateral cleft lip and cleft palate was less as compared to hypoplasia.

ACKNOWLEDGEMENT: We acknowledge Saveetha Dental college for all the help and support.

CONFLICT OF INTEREST: The authors declare no conflict of interest.

REFERENCES:

- Hansen K, Mehdinia M. Isolated Soft Tissue Cleft Lip: The Influence on the Nasal Cavity and Supernumerary Laterals [Internet]. Vol. 39, The Cleft Palate-Craniofacial Journal. 2002. p. 322–6.
- Onis M de, de Onis M, Blössner M. The World Health Organization Global Database on Child Growth and Malnutrition: methodology and applications. Vol. 32, International Journal of Epidemiology. 2003. p. 518–26.
- Al Omari F, Al-Omari IK. Cleft lip and palate in Jordan: birth prevalence rate. Cleft Palate Craniofac J. 2004 Nov;41(6):609–12.
- Cassolato SF, Ross B, Daskalogiannakis J, Noble J, Tompson B, Paedo D. Treatment of dental anomalies in children with complete unilateral cleft lip and palate at SickKids hospital, Toronto. Cleft Palate Craniofac J. 2009 Mar;46(2):166–72.
- Stahl F, Grabowski R, Wigger K. Epidemiology of Hoffmeister's "Genetically Determined Predisposition to Disturbed Development of the Dentition" in Patients with Cleft Lip and Palate [Internet]. Vol. 43, The Cleft Palate-Craniofacial Journal. 2006. p. 457.
- Felicita AS. Orthodontic extrusion of Ellis Class VIII fracture of maxillary lateral incisor - The sling shot method. Saudi Dent J. 2018 Jul;30(3):265–9.
- Shapira Y, Lubit E, Kufnec MM. Congenitally missing second premolars in cleft lip and cleft palate children. Am J Orthod Dentofacial Orthop. 1999 Apr;115(4):396–400.
- Wu T-T, Chen PKT, Lo L-J, Cheng M-C, Ko EW-C. The characteristics and distribution of dental anomalies in patients with cleft. Chang Gung Med J. 2011 May;34(3):306–14.
- Arvind P TR, Jain RK. Skeletally anchored forus fatigue resistant device for correction of Class II malocclusions-A systematic review and meta-analysis. Orthod Craniofac Res. 2021 Feb;24(1):52–61.
- Camporesi M, Baccetti T, Marinelli A, Defraia E, Franchi L. Maxillary dental anomalies in children with cleft lip and palate: a controlled study. Int J Paediatr Dent. 2010 Nov;20(6):442–50.
- Chandrasekar R, Chandrasekhar S, Sundari KKS, Ravi P. Development and validation of a formula for objective assessment of cervical vertebral bone age. Prog Orthod. 2020 Oct 12;21(1):38.
- Lourenço Ribeiro L, Teixeira Das Neves L, Costa B, Ribeiro Gomide M. Dental anomalies of the permanent lateral incisors and prevalence of hypodontia outside the cleft area in complete unilateral cleft lip and palate. Cleft Palate Craniofac J. 2003 Mar;40(2):172–5.
- de Carvalho Carrara CF, de Oliveira Lima JE, Carrara CE, Gonzalez Vono B. Chronology and sequence of eruption of the permanent teeth in patients with complete unilateral cleft lip and palate. Cleft Palate Craniofac J. 2004 Nov;41(6):642–5.
- Heliövaara A, Ranta R, Rautio J. Dental abnormalities in permanent dentition in children with submucous cleft palate. Acta Odontol Scand. 2004 Jun;62(3):129–31.
- Marya A, Venugopal A. The Use of Technology in the Management of Orthodontic Treatment-Related Pain. Pain Res Manag. 2021 Mar 9;2021:5512031.
- Ne K, Kolge NE. Orthodontic Treatment of Multiple Supernumerary & Impacted Teeth: Interdisciplinary Approach [Internet]. Vol. 4, Modern Approaches in Dentistry and Oral Health Care. 2019.
- Zhu JF, Marcushamer M, King DL, Henry RJ. Supernumerary and congenitally absent teeth: a literature review. J Clin Pediatr Dent. 1996 Winter;20(2):87–95.
- Fernández Montenegro P, Valmaseda Castellón E, Berini Aytés L, Gay Escoda C. Retrospective study of 145 supernumerary teeth. Med Oral Patol Oral Cir Bucal. 2006 Jul 1;11(4):E339–44.
- Adel S, Zaher A, El Harouni N, Venugopal A, Premjani P, Vaid N. Robotic Applications in Orthodontics: Changing the Face of Contemporary Clinical Care. Biomed Res Int. 2021 Jun 16;2021:9954615.
- Sivakumar A, Nalabothu P, Thanh HN, Antonarakis GS. A Comparison of Craniofacial Characteristics between Two Different Adult Populations with Class II Malocclusion-A Cross-Sectional Retrospective Study. Biology. 2021 May 14;10(5).
- Venugopal A, Vaid N, Jay Bowman S. Outstanding, yet redundant? After all, you may be another Choluteca Bridge! Vol. 27, Seminars in Orthodontics. 2021. p. 53–6.
- Gopalakrishnan U, Felicita AS, Mahendra L, Kanji MA, Varadarajan S, Raj AT, et al. Assessing the Potential Association Between Microbes and Corrosion of Intra-Oral Metallic Alloy-Based Dental Appliances Through a Systematic Review of the Literature. Front Bioeng Biotechnol. 2021 Mar 15;9:631103.
- AlJamal G, Hazza'a A, Rawashdeh M. Prevalence of Dental Anomalies in a Population of Cleft Lip and Palate Patients [Internet]. The Cleft Palate-Craniofacial Journal. 2010. p. 100611121139056.
- Möller LH, Pradel W, Gedrange T, Botzenhart UU. Prevalence of hypodontia and supernumerary teeth in a German cleft lip with/without palate population [Internet]. Vol. 21, BMC Oral Health. 2021.
- Marya A, Karobari MI, Selvaraj S, Adil AH, Assiry AA, Rabaan AA, et al. Risk Perception of SARS-CoV-2 Infection and Implementation of Various Protective Measures by Dentists Across Various Countries. Int J Environ Res Public Health. 2021 May 29;18(11).

26. Arumugam P, George R, Jayaseelan VP. Aberrations of m6A regulators are associated with tumorigenesis and metastasis in head and neck squamous cell carcinoma. *Arch Oral Biol.* 2021 Feb;122:105030.
27. Suzuki A, Nakano M, Yoshizaki K, Yasunaga A, Haruyama N, Takahashi I. A Longitudinal Study of the Presence of Dental Anomalies in the Primary and Permanent Dentitions of Cleft Lip and/or Palate Patients [Internet]. Vol. 54, *The Cleft Palate–Craniofacial Journal*. 2017. p. 309–20.
28. Joseph B, Prasanth CS. Is photodynamic therapy a viable antiviral weapon against COVID-19 in dentistry? *Oral Surg Oral Med Oral Pathol Oral Radiol.* 2021 Jul;132(1):118–9.
29. Tereza GPG, Carrara CF de C, Costa B. Tooth abnormalities of number and position in the permanent dentition of patients with complete bilateral cleft lip and palate. *Cleft Palate Craniofac J.* 2010 May;47(3):247–52.
30. Duraisamy R, Krishnan CS, Ramasubramanian H, Sampathkumar J, Mariappan S, Sivaprakasam AN. Compatibility of Nonoriginal Abutments with Implants. Vol. 28, *Implant Dentistry*. 2019. p. 289–95.
31. Gothandam K, Ganesan VS, Ayyasamy T, Ramalingam S. Antioxidant potential of theaflavin ameliorates the activities of key enzymes of glucose metabolism in high fat diet and streptozotocin - induced diabetic rats. *Redox Rep.* 2019 Dec;24(1):41–50.
32. Alam MK, Iida J, Sato Y, Kajii TS. Postnatal treatment factors affecting craniofacial morphology of unilateral cleft lip and palate (UCLP) patients in a Japanese population. Vol. 51, *British Journal of Oral and Maxillofacial Surgery*. 2013. p. e205–10.
33. Ezhilarasan D. Hepatotoxic potentials of methotrexate: Understanding the possible toxicological molecular mechanisms. *Toxicology.* 2021 Jun 30;458:152840.
34. Preethi KA, Auxzilia Preethi K, Sekar D. Dietary microRNAs: Current status and perspective in food science [Internet]. Vol. 45, *Journal of Food Biochemistry*. 2021.