

Treatment of Unstable Thoracolumbar Burst Fractures with Single-Stage Posterior Subtotal Corpectomy and Circumferential Reconstruction: A Prospective Observational Study in Jammu

Dr Naresh Rana¹, Dr Gagandeep Singh², Dr Rishabh Gupta^{3*}

¹Senior resident Department of Orthopaedic GMC Rajouri J and K, Email - naresh8rana@gmail.com

²Senior resident Department of Orthopaedic GMC Kathua J and K, Email - drgagandeep1717@gmail.com

³Assistant Professor department of Orthopaedic GMC kathua J and K, Email dr.rishabh19@gmail.com

*Corresponding Author: Dr Rishabh Gupta

³Assistant Professor department of Orthopaedic GMC kathua J and K, Email dr.rishabh19@gmail.com

DOI:10.47750/pnr.2022.13.S05.112

Abstract

Background: The term thoracolumbar fracture essentially refers to the fact that the bone is broken in the thoracic (middle) or lumbar (lower back) region of the spine. The present prospective study has been objectively conducted to evaluate the clinical and radiological outcome of single stage subtotal corpectomy and circumferential reconstruction of unstable thoracolumbar burst fracture.

Methods: This prospective study was carried out in GMC Jammu from October 2017 to December 2018. A total 20 patients with acute traumatic unstable burst fractures at thoracolumbar junctions were included in this prospective study who qualified the defined inclusion criteria.

Results: The mean sagittal plane kyphosis pre operatively was 24.84 ± 5.22^0 which reduced to 13.15 ± 5.3^0 at post-operative day 1. At final follow up, sagittal plane kyphosis was 15.10 ± 5.65^0 . The mean Anterior Body Compression was $33.64 \pm 6.79\%$ which decreased to 22.3 % at post-operative day 1. At final follow up, mean ABC was $24.26 \pm 4.95\%$. VAS score reduced from mean value of 6.85 to 2.2 at final follow up which is slightly less compared to what others reported.

Conclusion: The present study revealed that indirect decompression and posterior subtotal corpectomy and circumferential reconstruction fulfill all the aims of surgical treatment of fractures and fracture dislocations of thoracolumbar spine. We recommend longer follow up to assess the degree of correction of kyphosis and re-collapse and neural recovery with single stage posterior subtotal corpectomy and circumferential reconstruction

Keywords: Burst fracture, posterior subtotal corpectomy, circumferential reconstruction.

INTRODUCTION

In this modern era of increasing mechanization, high speed automobiles and increasing industrialization, the occurrence of thoracolumbar fractures and dislocations has increased substantially. The term thoracolumbar fracture essentially refers to the fact that the bone is broken in the thoracic (middle) or lumbar (lower back) region of the spine. With majority of cases occurring in males, the commonest age group is (15-40) years. Such kind of travesty arise mostly due to motor vehicle accidents, fall from height, diving accidents, winter sports accidents, airplane crashes, industrial accidents, suicidal attempts and less frequently due to direct violence. As per the documented literature; the proportion of contributing factors towards thoracic fractures are: motor vehicle accidents (45%), falls (20%), sport injuries (15%), act of violence (15%) and miscellaneous (5%).¹ Thoracic and lumbar injuries account for 90% of all spinal injuries. In fact, the majority of thoracic and lumbar spine injuries occur within the region between T11 and L1 commonly referred to as the thoracolumbar junction. A burst fracture of the thoracolumbar junction is a very common condition of the anterior and middle portions of the spinal column, in which vertebral body fragments shift into the spinal canal. These fractures can cause neurologic complications and kyphotic deformity. The management of unstable burst fractures warrants surgery to resolve pain, to address neurologic deficits, and to stabilize the spine.² The commonly employed surgical modalities include posterior approach, anterior approach, and combined anterior-posterior approach.³⁻⁶ Each technique has its advantages and disadvantages, as such, the optimal approach is still debatable.^{6, 7} Then the optimal approach remains controversial. Some reports have described posterior reconstruction using pedicle screws, aiming to reposition canal compromising fragments by ligamentotaxis or remodeling of the canal. Posterior surgeries of this type for thoracolumbar burst fractures have reported satisfactory results in fractures involving mild instability. For highly unstable thoracolumbar burst fractures, anterior decompression and reconstruction has been developed with a variety of

anterior implant systems, which have achieved satisfactory results. On the basis of current biochemical data, combined anterior-posterior modality can offer the highly stable biochemical stabilization of three columns for unstable thoracolumbar burst fracture.⁸⁻¹⁰ Albeit, the extensive surgical measures, including the anterior approach may increase the associated morbidity, specifically to traumatized thoracic cavities. Theoretically three column stabilization through a posterior approach excludes the possibility of these risks, shortcomings, and facilitates rehabilitation. Similar kind of experience was reported by Ayber et al recently.¹¹ The present prospective study has been objectively conducted to evaluate the clinical and radiological outcome of single stage subtotal corpectomy and circumferential reconstruction of unstable thoracolumbar burst fracture.

MATERIAL AND METHODS

This Study was carried out in GMC Jammu from October 2017 to December 2018. 20 patients with acute traumatic unstable burst fractures at thoracolumbar junctions were included in this prospective study. All these patients were treated with single-stage posterior subtotal corpectomy and circumferential reconstruction. This study was conducted with approval from the ethics committee of our hospital. Patients with both Sexes aging 18-65 years having traumatic burst fracture of thoraco lumbar junction with TLICS severity score ≥ 5 . However, patients having extremes of age, associated with cervical spine injury, spine deformity or previous fracture or spine surgery, multilevel fracture, compression fracture with intact neurological function and pathological fracture were excluded from the study

Pre OP Assessment:

All patients admitted for surgical intervention were assessed pre-operatively for: complete haemogram, renal function tests/liver function tests, blood sugar levels (FBS and PP), blood grouping, neurological status as per Frankel grading, pain-back pain using Visual Analog Scale (VAS) and imaging

Technique

Pre op. antibiotic (inj. cefuroxime 1.5gm) was given 30 minutes before surgery. Following endotracheal intubation, patients were placed in a prone position on a radiolucent operation table. A posterior midline incision is made spreading from two or three levels above the fracture site to two or three levels below it, after marking the fractured vertebra under C arm, and subperiosteal dissection performed from the spinous process to the tip of the transverse process at all predetermined levels. With C-arm guidance, pedicle screws were inserted two level below and above the fracture site or one level above and one level below including the fractured vertebra on one side or three levels in patients with severe osteoporosis or patients with translational or rotational injuries combined with posterior ligamentous complex disruption.

The single-stage posterior subtotal corpectomy was then performed. Posterior elements of the fractured level were removed. With Dura mater on sight, both lamina of the fractured vertebra were completely removed. Facet joint of more severe injured side was then removed to reveal nerve root and dorsal root ganglions. Epidural veins and radicular veins were cauterized with bipolar forceps to avoid massive bleeding. These steps decompressed the posterior aspect of the thecal sac. Once this done, the thecal sac was easily retracted to provide better exposure of the posterior portion of the fractured vertebral body and the intervertebral discs. The thecal sac and nerve root were then gently retracted and protected with a nerve retractor. A subtotal corpectomy of the fractured vertebral body was performed with an osteotome and curette leaving lateral and anterior vertebral body wall intact. The posterior wall, superior and inferior end plates of the fractured vertebral body were then broken down using a curved curette and the pieces removed with pituitary. The discectomies were performed to provide sufficient space for cage.

During this process, under fluoroscopy, a probe was used to check the depth of bone resection. The appropriate size of cage was confirmed and the cage pinned to the cage holder. The interior of the device was packed with resected local bone and allograft bone. By gently distracting the thecal sac and nerve root, we inserted a cage into the corpectomy cavity. Using an impactor, the cage was shifted as necessary so that it is positioned exactly at the midline and in the anterior of the corpectomy cavity. Cage positioning was monitored during all stages of implantation using postero-anterior and lateral fluoroscopy. Once proper placement was confirmed, additional bone graft tissue was packed around the cage and postero-lateral sides of the column for the circumferential fusion. Wound closure done in layers and antiseptic dressing applied. Post operatively antibiotic cover was given for a week. The patients were allowed to turn horizontally on second post-operative day.

After suture removal Taylor brace was applied and the assisted mobilization of the patient was started. Regular physiotherapy was continued and check radiography were taken to confirm stability, restoration of vertebral height and kyphotic angle. Weekly neurological charting and general physical examination of all the patient was done for bed sores, upper respiratory tract infections, urinary tract infections and associated complications.

Psychosocial counseling of patients was done throughout the treatment and vocational guidance was given at the time of discharge depending upon the patient's skill and ability. The follow up examination was done for an average period of 1 year, with patient reporting for assessment at 3 monthly intervals. The final results were analyzed on basis of following criteria: neurological recovery as per Frankel's Grading, spine stability as per Kyphotic angle by Cobb's method and vertebral body height and post op pain as per Visual Analogy Scale scoring.

Results and observations

In this section we will present the results of the study:

In the present study, out of 20 studied patients, (70%) were males and only (30%) were female. The average age of patients was observed as 31.9 years, with majority of them belonging to the age interval of (25-30) years accounting for (30%) of cases.

Table 1: Interval between Trauma and Fixation

DURATION	NUMBER	PERCENTAGE (%)
Less than 72 hours	0	0
72 hours -1 week	07	35
1 week-2 week	13	65

We observe that no patient was operated upon within 72 hours of injury whereas majority (65%) of the patients were operated between 1st and 2nd week of injury. The mean duration between trauma and surgery was 10.55 days.

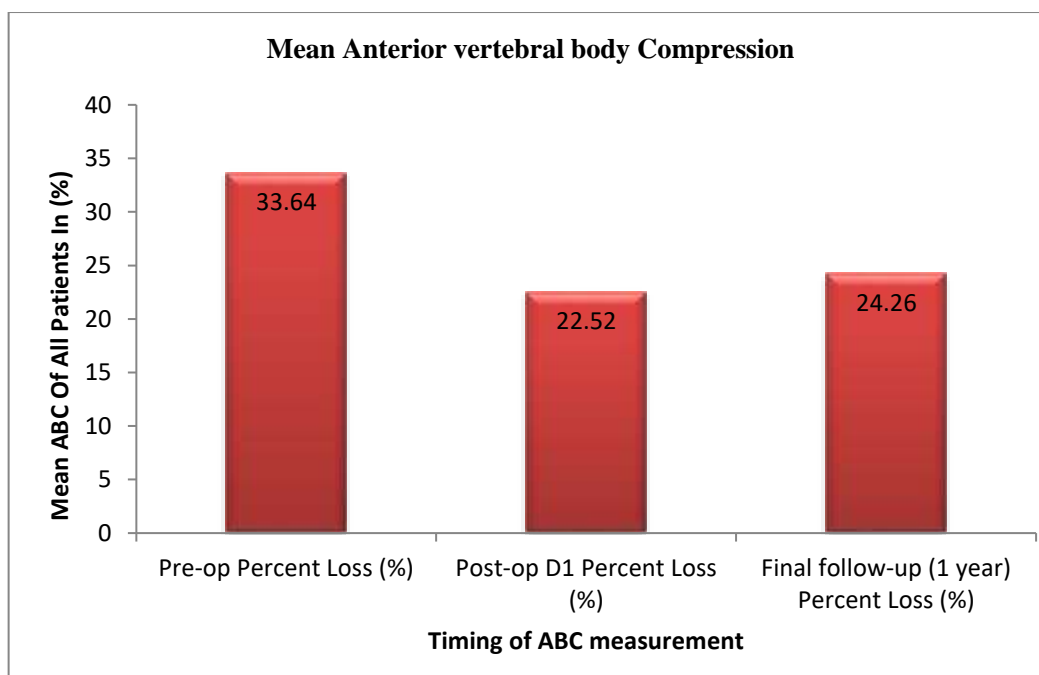
Table 2: Showing mean sagittal plane kyphosis (SPK)

TIME	PRE-OP	POST-OP D1	FINAL FOLLOW-UP (1 YEAR)
Mean Kyphosis	24.84 ± 5.22 ⁰	13.15±5.3 ⁰	15.10±5.65 ⁰

The mean sagittal plane kyphosis pre operatively was 24.84±5.22⁰ which reduced to 13.15±5.3⁰ at post-operative day 1. At final follow up, sagittal plane kyphosis was 15.10±5.65⁰.

Table 3: Showing mean anterior vertebral body compression

TIME	PRE-OP ABC (%)	POST-OP D1 ABC (%)	FINAL FOLLOW-UP (1 Year) ABC (%)
Mean Compression	33.64±6.79	22.52±5.16	24.26±4.95

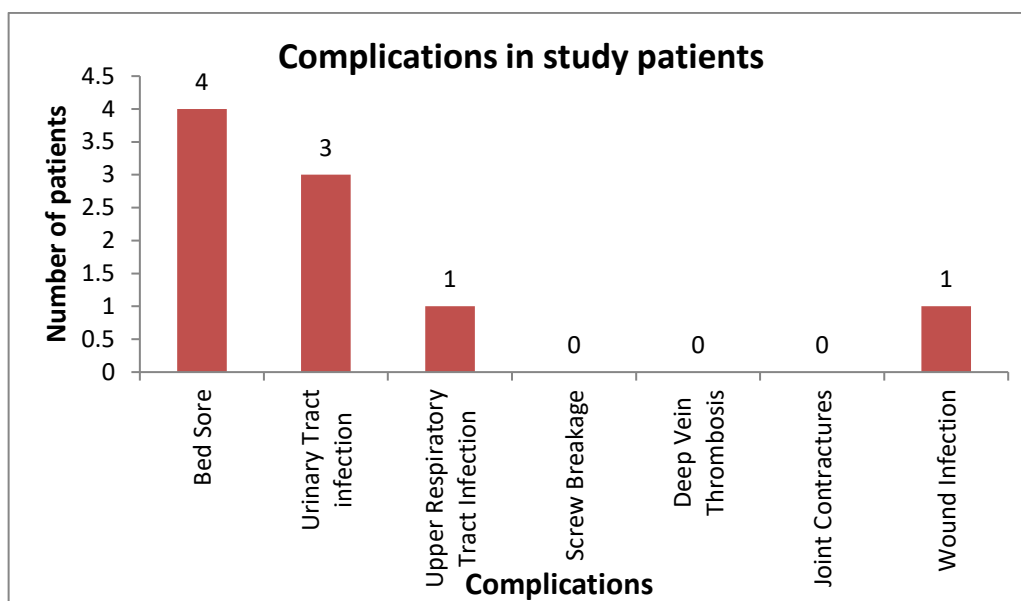


The mean Anterior Body Compression was 33.64±6.79% which decreased to 22.3 % at post-operative day 1. At final follow up, mean ABC was 24.26±4.95%.

Table 4: Showing neurological status among studied patients

Status	Pre-op		Post-op 6wks		Post-op 6mths		Post-op Final follow-up 1 Year	
	Freq.	%	Freq.	%	Freq.	%	Freq.	%
A	08	40	08	40	08	40	08	35
B	07	45	07	35	06	30	04	15
C	05	15	04	20	03	15	04	25
D	0	0	01	5	03	15	04	25
E	0	0	0	0	0	0	0	0
Total	20	100	20	100	20	100	20	100

Preoperatively 8(40%) patients had complete injury (grade A), 7(35%) patients had grade B, 5(25%) patients had grade C, and 0 (0%) patients had grade D neurological status while 0 (0%) patient had no neurological impairment. Post operatively at final follow up, 20% patient has grade D neurological status.



DISCUSSION

Traumatic thoracolumbar junction injuries are one of the most frequent sites of vertebral column injuries in adults. In unstable fracture anterior and middle columns fail in compression and the posterior osteoligamentous column is significantly disrupted. The goal of treatment of unstable thoracolumbar burst fractures is optimizing neural decompression while providing stable internal fixation over the least number of spinal segments. In the present study, we evaluated the clinical and radiological findings of single stage posterior subtotal corpectomy and circumferential reconstruction for unstable thoracolumbar burst fracture. We observed that no patient was operated upon within 72 hours of injury whereas majority of the patients (65%) were operated between 1st and 2nd week of injury. Mean duration between trauma and surgery was 10.55 days. In a likewise study, Hamzaoglu et al operated their patients with a mean of 3.24 days while as Lee et al had a mean trauma to fixation interval of 2.78 days (range 0 – 7 days).^{12,13} It is recommended that surgery should be performed as early as possible as the condition of the patient allows. In the present study, the mean sagittal plane kyphosis was 24.84 ± 5.22^0 pre-operatively which reduced to 13.15 ± 5.3^0 post-operatively. At final follow up, mean sagittal plane kyphosis was 15.10 ± 5.65^0 . Our study showed correction of approximately 10^0 in sagittal plane kyphosis. Sasani et al. demonstrated correction of approximately 5^0 in sagittal plane kyphosis. Shin et al. demonstrated correction of approximately 7^0 in sagittal plane kyphosis in their study.¹⁵ Suzuki T et al observed local kyphosis improved from 15.7^0 pre-operatively to -4.7^0 at final follow. Total kyphosis correction of about 20.4^0 was achieved.¹⁶ We observe that the mean anterior body compression was $33.64 \pm 6.79\%$ preoperatively which decreased to $22.52 \pm 5.16\%$ at post-operative day 1. At final follow up mean ABC was $24.26 \pm 4.95\%$. Contemporary to the literature, Shin et al also demonstrated 17% increase in the vertebral height obtained after surgery which was comparable to our study.¹⁵ The results obtained by Bernucci et al of near anatomical restoration must be reviewed with the fact that they were able to operate the patients with mean trauma fixation interval of 15 hours as compared to 10.55 days in our study.¹⁷ We assessed the neurological status among studied patients and found preoperatively 8(40%) patients had complete injury (grade A), 7(35%) patients had grade B, 5(25%) patients had grade C, and 0 (0%) patients had grade D neurological status while 0 (0%) patient had no neurological impairment. Post operatively at final follow up, 25% patient had grade D neurological status. All the patients had neurodeficit and were taken for surgery. 5(25%) patients showed neuro recovery by one or more Frenkel's grade. Only 4 (20%) patients had useful recovery at final follow up i.e ASIA D grade. 8(40%) patients had Pre op Frenkel's grade A and remained same at final follow up. 7(35 %) patients had Pre op grade B, of which 4 remained as B, 1 changed to C and 2 changed to D. In study of Suzuki T et al. 42.85% patients had Frenkel's grade C, 42.85% patients had Frenkel's grade D and 14.28% patients had Frenkel's grade E pre-operatively, while at final follow up 28.57% patients had Frenkel's grade D and 71.42% patients had Frenkel's grade E.¹⁶ In the study of Sasani et al. 7.14% patients had Frenkel's grade D, 21.42% patients had Frenkel's grade C, 14.28% patients had Frenkel's grade D and 57.14% patients had Frenkel's grade E at the time admission while at final follow up 7.14% patients had Frenkel's grade B, 7.14% patients had Frenkel's grade C, 21.42% patients had Frenkel's grade D and 64.28% patients had Frenkel's grade E.¹⁴ In our study VAS score reduced from mean value of 6.85 to 2.2 at final follow up which is slightly less compared to what others reported.^{13, 18, 19} The postoperative significant decrease in VAS essentially infers that the treatment is effectively resolving the severity of pain among operated patients as desired.

CONCLUSION

The present study revealed that indirect decompression and posterior subtotal corpectomy and circumferential reconstruction fulfill all the aims of surgical treatment of fractures and fracture dislocations of thoracolumbar spine. This can furnish a near anatomical restoration of vertebral column and spinal canal and is an effective method to adequately decompress the neural elements and provide the best milieu for neurological recovery. However, our study is by no means suggesting that the single-stage posterior subtotal corpectomy and circumferential reconstruction should be the preferred treatment over other techniques; it is merely one of the surgical options. We recommend longer follow up to assess the degree of correction of kyphosis and re-collapse and neural recovery with single stage posterior subtotal corpectomy and circumferential reconstruction.

REFERENCES

1. Mirza SK, Mirza AJ, Chapman JR, Anderson PA. Classifications of thoracic and lumbar fractures: rationale and supporting data. *JAAOS-Journal of the American Academy of Orthopaedic Surgeons*. 2002 Sep 1;10(5):364-77.
2. Gertzbein SD, Macmichael D, Tile M. Harrington instrumentation as a method of fixation in fracture of spine. *J Bone Joint Surg Br*. 1982;64:526-9.
3. Alanay A, Acaroglu E, Yazici M, Oznur A, Surat A : Short-segment pedicle instrumentation of thoracolumbar burst fractures : does transpedicular intracorporeal grafting prevent early failure? *Spine (Phila Pa 1976)* 26 : 213-217, 2001
4. Alvine GF, Swain JM, Asher MA, Burton DC : Treatment of thoracolumbar burst fractures with variable screw placement or Isola instrumentation and arthrodesis : case series and literature review. *J Spinal Disord Tech* 17 : 251-264, 2004
5. Chen HH, Wang WK, Li KC, Chen TH : Biomechanical effects of the body augments for reconstruction of the vertebral body. *Spine (Phila Pa 1976)* 29 : E382-E387, 2004
6. Kaneda K, Taneichi H, Abumi K, Hashimoto T, Satoh S, Fujiya M : Anterior decompression and stabilization with the Kaneda device for thoracolumbar burst fractures associated with neurological deficits. *J Bone Joint Surg Am* 79 : 69-83, 1997
7. Gurwitz GS, Dawson JM, McNamara MJ, Federspiel CF, Spengler DM : Biomechanical analysis of three surgical approaches for lumbar burst fractures using short-segment instrumentation. *Spine (Phila Pa 1976)* 18 : 977-982, 1993
8. Acosta FL Jr, Aryan HE, Taylor WR, Ames CP : Kyphoplasty-augmented short-segment pedicle screw fixation of traumatic lumbar burst fractures : initial clinical experience and literature review. *Neurosurg Focus* 18 : e9, 2005
9. Kaya RA, Aydin Y : Modified transpedicular approach for the surgical treatment of severe thoracolumbar or lumbar burst fractures. *Spine J* 4 : 208-217, 2004
10. Wood KB, Bohn D, Mehdorad A : Anterior versus posterior treatment of stable thoracolumbar burst fractures without neurologic deficit : a prospective, randomized study. *J Spinal Disord Tech* 18 Suppl : S15-S23, 2005
11. Ayberk G, Ozveren MF, Altundal N, Tosun H, Seckin Z, Kilicarslan K, et al. : Three column stabilization through posterior approach alone : transpedicular placement of distractable cage with transpedicular screw fixation. *Neurol Med Chir (Tokyo)* 48 : 8-14; discussion 14, 2008
12. Hamzaoglu A, Elsadig M, Karadereler S, Mutlu A, Akman YE, Ozturk H, Aslantürk O, Sanlı T, Kahraman S, Enercan M. Single-Stage Posterior Vertebral Column Resection With Circumferential Reconstruction for Thoracic/Thoracolumbar Burst Fractures With or Without Neurological Deficit: Clinical Neurological and Radiological Outcomes. *Global Spine Journal*. 2020 Oct 14:2192568220964453.
13. Jo DJ, Kim KT, Kim SM, Lee SH, Cho MG, Seo EM. Single-Stage Posterior Subtotal Corpectomy and Circumferential Reconstruction for the Treatment of Unstable Thoracolumbar Burst Fractures. *J Korean Neurosurg Soc*. 2016 Mar;59(2):122-8. doi: 10.3340/jkns.2016.59.2.122. Epub 2016 Feb 29. PMID: 26962417; PMCID: PMC4783477.
14. Sasani M, Ozer AF : Single-stage posterior corpectomy and expandable cage placement for treatment of thoracic or lumbar burst fractures. *Spine (Phila Pa 1976)* 34 : E33-E40, 2009
15. Shin EK, Kim CH, Chung CK, et al. Sagittal imbalance in patients with lumbar spinal stenosis and outcomes after simple decompression surgery. *Spine J* 2017;17(2):175-182
16. Suzuki T, Abe E, Miyakoshi N et al. Anterior Decompression and Shortening Reconstruction with a Titanium Mesh Cage through a Posterior Approach Alone for the Treatment of Lumbar Burst Fractures. *Asian Spine J*. 2012 Jun;6(2):123-30.
17. Bernucci C, Maiello M, Silvestro C, Francaviglia N, Bragazzi R, Pau A, Viale GL. Delayed worsening of the surgical correction of angular and axial deformity consequent to burst fractures of the thoracolumbar or lumbar spine. *Surgical neurology*. 1994 Jul 1;42(1):23-5.
18. Sin EG, Kim HW, Lee CY, Ha HG, Jung CK. Results of Combined 360-Degree Fusion versus Posterior Fixation Alone for Thoracolumbar Burst Fractures. *Korean J Neurotrauma*. 2013 Oct;9(2):52-56. <https://doi.org/10.13004/kjnt.2013.9.2.52>
19. Bagga RS, Goregaonkar AB, Dahapute AA, Muni SR, Gokhale S, Manghwani J. Functional and radiological outcomes of thoracolumbar traumatic spine fractures managed conservatively according to Thoracolumbar Injury Severity Score. *J Craniovertebr Junction Spine*. 2017 Oct-Dec;8(4):369-373. doi: 10.4103/jcvjs.JCVJS_93_17. PMID: 29403252; PMCID: PMC5763597.