

CHANGES IN ORAL CAVITY OF CHILDREN WITH DIABETES

Makhsুমova Sayora Sanjarovna¹, Makhsুমova Iroda Shavkatovna², Mukhamedova Malika Sagdullaevna³

^{1,2,3}Ph.D., associate professor at the Tashkent State Institute of Stomatology

Email: Irodamahsumova@gmail.com

DOI: 10.47750/pnr.2022.13.S06.309

Abstract

Diabetes mellitus in childhood is a serious problem. In this regard, this disease is among the first priority national health programs in all countries of the world.

Pathological processes that occur in the pancreas in type 1 diabetes mellitus in children are to some extent reflected in all tissues of the body, but the earliest and quite clearly expressed disorders are determined on the mucous membrane of the oral cavity and the dorsal surface of the tongue.

Keywords: Diabetes mellitus, pancreas, mucous membrane of the oral cavity.

INTRODUCTION

Diabetes mellitus is a chronic disease based on complex neuroendocrine mechanisms leading to morphofunctional changes in many organs and systems of the human body.

- According to the literature data, the level of oral hygiene in people with diabetes mellitus is worse than in patients without this disease.
- In almost 90-100% of cases, these individuals develop periodontal inflammation of varying severity.
- Changes in metabolism and trophic disorders in tissues in diabetes mellitus significantly affect the state of the oral cavity. Hyperglycemia, hyposalivation and other changes lead to a deterioration in the state of oral hygiene, the formation of non-mineralized and mineralized dental deposits, and contribute to the onset and progression of periodontal inflammatory reactions.

The increase in the incidence of type 1 diabetes mellitus among children and the often latent course of this pathology at the initial stage of development are the basis for a further comprehensive study of the state of the oral cavity and the development of criteria for early non-invasive diagnosis of this endocrine pathology.

Diabetes mellitus is a chronic disease based on complex neuroendocrine mechanisms leading to morphofunctional changes in many organs and systems of the human body [1, 2]. Type I (insulin-dependent) diabetes mellitus is less common [3, 4]. It occurs as a result of a decrease in insulin secretion. beta cells of the islets of Langerhans of the pancreas [5]. Severe forms of diabetes mellitus I type are more likely to affect children and young people (juvenile diabetes) [6, 7]. Among the numerous complications of diabetes mellitus are more often considered diabetic macro- and microangiopathies, neuropathies, nephropathy, visual impairment, in the pathogenesis which are disorders of carbohydrate, fat, protein and other types of metabolism [8, 9]. Dental manifestations of this disease are noted in the vast majority of patients, and some dentists indicate 100% damage to organs and tissues of the oral cavity [1, 8]. Dental manifestations of diabetes can be a direct consequence of the weakening or loss of specific effects of insulin, as well as various metabolic disorders [5]. Important emphasize that inflammatory processes in children, diabetic patients usually have with frequent exacerbations. Parallelism in the course of periodontal pathology is noted in the literature. So, when the current worsens underlying disease aggravated by inflammatory processes in periodontal tissues [1, 10]. The compensated course of diabetes mellitus has a positive effect on the duration of remission of the inflammatory process in the periodontium [3, 12]. In the same time insufficient attention is paid to improving the dental health of children

with diabetes mellitus, as well as treatment and prophylactic measures to preserve teeth and prevention of exacerbations of the inflammatory process in periodontal tissues.

Type 1 diabetes in childhood is a serious problem, in this regard, this disease

is among the first priority national health programs in all countries of the world. According to modern concepts, the level of dental health in type 1 diabetes,

determined by the resistance of hard tissues of teeth and periodontium, the constancy of the physicochemical composition of the oral fluid, the protective function of the oral mucosa, and also the state of local immunity, objectively reflects the intensity of neuroregulatory, metabolic, immunological, homeostatic and hemodynamic disorders occurring in macroorganism. To date, there has not been a comprehensive assessment of the state of the oral cavity in children with type 1 diabetes in depending on the duration of the disease and the degree of compensation.

The high prevalence of type 1 diabetes among children, the complexity of its early detection make it very relevant solution of problems associated with the early diagnosis of this pathology.

Due to the fact that the functions of the salivary glands are closely related to the processes in the whole organism, the use of oral fluid as a biological object for non-invasive diagnosis of type 1 diabetes in children is promising.

Despite numerous studies, there is no holistic view of the state of local immunity of the oral cavity in children with type 1 diabetes, depending on the stage of the disease and child's age.

Attention is drawn to the fact that the issue of violations of acid-base balance in the cavity too little attention is paid to the mouth, although its indicators can be informative and necessary for practical dentistry.

Currently, there is not enough information about the relationship between biochemical changes in blood serum and oral fluid in type 1 diabetes in children, and have not been parallels between these indicators. There are no diagnostic criteria for determining type 1 diabetes in children according to their dental status.

The increase in the incidence of type 1 diabetes among children and the often latent course of this pathology at the initial stages of development are the basis for further comprehensive study of the state of the cavity mouth and development of criteria for early non-invasive diagnosis of this endocrine pathology.

Diabetes mellitus in childhood is a lifelong autoimmune disease which practically all organs and systems of the body are involved in the pathological process [2, 7].

In inflammatory diseases of the stomach, intestines, gallbladder and pancreas changes in the oral cavity are of a functional nature (decrease in taste sensitivity, dry mouth), so there is catarrhal inflammation of the gums, oral mucosa, and also inflammatory-destructive processes in the periodontium.

It is known that changes in the oral cavity often outstrip the appearance of the main clinical signs of the disease, this explains the primary treatment of patients in dental institutions.

In this regard, the dentist is responsible for diagnosing the early manifestations of common diseases, in elucidating the etiology and pathogenesis of changes in the oral mucosa for development of evidence-based therapy.

At present, despite numerous studies, type 1 diabetes in children age is characterized by a high prevalence, a continuing trend towards an increase in the number patients, chronic course, high disability of patients in the most active period of life and the need to create a system of specialized care.

It is well known that the functions of the salivary glands are most closely related to the processes in the whole body, so the use of oral fluid as a biological object for the non-invasive diagnosis of type 1 diabetes in children is promising.

At present, the problem of using oral fluid to diagnose type 1 diabetes mellitus in children has not been fully studied and is of interest to both researchers and practitioners, especially pediatricians.

Despite numerous studies, there is no holistic view of the state of local oral immunity in children with type 1 diabetes, depending on the stage of the disease and the age of the child.

Attention is drawn to the fact that too little attention is paid to the issue of acid-base balance disorders in the oral cavity, although its indicators can be informative and necessary for practical dentistry.

Even at present, there is not enough information about the relationship between biochemical changes in blood serum and oral fluid in type 1 diabetes mellitus in children [8-13] .

Thus, an in-depth study of the dental status and identification of important diagnostic criteria in the oral cavity in type 1 diabetes mellitus in children can be of no small importance for the timely establishment of a general diagnosis and referral of a child to an endocrinologist.

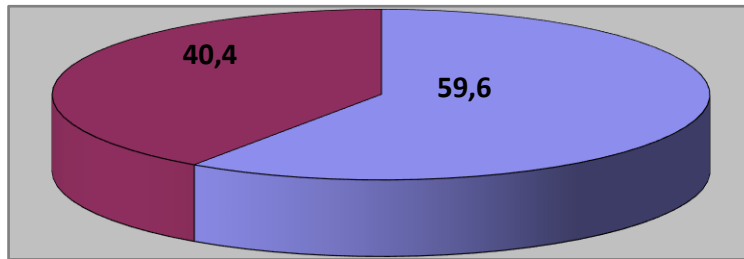
Purpose: to assess the state of periodontal and oral hygiene in children with type 1 diabetes

Materials and methods:

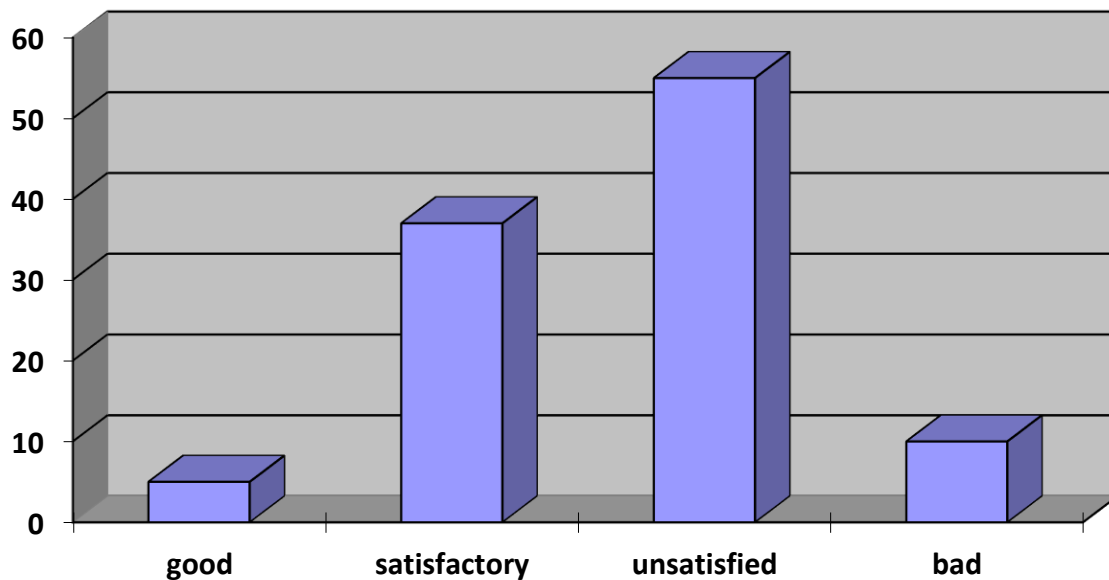
- The study was performed at a clinical dental clinic.
- A dental examination was carried out on 52 children aged 6 to 17 with type 1 diabetes mellitus.
- Examination of the oral cavity was carried out using a dental probe and a mirror, the results were recorded in a specially designed chart of the patient's dental examination. A survey of patients and/or their parents was also conducted, during which it was noted how many times a day children brush their teeth.
- The state of oral hygiene was assessed using the hygiene index (Green J.C., Vermillion J.R., 1964)
- Assessment of periodontal condition was carried out using the gum bleeding index

Research results

- Based on the survey, it was revealed that 40.4% of examined children with diabetes mellitus brush their teeth once a day or less, and 59.6% brush their teeth twice a day or more.

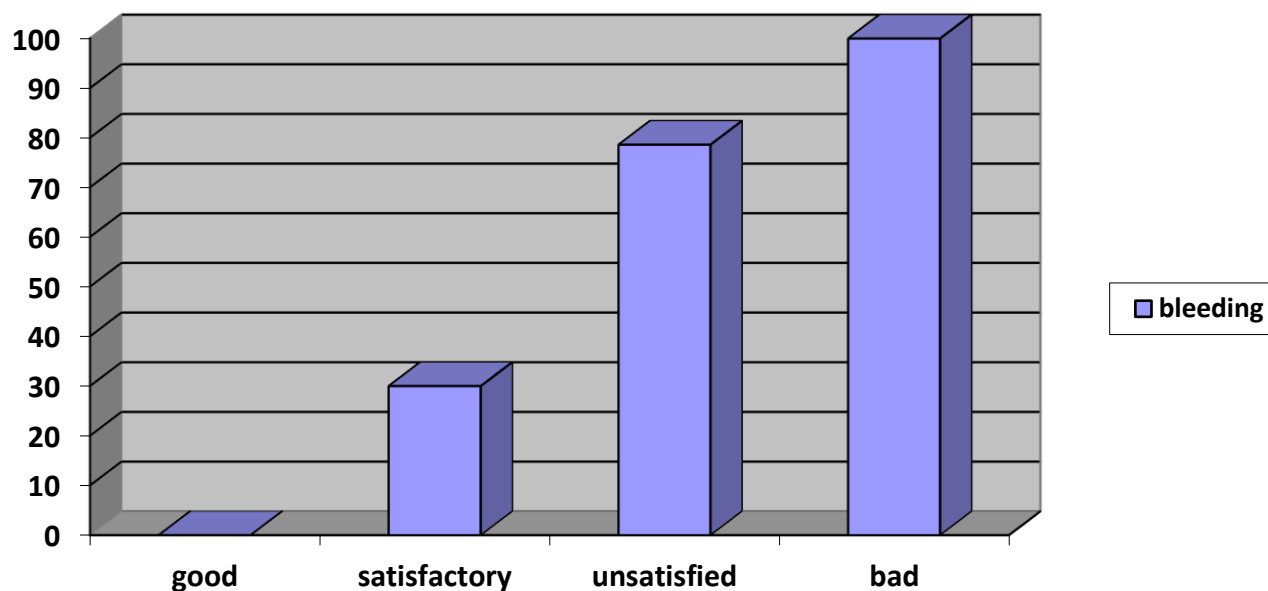


As a result of a survey of oral hygiene in patients, it was found that the average value of the oral hygiene index in children with diabetes mellitus was 1.7. This corresponds to poor oral hygiene. At the same time, good oral hygiene was noted in 1 person, satisfactory in 20 people, unsatisfactory in 28 and poor in 3 people.



Oral hygiene in children with diabetes diabetes, %

- Gingival bleeding was noted in 59.6% (31 people) of the examined children with diabetes mellitus.
- In the group of patients with good oral hygiene, there was no gingival bleeding; in the group of patients with satisfactory oral hygiene, 30% of children had gingival bleeding in one or more quadrants. In the group of children with poor oral hygiene, 78.6% had bleeding gums and in the group with poor oral hygiene, 100% of the examined had bleeding gums in two or more quadrants.



Conclusions

1. On the basis of the results obtained, one can judge the lack of awareness of children with diabetes mellitus about oral hygiene, namely the importance of twice regular brushing.
2. The state of oral hygiene in children with diabetes aged 6 to 17 years is unsatisfactory.
3. There is a connection between bleeding gums, as one of the symptoms of the periodontal inflammatory reaction, and the level of oral hygiene in children with diabetes mellitus.

A clinical study on the study of the characteristics of the dental status in children with type I diabetes mellitus allowed establish that they are more likely than healthy children to suffer from inflammatory periodontal pathology (gingivitis, periodontitis), and their dental caries proceeds more intensely than in children without somatic diseases. To maintain dental health of children with diabetes should be carried out during a dental appointment detailed instruction for parents on the rules of care behind the oral cavity and the optimal choice of means for individual oral hygiene in children.

In addition, such children, taking into account their age, need to be professionally trained once a quarter dental treatment and preventive measures using modern and effective oral care products.

REFERENCES

1. Albrant E.V. Features of the immune status of blood lymphocyte metabolism in children and adolescents with type 1 diabetes mellitus / E.V. Albrant, A.A. Savchenko, V.T. Manchuk // *Pediatrics*, 2004. No. 3. S. 19-22.
2. Ametov A.S. Insulin secretion and insulin resistance: two sides of the same coin / A.S. Ametov // *Problems of Endocrinology*, 2002. T. 48. No. 3. P. 31-37.
3. Vetoshkina M.S. Features of the course of chronic catarrhal gingivitis in diabetes mellitus against the background of the use of biologically active additive "Litovit": dis. ... cand. honey. Sciences / M.S. Vetoshkin. M., 2002. 153 p.
4. 10. Vinogradova, T.F. Dentistry of children's age / T.F. Vinogradova, O.P. Maksimov. M.: Medicine, 1987. S. 406-407.
5. Gazhva S.I. The use of linguistic diagnostics for the indication of diabetes mellitus / S.I. Gazhva // *Actual aspects of dentistry: Collection of scientific papers*. N. Novgorod, 1998. S. 31-32.
6. Zhukovsky, M.A. *Pediatric endocrinology: a guide for doctors* / M.A. Zhukovsky. 3rd ed., revised. and additional Moscow: Medicine, 1995. 358 p.
7. Zhukovsky M.A. Modern problems of pediatric diabetology / M.A. Zhukovsky, L.N. Shcherbacheva // *Bulletin of the USSR Academy of Medical Sciences*, 1983. No. 2. P. 59-64.

8. Zlobina O.A. The state of local immunity of the oral cavity in a patient with diabetes mellitus / O.A. Zlobina, T.D. Redinova // Tr. 5th Congress of the Dental Association of Russia. M., 1999. S. 195-196.
9. Makhsumova, Sayyora, et al. "Comprehensive Clinical Examination of the Oral Cavity in Children with Type 1 Diabetes Mellitus." *Central Asian Journal of Medical and Natural Science* 3.4 (2022): 21-24.
10. Махсумова, С. С., et al. "Особенности проявления сахарного диабета 1 типа у детей на слизистой оболочке полости рта и губ." *Вестник науки и образования* 15-2 (2021): 118.
11. Буриева, Н. А., and И. Ш. Махсумова. "Профилактическая работа в аспекте стоматологических заболеваний." *БКБ 60 С 56* (2019): 185.
12. Махсумова, С., et al. "Способы лечения острого герпетического стоматита у детей." *Stomatologiya* 1.1 (62) (2016): 75-82.
13. Махсумова, И., И. Мухамедов, and С. Махсумова. "ИЗУЧЕНИЕ АНТИМИКРОБНОЙ АКТИВНОСТИ НЕКОТОРЫХ ЛЕКАРСТВЕННЫХ ПРЕПАРАТОВ И УЛЬТРАЗВУКА." *Stomatologiya* 1.1 (74) (2019): 82-84.