Original Article

Early Histopathology In Oral Submucous Fibrosis (OSF) To Rule The Possibility Of Epithelial Dysplasia - Report Of Two Cases

Sisca Meida Wati[1], Abhishek Banerjee[2]*, Abhishek Chatterjee[3], Kumarjyoti Chatterjee[4], Retno Pudji Rahayu[5], Theresia Indah Budhy[6]

[1, *2, 5, 6] Faculty of dental medicine, Universitas Airlangga, Indonesia
[*2,4]Awadh dental college hospital, Jamshedpur, India
[3]Rampurhat Govt Medical College, Rampurhat, India

***Corresponding Author:** Dr. Abhishek Banerjee

*Adjunct Professor, Faculty of dental medicine, Universitas Airlangga, Indonesia
*Associate Professor, Department of Oral and Maxillofacial Pathology, Awadh Dental College & Hospital, Jamshedpur
Email: abhishek.banerjee376@gmail.com
DOI: 10.47750/pnr.2022.13.S05.56

Abstract

Oral submucous fibrosis (OSF) is a chronic scarring and progressive condition affecting the oral cavity, oropharynx and upper portion (1/3rd) of the esophagus. It is a potentially malignant disorder. It usually presents with trismus as the chronicity progresses with a pal presentation of the mucosa. Encountering a whitish patch, ulcer or a growth in the bed of Oral submucous fibrosis is something thought provoking. The malignant transformation potential of Oral submucous fibrosis is comparatively higher than other premalignant conditions affecting oral cavity. The need for biopsy at any stage of OSF is a necessity to rule out underlying pathogenicity to transform towards malignancy or dysplasia.

Key words: oral submucous fibrosis, malignant lesion, dysplasia in OSF

INTRODUCTION

Oral Submucous Fibrosis (OSF) has been classified as oral potentially malignant disorder. It is a chronic slowly progressing and scarring disease of oral cavity which also involves pharynx and esophagus afterwards[1]. The main risk factor is always been areca nut chewing. The histopathological features of this disease presents like a juxta epithelial inflammatory reaction followed by stromal changes[2,3]. The fibro-collagenous nature of the stroma also changes based on the chronicity. There is a constant epithelial atrophy and increase in the content of fibro-collagenous bundles in the stroma which leads to the trismus and inability to eat food with comfort. Marked increase in the prevalence of this disorder due to widespread use of ghutka preparation, tobacco, arecanut products. There is a global burden of this disease which ranges from 0.1 to 30 % in prevalence[4]. The published medical data on oral submucous fibrosis establishes the fact that arecanut plays an important role in the pathogenesis of oral submucous fibrosis[5]. Patients with Oral Submucous Fibrosis have been reported to develop malignancy that is oral squamous cell carcinoma at a higher rate compared to other oral potentially malignant disorders[6].

The nature of the disease being very much chronic, the international agency for research on cancer has categorized arecanut as a group 1 carcinogen[7]. The pre malignant characteristic of OSF was first described by paymaster in 1956[8]. Pindborg et al have reported malignant transformation rate to be 2.8 % while Murthy et al 1985 has reported it to be as 7.6 % over a period of 15 years but in 2022 a meta-analysis by Murthy V et al reported the malignant transformation rate to be 4 %[9,10,11].

There is always a controversy among clinicians whether to opt for biopsy in cases of oral submucous fibrosis or not. This paper will highlight the probable chances of development of dysplastic lesions and developing oral carcinoma over pre-existing oral submucous fibrosis condition. There are two cases put forward which highlights the role of histopathology of OSF.

Case 1

A 59 year male patient reported to the clinic complaining of mild pain and discomfort on the left lower posterior molar region. There was trismus and reduced mouth opening of less than 28mm. The patient was under observation since 1 year and produced numerous medical reports of different practitioners. Since last 6 months the patient was treated with prednisolone (both oral an intralesional) and multivitamins. The patient was previously diagnosed as oral submucous fibrosis after undergoing incisional biopsy from the left buccal mucosa 2 years back. The patient insisted us on getting a histopathology report done from the left lower posterior most regions after lower second molar. The area was slight

erythematous otherwise appearing normal. A provisional diagnosis of pericoronitis was rendered looking at the scenario of the patient.

The small fragile tissue bit was obtained for histopathology. The histopathology report was surprising. There was noted invasion of dysplastic epithelial islands into the stroma. There were keratin pearls seen in the stroma surrounded by chronic inflammatory cells predominantly lymphocytes; establishing the diagnosis as well differentiated squamous cell carcinoma. (Figure 1).

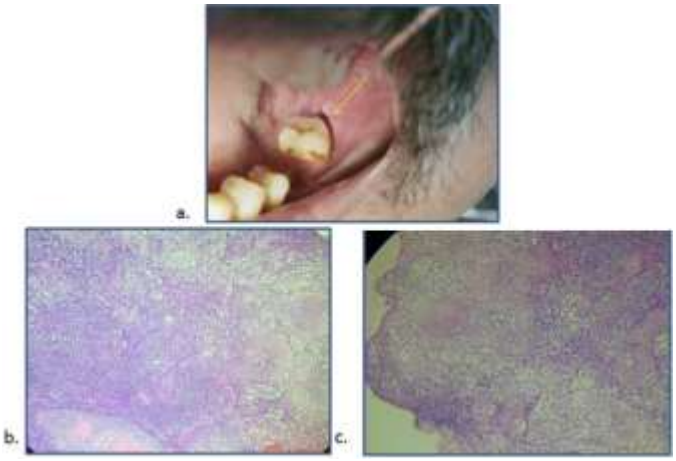

Figure 1: Diagnosed Differentiated squamous cell carcinoma and its keratin pearls in the stroma which is surrounded by chronic inflammatory cells (predominantly lymphocytes)

Case 2

A 45 year male patient reports to the outpatient department with a non-scrapable, non-tender and non- itchy pale whitish exophytic lesion on the right buccal mucosa. The patient gives a history of Ghutka chewing (a preparation of arecanut, tobacco and flavours) since past 20 years. The buccal mucosa was pale and blanched in appearance, leathery in consistency. A provisional diagnosis of leukoplakia over early OSF was rendered. After routine blood investigation, an Excisional biopsy was obtained and was sent for histopathology. On microscopy there was an evidence of hyperkeratosis, basilar hyperplasia and loss of epithelial architecture. A diagnosis of mild dysplasia superimposed on oral submucous fibrosis was rendered. (Figure 2)

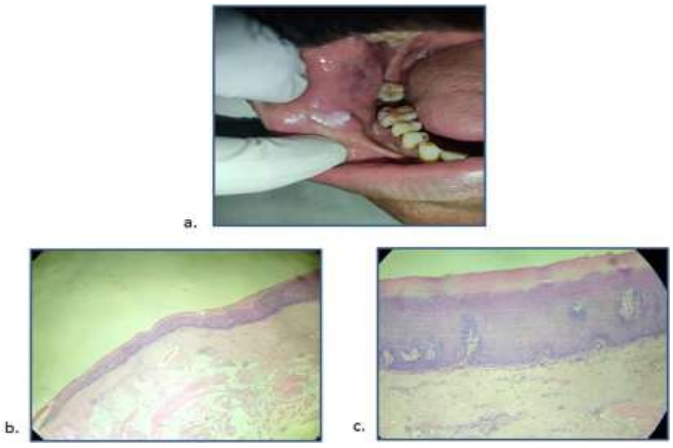

Figure 2: Mild dysplasia superimposed on oral submucous fibrosis showing basilar hyperplasia, hyperkeratosis and loss of epithelial architecture

DISCUSSION

Oral Submucous Fibrosis has always received less attention compared to the other oral potentially malignant disorders or lesions like leukoplakia and lichen planus. The habit of consuming areca nut has always been attributed to social causes, peer pressures and socio-economic status. Since it is well established that chewing areca nut is the main causative agent for this, retrospective reports have stated that more than 90% of the patients are betel chewers[12]. Genetic polymorphisms, deficiency in nutritional elements and immunological predispositions are contributory factors towards the pathogenesis[13]. But the underlying mechanism of undergoing transformation to carcinoma has still been a mystery. Experimental studies have demonstrated that arecoline induces chromosomal aberrations, reduced DNA repair and mechanism in keratinocytes mal-maturation. Kerr et al 2011 has classified that process based on the presence of any dysplastic lesion over it as stage IV disease[14]. This is classified as they possess more chance of transformation to malignancy.

OSF confirms to be a potential malignant disorder of the oral cavity though the exact malignant transmission rate could not be ascertained. There is always a gender imbalance which can be attributed to the subjects involved in the study and also the population group chosen. There is also differentiation in the observation based on geographic location due to the availability of different forms of arecanut. There are studies on expression of neo-angiogenic markers like VEGF and CD105 in Oral Submucous Fibrosis which depicts the progression of Oral Submucous Fibrosis from non-dysplasia to dysplasia[15]. This occurs due to loss of e-cadherin along with the upregulation of expression in the cytoplasm rather than membrane, leading to the dysplastic progression[16].

Epithelial changes that occur in OSF are precursors of carcinomatous change. Reports have shown that OSMF cases are at a higher risk of developing dysplastic changes in epithelium leading to leukoplakia and oral squamous cell carcinoma. There are markers like p63 which has been elaborately studied by Bhavle et al[17] and it was found more concentrated in the superficial layers of the epithelium which depicted proliferative potential rather than maturative potential of the lesion epithelium.

In the disease process of OSF, vascular constriction is a major finding due to fibrosis. There are hypoxia induced mechanisms which are involved in the pathogenesis of OSF. Angiogenesis is an important process in carcinogenesis, which promotes growth and spread of tumour. In advance degrees of dysplasia there has been dilation of blood vessels which supports the theory of tumourogenesis and growth maintenance[18, 19].

Understanding transformation of OSF into initial stages of dysplasia is complex phenomenon. The role of epithelium and connective tissue in development of carcinoma has many un-explored mechanisms. The epithelial mesenchymal interactions do play a role in malignant transformation, provide time as the important factor which takes part in the mechanisms[20]. Cell culture experiments are also done in order to study the phenotypic expressions of fibroblasts in varying toxicity levels similar in OSF.[21] Dysplasia in the OSF background is always a challenge and management is crucial.[22]
It is very important to obtain initial biopsy from OSF to know if there are any dysplastic changes happening and so there can be attempts to inhibit the malignant transformation.

CONCLUSION

Histopathology always stays as gold standard for any diagnosis of developing oral squamous cell carcinoma. Oral submucous fibrosis should be dealt seriously in order to prevent carcinomatous transformation. Though this is a potential malignant disorder still there is negligence among clinicians regarding diagnosing the stage through histopathology. Diagnosing the OSF stage through histopathology also give us an opportunity to rule out the presence of dysplasia and hence predicting the chances of malignant transformation.

REFERENCES

1. Tilakaratne WM, Klinikowski MF, Saku T, and Peters TJ, Warnakulasuriya S. Oral submucous fibrosis: review on aetiology and pathogenesis. Oral Oncol. 2006; 42:561-8.
2. Pandya S, Chaudhary AK, Singh M, Singh M, Mehrotra R. Correlation of histopathological diagnosis with habits and clinical findings in oral submucous fibrosis. Head Neck Oncol. 2009 May 2; 1:10. doi: 10.1186/1758-3284-1-10. PMID: 19409103; PMCID: PMC2691735.
3. Rajalalitha P, Vali S. Molecular pathogenesis of oral submucous fibrosis-a collagen metabolic disorder. J Oral Pathol Med. 2005; 34:321–28. doi: 10.1111/j.1600-0714.2005.00325.x.
4. Rao, N.R., Villa, A., More, C.B. et al. Oral submucous fibrosis: a contemporary narrative review with a proposed inter-professional approach for an early diagnosis and clinical management. J of Otolaryngol - Head & Neck Surg.2020;49(3): 1-11
5. Chandramani B. More, Naman Rajeshkumar Rao, Sucheta More & Newell W. Johnson Reasons for Initiation of Areca Nut and Related Products in Patients with Oral Submucous Fibrosis within an Endemic Area in Gujarat, India, Substance Use & Misuse.2020; 55(9): 1413-1421, DOI: 10.1080/10826084.2019.1660678
6. Murthy V, Mylonas P, Carey B, Yogarajah S, Farnell D, Addison O, Cook R, Escudier M, Diniz-Freitas M, Limeres J, Monteiro L, Silva L, Fricain JC, Catros S, Fenelon M, Lodi G, Lombardi N, Brailo V, Ariyaratnam R, López-López J, Albuquerque R. Malignant Transformation Rate of Oral Submucous Fibrosis: A Systematic Review and Meta-Analysis. J Clin Med. 2022 Mar 24; 11(7):1793. doi: 10.3390/jcm11071793. PMID: 35407401; PMCID: PMC8999767.
7. IARC Working Group on the Evaluation of Carcinogenic Risks to Humans. Betel-quid and Areca-nut Chewing and Some Areca-nut-derived Nitrosamines. Lyon (FR): International Agency for Research on Cancer; 2004. (IARC Monographs on the Evaluation of Carcinogenic Risks to Humans, No. 85.) Available from: https://www.ncbi.nlm.nih.gov/books/NBK316567/
8. Pindborg, J.J.; Chawla, T.N.; Srivastava, A.N.; Gupta, D.; Mehrotra, M.L. Clinical aspects of oral submucous fibrosis. Acta Odontol. Scand. 1964, 22, 679–691
9. Ray JG, Ranganathan K, Chattopadhyay A. Malignant transformation of oral submucous fibrosis: overview of histopathological aspects. Oral Surg Oral Med Oral Pathol Oral Radiol 2016; 122:200-9.
10. Kujan, O.; Mello, F.W.; Warnakulasuriya, S. Malignant transformation of oral submucous fibrosis: A systematic review and meta-analysis. Oral Dis. 2021, 27, 1936–1946.
11. Murthy V, Mylonas P, Carey B, Yogarajah S, Farnell D, Addison O, Cook R, Escudier M, Diniz-Freitas M, Limeres J, Monteiro L, Silva L, Fricain JC, Catros S, Fenelon M, Lodi G, Lombardi N, Brailo V, Ariyaratnam R, López-López J, Albuquerque R. Malignant Transformation Rate of Oral Submucous Fibrosis: A Systematic Review and Meta-Analysis. J Clin Med. 2022 Mar 24; 11(7):1793. doi: 10.3390/jcm11071793. PMID: 35407401; PMCID: PMC8999767.
12. Hazarey V.K., Erlewad D.M., Mundhe K.A., Ughade S.N. Oral Submucous Fibrosis: Study of 1000 cases from central India. J. Oral Pathol. Med. 2007; 36:12–17. doi: 10.1111/j.1600-0714.2006.00485.x.
13. Cheng RH, Wang YP, Chang JY, Pan YH, Chang MC, Jeng JH. Genetic Susceptibility and Protein Expression of Extracellular Matrix Turnover-Related Genes in Oral Submucous Fibrosis. Int J Mol Sci. 2020 Oct 30; 21(21):8104. doi: 10.3390/ijms21218104. PMID: 33143101; PMCID: PMC7663238.
14. Angadi P.V., Rao S.S. Management of Oral Submucous Fibrosis: An overview. Oral Maxillofac. Surg. 2010; 14:133–142. doi: 10.1007/s10006-010-0209-x.

15. Anura A, Das RK, Pal M, Paul RR, Ray AK, Chatterjee J. Correlated analysis of semi-quantitative immunohistochemical features of E-cadherin, VEGF and CD105 in assessing malignant potentiality of oral submucous fibrosis. Pathol Res Pract. 2014 Dec; 210(12):1054-63. doi: 10.1016/j.prp.2014.06.009. Epub 2014 Jun 24. PMID: 25015036.
16. Chakraborti S, Paul RR, Pal M, Chatterjee J, Das RK. Collagen deposition correlates with loss of E-cadherin and increased p63 expression in dysplastic conditions of oral submucous fibrosis. Med Mol Morphol. 2022 Mar;55 (1):20-26. doi: 10.1007/s00795-021-00304-7. Epub 2021 Sep 4. PMID: 34482436.
17. Bavle, RadhikaManoj & Paremala, Konda & Makarla, Soumya & Sudhakara, Muniswamappa & Venugopal, Reshma & Hosthor, Sreelatha. Predicting the Malignant Transformation of Oral Submucous Fibrosis Using Quantitative Biomarkers p63 and CD31. Journal of Orofacial Sciences.2020; 12(52): 10.4103/jofs.jofs_6_20.
18. Sharma E, Tyagi N, Gupta V, Narwal A, Vij H, Lakhnotra D. Role of angiogenesis in oral submucous fibrosis using vascular endothelial growth factor and CD34: An immunohistochemical study. Indian J Dent Res. 2019 Sep-Oct; 30(5):755-762. doi: 10.4103/ijdr.IJDR_186_17. PMID: 31854369.
19. Choudhari SS, Kulkarni DG, Patankar S, et al. Angiogenesis and Fibrogenesis in Oral Submucous Fibrosis: A Viewpoint. The Journal of Contemporary Dental Practice. 2018 Feb; 19(2):242-245.
20. Shetty SS, Sharma M, Fonseca FP, Jayaram P, Tanwar AS, Kabekkodu SP, Kapaettu S, Radhakrishnan R. Signaling pathways promoting epithelial mesenchymal transition in oral submucous fibrosis and oral squamous cell carcinoma. Jpn Dent Sci Rev. 2020 Nov; 56(1):97-108. doi: 10.1016/j.jdsr.2020.07.002. Epub 2020 Aug 22. PMID: 32874377; PMCID: PMC7452314.
21. Banerjee A, Mampilly MO, Kamath VV, Athreya V, Kotrashetti V, Srivastava KC, Shrivastava D. Phenotypic Expression of Oral Fibroblasts Derived from Oral Submucous Fibrosis: An Assay through Cell Culture. J Pharm Bioallied Sci. 2021 Nov; 13(Suppl 2):S1234-S1239. doi: 10.4103/jpbs.jpbs_408_21. Epub 2021 Nov 10. PMID: 35017962; PMCID: PMC8686880.
22. Shirsat PM, Desai RS, Bansal S, Prasad P. Oral epithelial dysplasia in oral submucous fibrosis: A challenge. Oral Oncol. 2016 Mar; 54:e19. doi: 10.1016/j.oraloncology.2015.11.005. Epub 2015 Nov 19. PMID: 26778245.