

Anatomical Variations Of Osteomeatal Complex In Chronic Rhinosinusitis Patients

Dr. Navin Agrawal¹, Dr. Chhavi Agrawal², Dr. Anand Sharma³, Dr. Purvi Aswani^{4*}, Dr. Shivam Narang⁵, Dr. Madhvi Maheshwari⁶, Dr. Akshita Bharagawa⁷, Dr. Rohit Maheshwari⁸, Dr. Harsh Dudhat⁹

¹professor & Hod, Department Of Otorhinolaryngology, Index Medical College Hospital & Research Centre, Indore, navinagrwal12@gmail.com

²associate Professor, Department Of Orl, Index Medical College Hospital & Research Centre, Indore. dr.chhaviag08@gmail.com

³assistant Professor, Department Of Orl, Index Medical College Hospital & Research Centre, Indore, dranand626@gmail.com

^{4,5,6}Pg Resident 3, Department Of Orl, Index Medical College Hospital & Research Centre, Indore, purviaswani@gmail.com

⁵shivamnarang1605@gmail.com , ⁶madhvi.m95@gmail.com

^{7,8,9}pg Resident 1, Department Of Orl, Index Medical College Hospital & Research Centre, Indore, akshitabhargawa078@gmail.com,

⁸rawhit031@gmail.com , ⁹harshdudhat@gmail.com

***Corresponding Author: Dr. Purvi Aswani**

*Pg Resident 3, Department Of Orl, Index Medical College Hospital & Research Centre, Indore, . Contact No. - +91-7999993709, Email- purviaswani@gmail.com ,OrCID: <https://orcid.org/0000-0001-7252-7723>

Doi: 10.47750/pnr.2022.13.S05.52

Abstract

Aim: To study the anatomical variations of osteomeatal complex commonly associated with paranasal sinus disease using computed tomography.

Methodology: A prospective longitudinal study was conducted in the ENT department of IMCHRC, Indore for a period of one year. All the adult patients with complaints suggestive of chronic rhinosinusitis for a period of more than 12 weeks, a total of 100 patients were involved in the study.

Results: In our study we observed the association between sinusitis and the anatomical variations of the osteomeatal complex and it has been found pneumatized middle turbinate to have strong significant association ($p < .05$) with maxillary, frontal and anterior ethmoidal sinusitis. Deviated Nasal Septum was the most common finding, which was significantly associated with anterior ethmoid sinusitis. Haller cells showed association with anterior ethmoid involvement (69.2%). Bilaterally obliterated osteomeatal complex had significant association with involvement of posterior ethmoidal sinus. Amongst the patients with Paradoxical uncinate process, all (100%) showed involvement of sphenoid sinus.

Conclusions: The importance of CT scan is emphasized in patients with persistent symptoms to identify the anatomical variations that may contribute to the development of chronic sinus mucosal disease.

INTRODUCTION:

Osteomeatal Complex (OMC) represents the final common pathway for drainage and ventilation for the paranasal sinuses in the skull. [1,2]. Scribano et al. have defined the osteomeatal complex as a complex including the maxillary sinus ostium, ethmoid infundibulum, and middle meatus. [3].

Of which the anterior OMC is the major draining ostia, as it drains the maxillary sinus, frontal sinus, anterior part of ethmoidal sinus whereas posterior OMC drains posterior part of ethmoid and sphenoid sinus.

Anatomical variants like Deviated Septum, pneumatized middle turbinate, Haller cells, agger nasi cells, and enlarged bulla ethmoidalis may obstruct the mucociliary clearance through osteomeatal complex, narrow osteomeatal channels [13].

The transition of frontal sinus to frontal recess has an hour-glass shape, with waist at level of frontal sinus ostium. Frontal recess can be influenced and narrowed by uncinate process, agger nasi cells, the ethmoidal bulla. These structures narrow inferior part of "hour-glass" [5] which leads to impaired drainage and dysventilation of the paranasal sinuses which are primary predispositions for development of sinusitis.

American Academy of Otorhinolaryngology and Head and Neck Surgery defined Rhinosinusitis as the condition manifested by an inflammatory response of the mucous membrane of the nasal cavity and paranasal sinuses, fluids within these cavities and / or underlying bone. Etiology of CRS includes structural anatomical obstruction, recurrent upper respiratory infections, allergies, biofilm formation and less commonly ciliary dyskinesias, mucopolysaccharidosis and cystic fibrosis. [11,12]

Over the past few decades, both CT and nasal endoscopy have been used successfully as diagnostic modalities in sinus disease. The purpose of these investigations is to determine the mucosal abnormalities and bony anatomic variations of paranasal sinus and assess the possible pathogenicity of these findings in patients undergoing evaluation for sinusitis. The normal OMC is visualized on 2 or 3 mm thick coronal CT section.[6]

The revolutionary changes in the surgical treatment of rhino sinusitis in recent years, particularly in endoscopic surgery, require the surgeons to have detailed knowledge of the anatomy of the lateral nasal wall, paranasal sinuses and surrounding vital structures and of the large number of anatomical variants in the region, many of which are detectable only using CT. [10]

AIM:

To study the anatomical variations of osteomeatal complex commonly associated with paranasal sinus disease using computed tomography.

MATERIAL AND METHODS:

A prospective longitudinal study was conducted in the ENT department of Index Medical College Hospital and Research Centre, Indore for a period of one year from September 2020 to September 2021.

The study was formally started after getting the clearance from the institutional ethical committee. All the adult patients of more than 17 years with complaints suggestive of chronic rhinosinusitis for a period of more than 12 weeks, patients with acute exacerbation of chronic rhinosinusitis and with persistent chronic rhinosinusitis requiring surgical intervention are included in our study. Patients with acute or fungal sinusitis, patients with mass or polyps obstructing the nasal cavity, with history of previous sinonasal surgeries or trauma with altered anatomy, patients with facial anomalies and with known ciliary motility disorder like Kartagener's syndrome or Down's syndrome were excluded from the study. Based on our inclusion and exclusion criteria a total of 100 patients were involved in the study. An informed written consent was obtained from all the study subjects.

A thorough clinical examination was done, and the diagnosis of CRS was established. All the patients in the acute phase of the disease were treated conservatively with a course of antibiotics, topical and oral decongestants. The patients with persistent symptoms and signs were counselled regarding endoscopic evaluation and imaging of nose and PNS by CT scan and further about the need for surgery.

Computed Tomography would be done by SOMATOM Definition AS 64 slice machine. After obtaining the scout projections, the area of scanning was designed to include the region from roof of frontal sinus upto the hard palate. Coronal sections were performed with the patients in prone position with extended neck and the plane perpendicular to axial plane. Limited axial sections were performed with the patient in supine position and the plane of data acquisition parallel to hard palate. All films are taken without contrast.

And would be graded by using Lund Mackay Scoring [14].

Sinus	Right sinus	Left sinus
Frontal	0-2	0-2
Anterior ethmoids	0-2	0-2
Posterior ethmoids	0-2	0-2
Maxillary	0-2	0-2
Sphenoid	0-2	0-2
Ostiomeatal complex	0 or 2	0 or 2

For the sinuses: 0 = no inflammation; 1 = partial inflammation; 2 = 100% inflammation.
 For the ostiomeatal complex: 0 = not occluded; 2 = occluded.
 Maximum total score: 24.

The data was entered into the excel sheet. The data was analysed using SPSS (Statistical Package for Social Sciences) 20.0 version. The descriptive statistics was performed. The data was described as numbers and percentages. The comparison between the groups was done using Chi-square test. p value<.05 was considered statistically significant. Confidence interval was set at 90%.

RESULTS:

Table I. Distribution Of Study Subjects Based On Age Groups

Age group	Number	Percentage
17-20 years	14	14%
21-30 years	33	33%
31-40 years	34	34%
41-50 years	11	11%
51-60 years	7	7%
>61 years	1	1%
Total	100	100%

Table II. Distribution Of Study Subjects Based On Gender

Age group	Number	Percentage
Male	53	53%
Female	47	47%
Total	100	100%

According to Table 1, the study included 100 patients. The mean age of the patients was 32.9400±11.46520 years (range-16.0-68.0 years). The maximum number of patients belonged to the age group of 31-40 years and 21-30 years (34.0% and 33.0% respectively).

Table 2 showed, the number of male patients was greater than the female patients (53.0% vs 47.0%).

Headache was the most common symptom. Unilateral nasal obstruction was a common finding as compared to bilateral nasal obstruction (43.0% vs 19.0%). And rhinorrhoea was present in 39.0% patients.

In Table 3, CT findings revealed deviated nasal septum in 83.0% patients, in maximum patients (43.0%) deviation of septum on right side was present. Spur was seen in 56.0% patients, in most of the patients (28.0%), it was present on right side. Concha bullosa was present in 58.0% patients; it was present most commonly on bilateral sides. Paradoxical middle turbinate and Enlarged Bulla Ethmoidalis were present in 4.0% patients (unilaterally in 2.0% patients and bilaterally in 2.0% patients). Pneumatization of Uncinate process was present in 6.0% patients and Hypertrophy was seen in none of the patients. Paradoxical uncinat process was seen in 2.0% patients while polypoid uncinat process was not seen.

Table III. Distribution Of Anatomical Variations Based On CT Findings

Anatomical Variations	Frequency	Percentage
Deviated nasal septum	83	83%
Spur	56	56%
Concha Bullosa	58	58%
Paradoxical Middle Turbinate	4	4%
Enlarged Bulla Ethmoidalis	4	4%
Uncinate process (Pneumatization)	6	6%
Uncinate process (Hypertrophy)	0	0
Uncinate process (Paradoxical)	2	2%
Uncinate process (polypoidal)	0	0
Agger Nasi Cells	0	0
Haller Cells	13	13%

Table IV. Based On Variations Of OMC On CT Scan

Variations of OMC	Frequency	Percentage
Patent	69	69%
Obliterated (Unilateral)	4	4%
Obliterated (Bilateral)	23	23%
Widening	4	4%

Table V. Based On Presence Of Sinusitis

Sinuses involved	No. Of Cases
Maxillary	69
Ethmoid	33
Sphenoid	29
Frontal	18
Maxillary and Sphenoid	20
Maxillary And Ethmoid	25
Ethmoid And Sphenoid	8
Maxillary, Ethmoid, Frontal	12
Maxillary, Ethmoid, Sphenoid	8
Pansinusitis	8

According to Table 4, Osteomeatal complex was obliterated in 27.0% patients and patent in 69% patients.

Shown in Table 5, amongst all the patients' maxillary sinusitis was found in 69% of patients followed by Ethmoidal sinusitis in 33% patients and least common was Frontal sinusitis in 18% patients. While Pansinusitis was only found in 8 patients.

Following conclusions were made from Table 6;

Amongst the patients with Concha bullosa (right & bilateral) more patients had maxillary sinus involvement. Bilaterally obliterated osteomeatal complex and presence of haller cells was also found significantly associated with maxillary sinus involvement.

A statistically significant association was found between concha bullosa and frontal sinus (p value<.05). Amongst the patients with frontal sinus involvement, a significantly greater proportion (90.0%) had no concha bullosa. The Unilateral Paradoxical Middle Turbinate and Enlarged Bulla Ethmoidalis was significantly associated with frontal sinus involvement.

A statistically significant association was seen between deviated nasal septum and anterior ethmoidal sinus involvement.

Amongst the patients with S shaped nasal septum, significantly greater number (100.0%) had anterior ethmoidal sinus involvement. A statistically significant association was found between concha bullosa and anterior ethmoidal sinus (p value<.05). Amongst the patients with Enlarged Bulla Ethmoidalis, a significantly greater proportion (100.0%) had sinus involvement.

Presence of Haller cells was significantly associated with anterior ethmoidal sinus involvement (69.2%).

Bilaterally obliterated osteomeatal complex had significant association with involvement of posterior ethmoidal sinus.

Amongst the patients with Paradoxical uncinat process, all (100.0%) were having involvement of sphenoid sinus. This shows significant association.

Table VI. Association Between Various CT Findings And Sinus Involvement (P Value)

Anatomical Variations Of OMC	Maxillary Sinusitis (n=68)	Frontal Sinusitis (n=18)	Anterior Ethmoidal Sinusitis(n=33)	Posterior Ethmoidal Sinusitis (n=12)	Sphenoidal Sinusitis (n=29)
Deviated Nasal Septum (n=83)	>.05	>.05	<.05	>.05	>.05
Spur (n=56)	>.05	>.05	<.05	>.05	>.05
Concha Bullosa (n=58)	<.05	<.001	<.05	<.001	<.05
Paradoxical Middle turbinate (n=4)	>.05	<.05	>.05	>.05	>.05
Enlarged Bulla Ethmoidalis (n=4)	>.05	<.001	<.05	<.001	>.05
Uncinate process (pneumatization) (n=6)	>.05	>.05	>.05	>.05	>.05
Uncinate process (hypertrophy) (n=0)	-	-	-	-	-
Uncinate process (paradoxical) (n=2)	<.05	>.05	>.05	>.05	<.05
Uncinate process (polypoidal) (n=0)	-	-	-	-	-
Agger Nasi Cells (n=0)	-	-	-	-	-
Haller cells (n=13)	>.05	>.05	<.05	>.05	>.05

*p value (<.05) is considered to be significant.

DISCUSSION:

Although chronic sinusitis is a clinically diagnosable condition, imaging studies are essential for assessing the extent of the disease and planning for surgical treatment.[16] At present CT scan study especially using coronal plane due to its similarity with the surgical orientation, is the most preferred imaging investigation for this purpose. [17-19]

In the present study, the concept developed by Stammberger & Kennedy [15] was adopted, defining osteomeatal complex as a functional unit of the anterior ethmoid complex representing the final common pathway for drainage and ventilation of the frontal, maxillary and anterior ethmoid cells. Any of these cells, clefts, ostia, recesses, or cavities may be affected by a pathological process, thereby contributing to the symptoms and pathophysiology of sinusitis.

Messerklinger reported that infundibulum and middle meatus were the most common sites influenced by anatomic variation of OMC and Stammberger found that more than 90% of this disease is caused by anatomic variation of OMC. [7,8,9]. Liu et al. [4] have demonstrated that greater the size of anatomical variant, the higher the frequency of association with paranasal sinus mucosal alterations at CT.

In several areas of the osteomeatal complex overcrowding due to anatomical variation, two mucosal layers contact each other, thus increasing the likelihood of local impairment of mucociliary clearance. Secretions may then be retained at the site, creating the potential for infection even without ostial closure. Anatomically, the most likely areas of mucosal contact are in the narrow mucosa lined channels of the middle meatus and the ethmoidal infundibulum.

Nasal Septal Deviation

Nasal septum is fundamental in the development of the nose and paranasal sinuses. Septal deviations may be cartilaginous, cartilaginous-bony type, or a combination of both. Since septal deviation causes lateral compression of the middle turbinate and uncinat process pushing them into the infundibulum and thus causes obstruction of osteomeatal complex, and related complications. Deviation of the nasal septum was found in 83% of cases in the present study. In other studies, this finding ranged from 14.1% to 80%: Dutra &Marchiori[20], 14.1%; Kinsui et al.[21], 23.3%; Arslan et al.[22], 36%; Earwaker[23], 44%; and Pérez-Piñas et al.[24], 80%.

Concha Bullosa

Concha bullosa (pneumatized middle turbinate) has been implicated as a possible aetiological factor in the causation of recurrent chronic sinusitis. It is due to its negative influence on paranasal sinus ventilation and mucociliary clearance in the middle meatus region as quoted by Tonai [25].

Zinreich et al. report that conchae bullosa are best diagnosed radiographically and easily identified with CT[29]. The appearance is that of an air space of the middle concha surrounded by an oval bony rim. In our study, the incidence was 58%. (Unilateral-24%, bilateral- 34%). The prevalence of concha bullosa in our study is on the higher side when compared to the findings of Stallmann et al., [28], Maru et al., [26] and Alkire BC et al., [27] who reported it to be 44%, 42.6% and 41.7% respectively.

Paradoxically Curved Middle Turbinate

The middle turbinate may be paradoxically curved i.e., bent in the reverse direction. This may lead to impingement of the middle meatus and thus to sinusitis. Stammberger and Wolf [30] accepted paradoxical curvature of the middle turbinate as an etiological factor for CRS because it may cause obliteration or alteration in nasal air flow dynamics. It was found

in 4% of the patients; It is less than that reported by 12% by Asruddin et al., [31] and 15% by Llyod [32], Bolger et al., 27% and Al-Qudah et al., 18% respectively [33,34]. Lesser prevalence of paradoxically middle turbinate was observed by Wani et al., [6].

Uncinate Process

The uncinat process is a thin, bony leaflet that resembles a hook. It is oriented almost sagittally and runs from anterosuperior to posteroinferior. We observed that the uncinat process may be paradoxical or pneumatized. Variations of uncinat can impair sinus

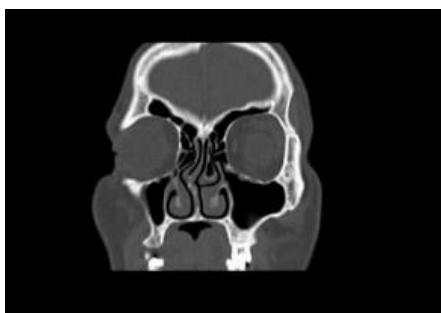ventilation especially in the anterior ethmoid, frontal recess and infundibulum regions. Hypertrophied uncinat process causes narrowing of the hiatus semilunaris and the ethmoid infundibulum. It has also been suggested as a predisposing factor for impaired ventilation of the anterior group of sinuses and frontal sinus. Pneumatisation and paradoxical uncinat process was observed in 6% and 2% of the cases respectively which is very less as compared to the findings of Wani et al., who reported it to be 21% in chronic rhino sinusitis cases [6].

Agger Nasi Cell

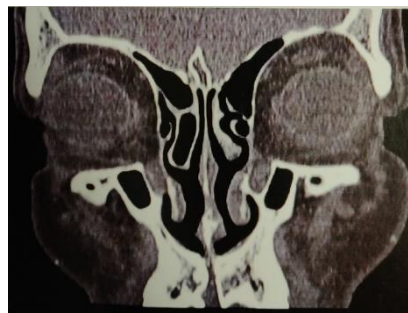Agger nasi cells lie just anterior to the anterosuperior attachment of the middle turbinate and frontal recess. These can invade the lacrimal bone or the ascending process of maxilla. These cells were not observed in our study. According to Liu X et al., [35] and Llyod et al., [36] who reported the prevalence of agger nasi cell as 0.7% and 3% in chronic rhinosinuisitis cases whereas in the study by Dua et al., [37] agger nasi cells were found to be present in 20 patients (40%). The prevalence is very less as compared to 98.5% by Bolger [38], 88.5% by Maru [26], 86.7% by Tonai and Baba [39] and 48% by Asruddin [31].

Haller's Cell

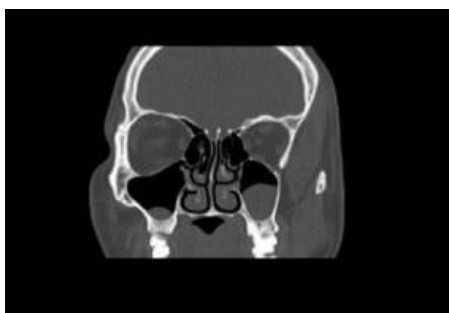Zinreich et al.,[40] and Kennedy et al., [41] described Haller's cells as ethmoid air cells found inferior to the ethmoid bulla adhering to the roof of the maxillary sinus, in continuity with the proximal infundibulum, which formed part of the lateral wall of the infundibulum. They are considered as ethmoid cells that grow into the floor of orbit and may narrow the adjacent ostium of the maxillary sinus especially if they become infected [42]. Davis et al., [43] noted the haller cell is thought to cause chronic sinusitis cases by impinging on the ostium of the maxillary sinus and infundibulum by inhibiting the ciliary function, leading to obstruction of the ostium. In our study prevalence was found to be 13% which is similar to 16%, Llyod et al., [36] 15%, Perez-Pinas et al., [24] 20%, Tonai and Baba [39] 36%, Bolger et al., [33] 45.9%, Maru et al., [26] 36%, Alkire BC et al., [27] 39.9% and Asruddin et al., [31] 28% respectively.



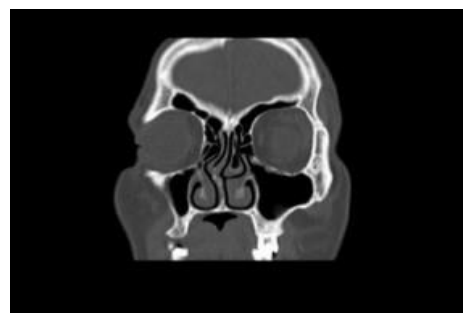CT PNS SHOWING SEPTAL SPUR TO RIGHT SIDE



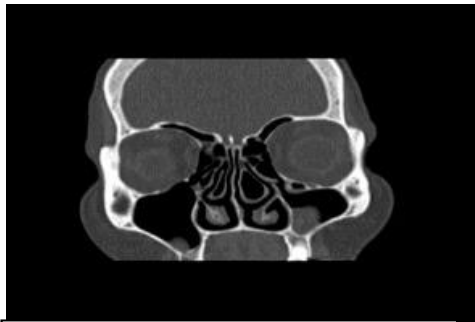
CT PNS SHOWING RIGHT SIDE CONCHA BULLOSA



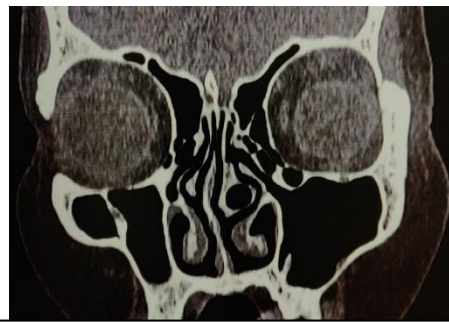CT PNS SHOWING BILATERAL ETHMOIDAL BULLA



CT PNS SHOWING RIGHT PNEUMATISED UNCINAT PROCESS



CT PNS SHOWING LEFT HALLER CELL



CT PNS SHOWING LEFT SIDE DNS WITH CONCHA BULLOSA

CONCLUSION:

Anatomical variations are common in the osteomeatal complex. Deviated nasal septum was the most common anatomical variation encountered in our study followed by concha bullosa and Haller cells.

CT scan must be done prior to any functional endoscopic sinus surgery. They help in assessing the extent of sinus disease and to know the anatomical variations.

Awareness of the possibility of such variations helps in making surgical decisions.

REFERENCES:

- Laine FJ, Smoker WR (1992) The osteomeatal unit and endoscopic surgery: anatomy, variations, and imaging findings in inflammatory diseases. *AJR Am J Roentgenol* 159:849–857
- Stammberger H, Hawke M (1993) *Essentials of endoscopic sinus surgery*. Mosby Inc., St. Louis, pp 1–108
- Scribano E, Ascenti G, Cascio F, Racchiusa S, Salamone I (1993) Computerized tomography in the evaluation of anatomic variations of the osteomeatal complex. *Radiol Med (Torino)* 86:195–199
- Liu X, Han D, Zhou B (1998) Relationship between anatomic variants of nasal sinus and chronic sinusitis. *Zhonghua Er Bi Yan Hou Ke Za Zhi* 33:149–152
- Stammberger H (1991) *Functional endoscopic sinus surgery*: pp 9
- Wani AA, Kanotra S, Lateef M, Ahmad R, Qazi SM, Ahmad S. CT scan evaluation of the anatomical variations of the osteomeatal complex. *Indian J Otolaryngol Head Neck Surg.* 2009;61:163-8.
- Stammberger H. Anatomic and Pathophysiologic Considerations. *Endoscopic endonasal surgery. Concepts in treatment of recurring rhinosinusitis. Otolaryngol Head and Neck Surg.* 1986;94:143-6.
- Zinreich SJ, Kennedy DW. Paranasal sinuses. CT imaging requirements for endoscopic surgery. *Radiol.* 1987;163:769-74.
- Lee KJ. *Textbook of otolaryngology and head and neck surgery*. New York: Elsevier; 1989: 222-223.
- Bolger WE, Butzin CA, Parsons DS. Paranasal sinus bony anatomic variations and mucosal abnormalities: CT analysis for endoscopic sinus surgery. *Laryngoscope.* 1991; 101:56-64
- Sandring S, Ellis H, Healy JC, Johnson D, Williams A. *Gray's Anatomy* 39th ed. Edinburgh. London. New York; 2005: 567-579.
- Riello APL, Boasquesvisque EM. Anatomical variants of the osteomeatal complex: tomographic findings in 200 patients. *Radiol Bras J.* 2008; 41:149-54.
- Shpilberg KA, Daniel SC, Doshi AH, Lawson W, Som PM. CT of Anatomic Variants of the Paranasal Sinuses and Nasal Cavity - poor Correlation with Radiologically Significant Rhinosinusitis but Importance in Surgical Planning. *Neuroradiology/Head and Neck Imaging AJR.* 2015; 204:1255-60.
- Renuka Bradoo, *Anatomical principles of endoscopic sinus surgery: a step-by-step approach*, chapter 4, page 59
- Stammberger HR, Kennedy DW. Paranasal sinuses: anatomic terminology and nomenclature. The Anatomic Terminology Group. *Ann OtolRhinolLaryngol Suppl.* 1995; 167:7–16.
- Gebrim ES. Relevance of sinonasal anatomical variations in the preoperative evaluation by computed tomography for endonasal surgery. *Radiol Bras.* 2008; 41:5-6.
- Jones NS. CT of the paranasal sinuses: a review of the correlation with clinical, surgical and histopathological findings. *Clin Otolaryngol Allied Sci.* 2002; 27:11-7.
- Stankiewicz JA, Chow JM. The low skull base-is it important? *Curr Opin Otolaryngol Head Neck Surg.* 2005; 13:19–21.
- Hudgins P. Complications of endoscopic sinus surgery: the role of the radiologist in prevention. *Radiologic Clin North Am.* 1993; 31:21–32.
- Dutra LD, Marchiori E. Tomografiacomputadorizada helicoidal dos seiosparanasaisnacrionça:avaliação das sinusopatiasinflatórias. *Radiol Bras.* 2002;35:161–9.
- Kinsui MM, Guilherme A, Yamashita HK. Variaçõesanatômicas e sinusopatias: estudoportomografiacomputadorizada. *Rev Bras Otorrinolaringol.* 2002;68:645–52.
- Arslan H, Aydinlioglu A, Bozkurt M, et al. Anatomic variations of the paranasal sinuses: CT examination for endoscopic sinus surgery. *Auris Nasus Larynx.* 1999; 26:39–48.
- Earwaker J. Anatomic variants in sinonasal CT. *Radiographics.* 1993;13:381–415.
- Pérez-Piñas, Sabaté J, Carmona A, et al. Anatomical variations in the human paranasal sinus region studied by CT. *J Anat.* 2000;197:221–7.
- Danese M, Duvosin B, Agrifoglio A, Cherpillod J, Kraysenbuhl M. Influence of naso-sinusal anatomic variants on recurrent, persistent or chronic sinusitis; X-ray computed tomographic evaluation in 112 patients. *J Radiol.* 1997;78:651–57.
- Maru YK, Gupta Y. Concha bullosa: frequency and appearances on sinonasal CT. *Indian J Otolaryngol.* 1999-2000;52:40-45.
- Alkire BC, Bhattacharyya N. An assessment of sinonasal anatomic variants potentially associated with recurrent acute rhinosinusitis. *Laryngoscope.* 2010;120:631-34
- Stallman JS, Lobo JN, Som PM. The incidence of concha bullosa and its relationship to nasal septal deviation and paranasal sinus disease. *Am J Neuroradiol.* 2004;25:1613-18.
- Zinreich SJ, Mattox DE, Kennedy DW, Chisholm HL, Diffley DM, Rosenbaum AE (1988) Concha bullosa: CT evaluation. *Journal of Computer Assisted Tomography* 12:778-784.
- Stammberger H, Wolf G. Headaches and sinus disease: the endoscopic approach. *Ann Oto RhinolLaryn.* 1988;97:3-23.
- Asruddin, Yadav SPS, Yadav RK, Singh J. Low dose CT in chronic sinusitis. *Indian J Otolaryngol.* 1999-2000;52:17-22.

32. Llyod GA. CT scan of the paransal sinuses: study of a control series in relation to endoscopic sinus surgery. *Laryngo Rhino Otol.* 1990;104:477-81.
33. Bolger WE, Butzin CA, Parsons DS. Paranasal sinus bony anatomic variations and mucosal abnormalities: CT analysis for endoscopic sinus surgery. *Laryngoscope.* 1991; 101:56-64
34. [34] Al-Qudah MA. Anatomical variations in sino-nasal region: A computer tomographic (CT) study. *J Med J.* 2010;44:290-97
35. Liu X, Zhan G, Xu G. Anatomic variations of osteomeatal complex and correlation with chronic sinusitis:CT evaluation. *Zhonghua Er Bi Yan Hou Ke Za Zhi.* 1999;34:143-46
36. Llyod GA. CT scan of the paransal sinuses: study of a control series in relation to endoscopic sinus surgery. *Laryngo Rhino Otol.* 1990;104:477-81.
37. Dua K, Chopra H, Khurana AS and Munjal M. CT scan variations in chronic sinusitis. *Ind J RadiolImag.* 2005;15:315-20.
38. Bolger WE, Butzin CA, Parsons DS. Paranasal sinus bony anatomic variations and mucosal abnormalities: CT analysis for endoscopic sinus surgery. *Laryngoscope.* 1991; 101:56-64.
39. Tonai A, Baba S. Anatomic variations of the bone in sinonasal CT. *Acta Otolaryngol Suppl.*1996;525:9-13.
40. Zinreich SJ, Kennedy DW, Rosenbaum AE, Gayler BW, Kumar AJ, Stammberger H. Paranasal sinuses: CT imaging requirement for endoscopic surgery. *Radiology.* 1987; 163:769-75.
41. Zinreich SJ, Kennedy DW, Gayler BW. Computer tomography of nasal cavity and paranasal sinuses: An evaluation of anatomy for endoscopic sinus surgery. *Clear images.* 1988;1:2-10
42. Davis WE, Templer J, Parsons DS. Anatomy of the paranasal sinuses. *Otolaryngol. Clin. North Am.* 1996;29:57-91.
43. Kayalioglu G, Oyar O, Govsa F. Nasal cavity and paranasal sinus bony variations: a computed tomographic study. *Rhinology.* 2000;38:108-13.