

Assessment Of Changes In Alveolar Bone Width Around Dental Implants At Native And Reconstructed Bone Sites With CBCT

Dr. Pragati Rawat¹, Dr. Abhinav Sharma², Dr. Prashant Singh^{3*}, Dr. Sania⁴, Dr. Prateek Kumar Singh⁵

¹Assistant Professor, Department of Prosthodontics and crown and bridge, Subharti Dental College, Meerut, UP, India

²Assistant Professor, Department of Oral Medicine and Radiology, Subharti Dental College, Meerut, UP, India

^{3,4}Reader, Department of Periodontology Institute of Dental Sciences, Sehora, Jammu, Jammu and Kashmir, India

⁵Reader, Dept of Periodontology, Kothiwal Dental College and Research Centre, Moradabad, Uttar Pradesh, India

*Corresponding author: Dr. Prashant Singh

*Reader, Department of Periodontology Institute of Dental Sciences, Sehora, Jammu, Jammu and Kashmir, India

DOI: 10.47750/pnr.2022.13.S05.34

Abstract

Background: The extraction of a tooth initiates a series of reparative processes involving alveolar bone, periodontal ligaments, and the gingiva. The present study was conducted to assess changes in alveolar bone width around dental implants at native and reconstructed bone sites with CBCT.

Materials & Methods: 56 patients who received dental implants of both genders were subjected to thorough oral examination followed by CBCT scan of the implant recipient site. Dental implant insertion was done following all standardized measures. Horizontal alveolar bone widths around implants at three levels (subcrestal width 1 mm (CW1), subcrestal width 4 mm (CW4), and subcrestal width 7 mm (CW7)) were measured in all patients.

Results: Out of 56 patients, males were 36 and females were 20. The mean bone width at CW1 pre-surgery was 7.04 mm and post-surgery was 6.82 mm, at CW4 pre-surgery was 9.81 mm and post-surgery was 9.12 mm and at CW7 pre-surgery was 11.36 mm and post-surgery was 11.15 mm. The difference was significant ($P < 0.05$). The bone width at CW1 at native bone was 0.35 mm and at ARP/GBR was -0.03 mm, at CW4 at native bone was 0.58 mm and at ARP/GBR was 0.22 mm and at CW7 at native bone was 0.24 mm and at ARP/GBR was 0.03 mm. The difference was non-significant ($P > 0.05$).

Conclusion: Significant alveolar bone width resorption was observed at only the middle third of all sites. CBCT scans can be used to observe long-term changes in the alveolar bone width around dental implants at native and reconstructed bone sites.

Key words: alveolar bone width, CBCT, vertical bone defects

INTRODUCTION

Bone loss is an increasing problem in the long-term treatment of implant patients. Monitoring of vertical bone defects surrounding oral or vestibular aspects of the tooth or implants, remains a challenge for clinical examination. The alveolar process is dependent on the teeth as they develop and remodel with their formation and eruption; therefore, the shape, location, and function of the teeth determine the alveolar morphology.¹

The extraction of a tooth initiates a series of reparative processes involving alveolar bone, periodontal ligaments, and the gingiva.² After dental extraction, the height of the buccal wall decreases, which results in the disappearance of bundle bone. Resorption of the alveolar ridges most often occurs during the first 6 months after tooth extraction. The rate of resorption varies among different individuals and the same individual at different times. Related factors of the resorption rate are divided into anatomic, metabolic, functional, and prosthetic factors.³

Conventional intra-oral radiographs (CRs) show interproximal alveolar bone levels,⁴ but three-dimensional (3D) information in oro-vestibular direction is projected onto the two-dimensional (2D) radiographs and therefore is not accessible. CR suffers from its inherent 2D nature, with anatomical superposition and geometric distortion, limiting the visibility of, for example, intra-osseous defects and their changes over time.⁴

Since the introduction of CBCT in 1998, indications for this imaging method include implant site assessment, temporomandibular joint examination, visualization of periodontal osseous situation and identification of periodontal ligament spaces. Compared with CT, radiation exposure to the patient is generally lower in CBCT. This technique uses isotopic voxels of a size down to 0.08 mm. Additionally, metallic artefacts are less severe in CBCT than in CT.⁵ The present study was conducted to assess changes in alveolar bone width around dental implants at native and reconstructed bone sites with CBCT.

MATERIALS & METHODS

The present study comprised of 56 patients who received dental implants of both genders. All were informed regarding the study and their written consent was obtained.

Data such as name, age, gender etc. was recorded. All patients were subjected to a thorough oral examination followed by CBCT scan of the implant recipient site. Dental implant insertion was done following all standardized measures. Horizontal alveolar bone widths around implants at three levels (subcrestal width 1 mm (CW1), subcrestal width 4 mm (CW4), and subcrestal width 7 mm (CW7)) were measured in all patients. Data thus obtained were subjected to statistical analysis. P value < 0.05 was considered significant.

RESULTS

Table I Distribution of patients

| Total- 56 | | |
|-----------|-------|---------|
| Gender | Males | Females |
| Number | 36 | 20 |

Table I shows that out of 56 patients, males were 36 and females were 20.

Table II Assessment of bone widths around implants before and after the implantsurgery

| Sub-crestal levels | Pre- surgery | Post- surgery | P value |
|--------------------|--------------|---------------|---------|
| CW1 | 7.04 | 6.82 | 0.52 |
| CW4 | 9.81 | 9.12 | 0.04 |
| CW7 | 11.36 | 11.15 | 0.65 |

Table II, graph I shows that mean bone width at CW1 pre- surgery was 7.04 mm and post- surgery was 6.82 mm, at CW4 pre- surgery was 9.81 mm and post- surgery was 9.12 mm and at CW7 pre- surgery was 11.36 mm and post- surgery was 11.15 mm. The difference was significant (P< 0.05).

Graph I Assessment of bone widths around implants before and after the implantsurgery

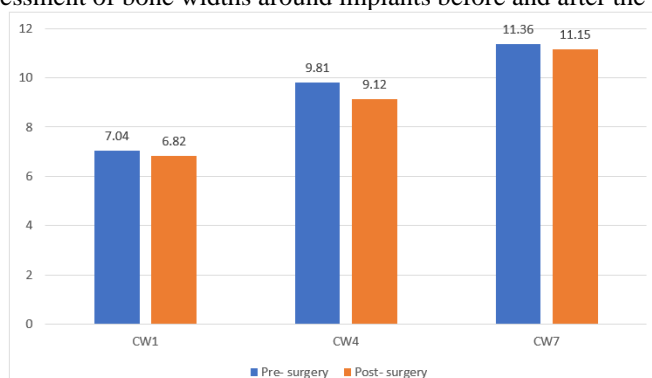


Table III Change of bone width around implants at native bones and ridge preservation/augmentation bones

| Sub-crestal levels | Native bone | ARP/GBR | P value |
|--------------------|-------------|---------|---------|
| CW1 | 0.35 | -0.03 | 0.05 |
| CW4 | 0.58 | 0.22 | 0.24 |
| CW7 | 0.24 | 0.03 | 0.36 |

Table III shows that bone width at CW1 at native bone was 0.35 mm and at ARP/GBR was -0.03 mm, at CW4 at native bone was 0.58 mm and at ARP/GBR was 0.22 mm and at CW7 at native bone was 0.24 mm and at ARP/GBR was 0.03 mm. The difference was non- significant (P> 0.05).

DISCUSSION

Dental Implants is an important dentistry in the recent years. Only limited universities and practitioners used to place and use dental implant treatment in the late 1980s.⁶ Later on, dental implants started to be used in partially edentulous patients with the developments of implant material, components and design. Adequate treatment planning and successful dental treatment relies on accurate diagnosis. An important tool for accurate diagnosis and treatment planning of implants is diagnostic imaging.⁷The demand of three-dimensional (3D) imaging for evaluation of bone quality and quantity in some cases had led to the use of CT in previous years.⁸ With the advance in technology and the release of Cone Beam Computed Tomography (CBCT) it's now possible to get 3D images with lower radiation. CBCT nowadays is an important diagnostic tool for dental implant treatment planning and offers a good spatial resolution.^{9,10}The present study was conducted to assess changes in alveolar bone width around dental implants at native and reconstructed bone sites with CBCT.

We found that out of 56 patients, males were 36 and females were 20. Payne et al recorded a 0.35 mm loss of bone height at the crest after one year of conventional loading and was reduced to 0.09 mm after two years. Nickenig et al¹¹ after six

and twelve months of functional loading found mean marginal bone loss of 0.8 mm and 1.1 mm respectively associated with the machined neck implants, while the rough-surfaced micro threaded neck implants scored 0.4 mm and 0.5 mm mean marginal bone loss respectively.

We found that the mean bone width at CW1 pre- surgery was 7.04 mm and post- surgery was 6.82 mm, at CW4 pre-surgery was 9.81 mm and post- surgery was 9.12 mm and at CW7 pre- surgery was 11.36 mm and post- surgery was 11.15 mm. Yamany et al¹²evaluated bone loss around implants after delivery of implant supported over dentures using CBCT. The implants were divided in two groups. Implants bearing locator attachment with blue nylon insert (Group I) and implants bearing locator attachment with transparent nylon insert (Group II). The twenty inserted implants were left undisturbed for three months to achieve osseointegration. The mesial, distal, buccal and lingual bone level around the dental implants was evaluated, using the CBCT i-CAT scan with Blue sky Plan® software. Bone level was obtained at six and twelve months after loading. The CBCT measurements of bone level revealed that there was bone loss around all aspects of the inserted twenty dental implants.

We observed that the bone width at CW1 at native bone was 0.35 mm and at ARP/GBR was -0.03 mm, at CW4 at native bone was 0.58 mm and at ARP/GBR was 0.22 mm and at CW7 at native bone was 0.24 mm and at ARP/GBR was 0.03 mm. Previous studies have often assessed peri-implantitis or loss of crestal bone level in long-term follow-up periods using periapical or bitewing radiographs.^{13,14} However, periapical and bitewing radiographs are 2D images, which cannot truly show changes in width. CBCT provides a 3D view of an anatomical structure in relation to the teeth and implants and detects width changes on the buccal and lingual sides.

The limitation the study is small sample size.

CONCLUSION

Authors found that significant alveolar bone width resorption was observed at only the middle third of all sites. CBCT scans can be used to observe long-term changes in the alveolar bone width around dental implants at native and reconstructed bone sites.

REFERENCES

1. Schropp, L.; Wenzel, A.; Kostopoulos, L.; Karring, T. Bone healing and soft tissue contour changes following single-tooth extraction: A clinical and radiographic 12-month prospective study. *Int. J. Periodontics Restor. Dent.* 2003;23:313–323.
2. Barone, A.; Ricci, M.; Tonelli, P.; Santini, S.; Covani, U. Tissue changes of extraction sockets in humans: A comparison of spontaneous healing vs. Ridge preservation with secondary soft tissue healing. *Clin. Oral Implant. Res.* 2013;24: 1231–1237.
3. Pietrokovski, J.; Massler, M. Alveolar ridge resorption following tooth extraction. *J. Prosthet. Dent.* 1967;17: 21–27.
4. Atwood, D.A. Some clinical factors related to rate of resorption of residual ridges. *J. Prosthet. Dent.* 2001; 86: 119–125.
5. Ten Heggeler, J.M.; Slot, D.E.; Van der Weijden, G.A. Effect of socket preservation therapies following tooth extraction in non-molar regions in humans: A systematic review. *Clin. Oral Implant. Res.* 2011; 22:779–788.
6. Tan, W.L.; Wong, T.L.; Wong, M.C.; Lang, N.P. A systematic review of post-extraction alveolar hard and soft tissue dimensional changes in humans. *Clin. Oral Implant. Res.* 2012; 23: 1–21.
7. Chappuis, V.; Araujo, M.G.; Buser, D. Clinical relevance of dimensional bone and soft tissue alterations post-extraction in esthetic sites. *Periodontol.* 2000 2017;73:73–83.
8. Chen, P.; Yu, S.; Zhu, G. The psychosocial impacts of implantation on the dental aesthetics of missing anterior teeth patients. *Br. Dent. J.* 2012;213:20.
9. Hartmann, R.; Bandeira, A.; Araujo, S.C.; Bragger, U.; Schimmel, M.; Leles, C.R. A parallel 3-group randomised clinical trial comparing different implant treatment options for the edentulous mandible: 1-year effects on dental patient-reported outcomes and chewing function. *J. Oral Rehabil.* 2020;47: 1264–1277.
10. Payne AG, Tawse-Smith A, Duncan WD& Kumara R. Conventional and early loading of un-splinted ITI implants supporting mandibular overdentures. *Clin Oral Implants Res.* 2002;13(6):603-609.
11. Nickenig H-J, Wichmann M, Schlegel KA, Nkenke E&Eitner S. Radiographic evaluation of marginal bone levels adjacent to parallel-screw cylinder machined-neck implants and rough surfaced microthreaded implants using digitized panoramic radiographs. *Clin Oral Impl Res.* 2009;20: 550–554.
12. Yamany IA. The Employment of CBCT in Assessing Bone Loss around Dental Implants in Patients Receiving Mandibular Implant Supported over dentures. *International Journal of Pharmaceutical Research & Allied Sciences.* 2019 Jul 1;8(3).
13. Mericske-Stern R, Steinlin Schaffner T, Marti P&Geering AH. Peri-implant mucosal aspects of ITI implant supporting overdentures. A five-year longitudinal study. *Clin Oral Implants Res.* 1994;5:9-18.
14. Simon H& Caputo A. Removal torque of immediately loaded transitional endosseous implants in human subjects. *Int J Oral Maxillofac Implants*2002; 17:839–845.