

A review on the impact of deep learning in the identification of atrial septal defect and a comparative study on the algorithms employed in the imaging modalities

Hima Vijayan V P¹, Prof. (Dr.) Abdul Rahiman², Dr. Lizy Abraham³

¹Department of Electronics & Communication Engineering, LBS Institute of Technology for Women, APJ Abdul Kalam Kerala Technological University, Kerala, India.

²Director, LBS Centre for Science & Technology, Trivandrum, Kerala, India.

³Assistant Professor, Department of Electronics & Communication Engineering, LBS Institute of Technology for Women, Trivandrum, Kerala, India

Email: himavijayan@gmail.com¹, researchlbsitw2020@gmail.com², lbsitwresearch2020³

DOI: 10.47750/pnr.2022.13.S01.228

Abstract

Among the congenital coronary heart diseases, atrial septal defect constitutes the 1/3 most common type. In many cases, the affected person stays asymptomatic for the duration of the youth even having big shunts. Methodologies that may be hired for figuring out the defects are : echocardiogram , chest X-ray, electrocardiogram, cardiac catheterization, MRI, CT scan, phonocardiogram . Deep learning may be correctly utilised for the automatic estimation of the illness from the test result. The purpose of this review paper is to offer an perception into ASD, the strategies for figuring out it and the application of deep learning models for distinguishing the illness. The paper opinions diverse algorithms used for identity of defects also points out the restrictions of every algorithm.

Keywords: Atrial Septal defect; Image Processing; Deep learning; Diagnostic tools; Classifiers; CNN; U-Net architecture; LSTM; Image Segmentation ; MRCNN.

INTRODUCTION

Congenital coronary heart disease (CHD) is the most regularly taking place congenital disease and is answerable for approximately 28% of congenital birth defects [1]. A group of serious heart defects which might be present from birth is crucial congenital coronary heart disease. There is a big variation of care available for kids in medium income countries, along with India, than it from high income countries. Due to this big number of affected ones and restricted sources, a massive percentage of kids with CHD cross undiagnosed and untreated in India. For the control of kids with CHD over the past three decades, a great quantity of development has been made in India, however it nevertheless stays grossly inadequate. In order to enhance the general outlook for kids with CHD, healthy communication with pediatricians and other front line health workforce are necessary . Fruitful discussions with health policy makers is critical in order that extra sources are allotted for kids with CHD – at primary, secondary and tertiary levels [2].

Deficiency of the atrial septum, which lets in shunting of blood among the two atria is Atrial Septal Defect (ASD) . It is one of the maximum common congenital coronary heart defects [3] happening in as much as 10% of all congenital cardiac disfigurement [2] and, together with bicuspid aortic valve, is the most regularly diagnosed congenital coronary heart disorder in adulthood. Most children with ASD are diagnosed through incidental detection of a cardiac murmur through the pediatrician [4].

Artificial Intelligence(AI) [5] is a wide term that covers any computer program (algorithms and models) that mimics human common sense and intelligence. Deep learning (additionally referred to as deep structured learning) is a part of a broader family of machine learning techniques primarily based totally on artificial neural networks. In deep learning [5], a computer model

learns to carry out classification tasks immediately from images, text, or sound. Using a huge set of labeled data and neural network architectures that comprise many layers, the models are trained. Developing an efficient deep learning model for the identification of ASD might be extremely helpful for the gain of sufferers and sonographers. Here a computer model is made to carry out identification venture directly from images.

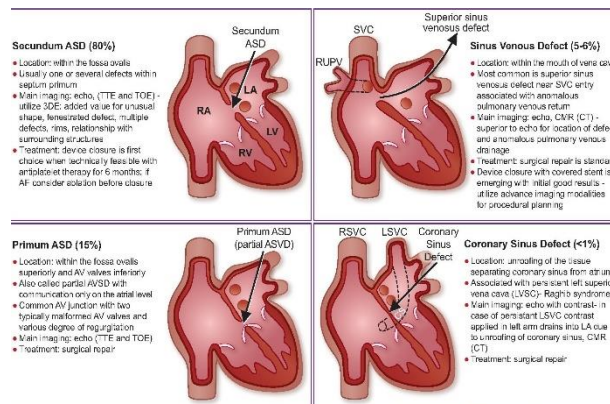
Motivated through this consideration, the contribution of this paper is to analyze the deep learning tactics carried out for figuring out ASD. The aim is to offer an perception into ASD, the techniques for figuring out it and the application of deep learning models for distinguishing the defect.

ATRIAL SEPTAL DEFECT

The human heart is a muscular organ that is accountable for correctly receiving and pumping blood. Since the body's tissues depend on the blood to hold nourishment (oxygen, glucose) and put off waste products (carbon dioxide), right blood flow is crucial to health. The cardiovascular system (coronary heart, blood vessels) carries separate circulatory systems - venous (right) and arterial (left) [6], below ordinary conditions.

The inner anatomy of heart uncovers 4 chambers. The top chambers (atria) are gathering chambers and the 2 lower chambers (ventricles) are more potent and that they pump blood. The right atrium gather blood from body that is deoxygenated and right ventricle pump it to the lungs. The left atrium gather blood from the lungs that is oxygenated and the left ventricle pump it throughout the body [6]. A set of 4 valves manages the only way flow of blood via the heart.

Figure 1 : The different morphological types of ASD [7]



In fetus, lungs do not yet achieve the feature of oxygenating the blood as in adults. Placenta is the provider of oxygen to fetus. Unlike grownup heart, in fetus, the oxygenated blood mixes with deoxygenated blood and collects within the right atrium. Since lungs require very little of this blood, the fetus has 3 specific capabilities that establish the shunting of blood from right side of the heart to left side [6].

The first component in fetal heart is foramen ovale, that is a valve blanketed by flaps that stops the regurgitation of blood, within the inter atrial septum and it's far a passage of blood to flow from the right atrium to left. The second aspect is the ligament of inferior vena cava, that's a massive vein that contains the deoxygenated blood and functions in fetal flow and the third characteristic is the manner for oxygenated blood [6].

A wedge of tissue, that is the primary partition, referred to as the septum primum, extends inferiorly, among three and four weeks of fetal improvement and is produced by the depressed roof of the atrium. The crescent-fashioned septum reaches the ground and hence keeping apart the right and left atria and hence it forms a foramen alongside its free edge, ostium primum ("first mouth/opening"), during the 5th week. Towards the end of the 6th week, the developing edge of the septum primum reduces the ostium primum to nothing. The septum primum grows the perforations simultaneously, that integrates to shape a new foramen the ostium secundum ("second opening"). Thus, a new channel for right-to-left blood flow opens before the old one shuts. Unitedly this, the septum secundum ("second partition") that is a second crescent-fashioned wedge of tissue, develops

from the roof of the atrium. It is located along the septum primum at the side of the right atrium. The secundum is thick and muscular because it grows posteroinferiorly, in contrast to the septum primum. It sincerely extends to the floor of the right atrium and leaves a hollow withinside the inferior portion, the foramen ovale. There might be the shunting of blood all through the rest of fetal development, from the right to the left atrium to pump out of the heart via the aortic artery. This shunt closes at birth due to the crusty dilation of the pulmonary vasculature united with the loss of flow via the umbilical vein [6].

The left-to-right atrial flow is allowed by an atrial septal defect, after the septum primum and septum secundum are pressed collectively at birth, if the septum secundum is just too short to cover the ostium secundum completely. Atrial septal defects (ASD) make up the 1/3 most common kind of congenital heart disease . Even with big shunts[4], maximum sufferers stay asymptomatic all through their childhood. The unique morphological kinds of ASD [7] based largely on their location are as shown in Figure. 1

METHODS FOR IDENTIFICATION OF ASD

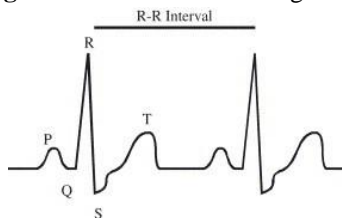
Medical image segmentation intents to make anatomical or pathological structures changes in more clear in images; it regularly performs a vital in computer aided diagnosis. The improvement and developing popularity of scientific imaging equipments, which encompass X-ray, Computed Tomography (CT), Magnetic Resonance Imaging (MRI) and ultrasound have turn out to be 4 important image assisted means to assist clinicians diagnose diseases, to estimate prognosis, and to devise operations in medical institutions. To resource the clinicians make correct diagnosis, it is vital to segment some important items in medical images and extract features from the segmented areas [5].

Cardiac Murmur : Most kids with ASD are recognised through incidental detection of a cardiac murmur through the pediatrician. Hardly an infant with ASD may present with failure to thrive, feeding difficulties, breathlessness or recurrent lower respiratory infections [4]. A ordinary first heart sound and a extensive and stuck second sound establishes the classical auscultatory findings in massive ASD. The ordinary break up of the second sound is commonly nicely audible, in wholesome young children and can be exaggerated and continual withinside the recumbent position, which every so often ends in the notion of an ASD.

Chest X-Ray : X-ray radiography is the most frequently available strategies that may be applied for the detection and analysis of many diseases. A big quantity of radiographic images and reports are available in hospital records across the world. Enlargement of the right heart chambers is an implication of hemodynamically considerable shunt in ASD [4].

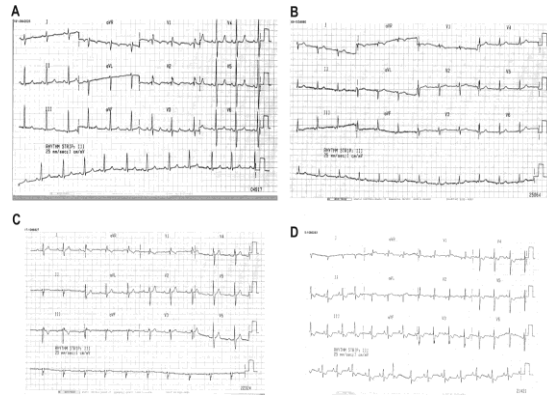
Electrocardiography (ECG): Electrocardiogram (ECG) is the transthoracic perception of the electric activity of the heart over a length of time [8]. An perfect ECG sign is as depicted in the Figure. 2. The complexes P, QRS and T are present in the trace of the signal and that they constitute one heartbeat. The period of the pulse is notated by the interval R-R. Absence of sinus arrhythmia is a consistent factor of ASD. While unaccomplished right bundle branch block is a typically mentioned in ASD, the span of the QRS has a tendency to be more with growing proper ventricular volume encumber.

Figure 2 The normal ECG signal [8]

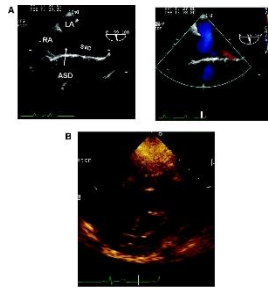


Right atrial enlargement withinside the affected person is regularly mentioned by subtle peaking of 'P' waves with rarely any increase in its amplitude. Right axis deviation of the QRS typically notates the presence of large pulmonary high blood pressure and occasionally pulmonary vascular disease [9]. The importance of electrocardiographic findings withinside the diagnosis of atrial septal disorder is established by Nermin Bayar et al. [10]. Ostium secundum ASD, Sinus venosus ASD, Ostium primum ASD and Eisenmenger ASD are as shown by the lines A, B, C and D respectively in Figure. 3

Figure 3 The electrocardiographic findings for recognising the atrial septal defect [11]



Echocardiography : An echocardiogram (echo) is a graphic blueprint of the heart's movement. Using an echo test, ultrasound, which are high-frequency sound waves, from a hand held wand located on chest furnishes the images of the heart's valves and chambers, which aids the sonographer to assess the pumping movement of the heart. **Figure 4** Recognising ASD from echo [13]



Echo is frequently combined with Doppler ultrasound and colour Doppler to grade blood flow across the heart's valves [1]. Transthoracic echocardiography is the primary modality used for the scrutiny and depiction of ASD. Multiple perspectives ought to be used to delineate the size, form and role of the ASD and its affiliation with adjoining cardiac structures [10]. Among the imaging modalities, Transesophageal echocardiography (TEE) and intracardiac echocardiography are properly advocated [12].

Itzhak Kronzon et al. [13] compared the value of transthoracic (TTE) and transesophageal (TOE) echocardiography within the estimation of diverse kinds of ASD in adults. TTE is the first-line imaging modality imparting a genuine diagnosis, shunt quantification, and computation of haemodynamic consequences, together with pulmonary hypertension, for almost all of adult sufferers with ASD [7]. TOE is needed for specific estimation of ASD before or all through transcatheter or surgical closure, imparting meticulous quantification of disorder length and morphology. It is as shown in Figure 4.

Cardiac Catheterization : Cardiac catheterization is a conduct wherein a thin, bendy tube (catheter) is guided via a blood vessel to the heart to research or deal with positive heart conditions. While an invasive catheterization isn't demanded for the analysis of ASD, cardiac catheterization nevertheless stays the gold trendy for the estimation of shunt [14].

Magnetic resonance imaging (MRI): Magnetic resonance imaging (MRI) is a clinical imaging method that utilises a magnetic area and computer-generated radio waves to create specific images of the organs and tissues [15]. Efficient estimation of the shunt and its effect at the shape and characteristic of heart may be analysed the usage of MRI.

Computerized tomography (CT): CT experiment associates a sequence of X-ray images taken from exceptional angles across the body and does the processing using computer to generate cross-sectional images (slices) of the bones, blood vessels and smooth tissues inside the body. CT experiment images offer greater complete facts than simple X-rays [15]. CT experiment can also provide the shunt estimation of ASD.

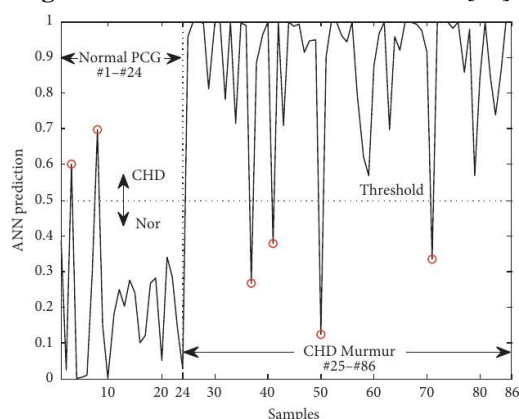
DEEP LEARNING FOR THE RECOGNITION OF ASD

Jiaming Wang et al. expose the wise analysis of pediatric murmurs because of congenital heart disease (CHD) [16]. Phonocardiogram (PCG) signals have been recorded and a segmentation approach based at the discrete wavelet transform [17] blended with Hadamard product was applied to come across the primary and the second one heart sounds from the signal. The accuracy turned into 93% , with sensitivity, and specificity of diagnosis for heart murmurs being 93.5%, and 91.7%, respectively. Eventually, a technique of intelligent diagnosis of pediatric CHD murmurs is advanced successfully and may be hired for on line screening of CHD in children. For a nonprofessional volunteer who records PCG signal by setting an digital stethoscope in another position, the approach can be inappropriate. The denoising approach used turned into not capable of rule out robust noises coming from children crying and transferring all through the recording and the output information in the prediction have been risky because the mild, moderate, and intense murmurs have been now no longer notified. The outcomes are as shown in Figure 5.

In deep learning, convolutional neural networks (CNN) strongly gain hierarchical feature illustration of images. As CNNs employed for feature learning are insensitive to image noise, blur, contrast, etc., they fetch brilliant segmentation results. For medical image segmentation tasks, supervised learning is the most stuck on method [5]. Ronneberger et al.[18] proposed the U-Net, that is the primary high impact encoder-decoder shape and has been notably used for medical image segmentation.

In the last 20 years, the mortality because of CHD has halved in excessive income countries (HICs) while low and middle income nations (LMICs) have visible a upward thrust in disability and death . Scaling up surgical care in those nations can reduce down congenital heart disorder associated deaths by 58% [19]. However, set off identity of sufferers is essential to make sure of the advanced outputs. Machine learning models which includes neural networks have the capacity to apprehend congenital heart disorder perfectly with out the want for skilled personnel. The diverseness of the diagnostic techniques used to teach those models and the diversification of the CHD reputation blanketed among the research is a chief constraint. [20].

Figure 5 The result of PCG classification. [16]



Yar Muhammad et al. [21] evolved an intelligent predictive device based on contemporary machine learning algorithms for the prediction and analysis of heart disorder. The accurate prediction of heart disorder can prevent lifestyles threats while an incorrect one can show to be deadly at the same time. The paper focusses at the experimental outcomes of various contemporary classification algorithms. The overall performance of all used type models that consists of K-Nearest Neighbors (KNN), Decision Tree (DT), Extra- Tree Classifier (ETC), Random Forest (RF), Support Vector Machine (SVM), Logistic Regression (LR), Naïve Bayes (NB), Artificial Neural Network (ANN), Adaboost (AB), and Gradient Boosting (GB) together with complete feature space is evaluated first . The 4 feature selection algorithms (FSA), which consists of, Fast Correlation-Based Filter (FCBF), Minimal Redundancy Maximal Relevance (mRMR), Least Absolute Shrinkage and Selection Operator (LASSO), and Relief are carried out to pick out the critical and excessive version capabilities from feature area. For measuring the performances of the classification models, various overall performance assessment metrics are implemented . An Intelligent Hybrid Framework became evolved for the prediction of heart disorder as depicted in the block diagram Figure. 6.

Different machine learning algorithms and deep learning and have been carried out to examine the outcomes and evaluation of the UCI Machine Learning Heart Disease dataset by Rohit Bharti et al. [22]. An accuracy of 94.2% accuracy changed into acquired through the usage of deep learning approach. It is as shown in Table 1 [22].

Magnetic resonance imaging (MRI) of the heart lets in both planar and volumetric evaluation of the cardiac anatomy, and it is able to be efficaciously employed for the identification of atrial septal defect. Yu Lu et. al. [23] devised a variation of the U-Net structure Fig. 7, that's broadly utilized in deep learning, to section the right atrium in images obtained the use of MRI from ASD patients. The proposed technique gives better accuracy segmentation .The primary trouble with present encoder–decoder networks is that the pass connection and the encoder–decoder course cannot jointly hold information and semantic information. Along with high-resolution semantic information, residual and dense connections, a extracted with the aid of using a deep monitoring mechanism also can be explored

Figure 6 An Intelligent Hybrid Framework for the prediction of heart disease. [21]

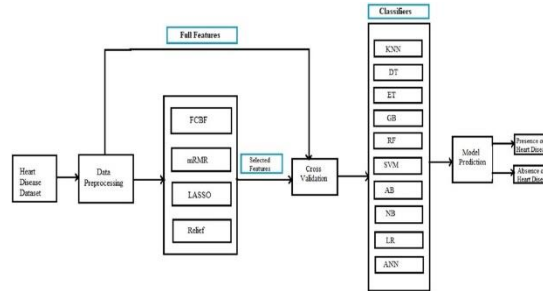


Table 1 Comparison of performance parameters of classifiers [22]

Types of classifiers	Percentage of accuracy	Specificity	Sensitivity
Logistic regression	83.3	82.3	86.3
K neighbours	84.8	77.7	85.0
SVM	83.2	78.7	78.2
Random forest	80.3	78.7	78.2
Decision tree	82.3	78.9	78.5
DL	94.2	83.1	82.3

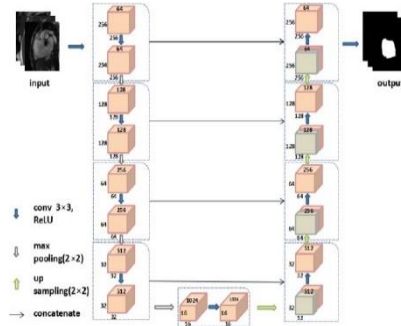
The heart murmur that is allied with atrial septal defects is regularly faint and may hence only be detected by chance. Although ECG examination can activate diagnoses, popularity of particular findings stays a chief challenge. Hiroki Mori et. al. [24] established progressed diagnostic accuracy found out by incorporating a proposed deep learning model, comprising a convolutional neural network (CNN) and long short-term memory (LSTM), along side ECGs [25] for figuring out ASD. They used a deep learning model comprising a CNN and LTSMs [26]. The deep learning model results supplied the accuracy of 0.81 having sensitivity of 0.76, specificity of 0.96 with the high quality predictive price of 0.88, and F1 rating of 0.81. In growing the model primary boundaries had been encountered. The first being, the extent of images used for deep studying (DL) became rather small and so the observe may also comprise bias; the priming effect and Hawthorne impact have to be considered in the physicians’ tests [19] [27]. This may also have yielded better false positive and true positive ratios than if ASD had now no longer been said because the sickness being doubtlessly identified. The diagnostic quality of the proposed deep learning ECG approach ought to remain subtle for applications in medical pre-examination ECG screening, if these boundaries are addressed in further work.

Echocardiography utilises ultrasound technology to seize high temporal and spatial resolution images of the heart and its surrounding structures, and is the most frequently used imaging modality in cardiovascular medicine. By the usage of CNN on

a huge new dataset. Amirata Ghorbani et al. supplied deep learning interpretation of echocardiograms [28]. Deep learning applied to echocardiography can point out nearby cardiac structures, estimate cardiac function, and anticipates systemic phenotypes which modifies cardiovascular risk however now no longer easily identifiable to human interpretation. The proposed deep learning model, EchoNet, accurately acknowledged the presence of pacemaker leads, enlarged left atrium, left ventricular hypertrophy, left ventricular end systolic and diastolic volumes and ejection fraction along with the prediction of systemic phenotypes of age, sex, weight, and height. Interpretation evaluation endorses that EchoNet suggests convenient interest to key cardiac structures while appearing human-explainable tasks and features hypothesis-generating regions of interest while figuring out systemic phenotypes that is difficult for human interpretation.

Authentic screening for septal defects is crucial for assisting radiologists' interpretative work. Siti Nurmaini et. at. proposed the accurate detection of septal defects with fetal ultrasonography images using deep learning [29].

Figure 7 Architecture of proposed U-Net variant for atrium segmentation [23]

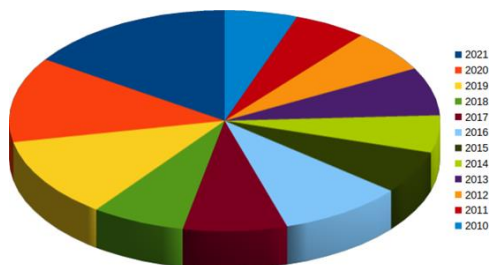


The fetal heart may encompass multiple objects, including the atria, ventricles, aorta and valves. Besides, blurry boundaries (shadows) or a loss of consistency in the acquisition ultrasonography can cause extensive variations. This study used Mask-RCNN (MRCNN) [30] to address fetal ultrasonography images and appoint it to come across and segment defects in heart partitions with more than one objects. The proposed MRCNN model gains higher overall performance in multiclass detection of the heart chamber, with 97.59% for the right atrium, for the left atrium it is 99.67% and for the left ventricle 86.17%, 98.83% for the right ventricle, and 99.97% for the aorta. The proposed model offer dependable detection of septal defects, inclusive of defects withinside the atria, ventricles, or both. All results were tested by experts to make certain the suitable achievement of hole detection. A acquainted problem having the septal illness dataset is the ground truth consists of a very limited and strict dataset.

Transthoracic echocardiography [31] represents the mainstay withinside the routine imaging estimation of sufferers with congenital heart disorder. Gerhard Paul Diller et al. aimed to analyze the utility of deep learning algorithms in de-noising transthoracic echocardiographic images and removing acoustic shadowing artefacts mainly in sufferers with congenital heart disorder (CHD) [32]. Also, the overall performance of DL algorithms that is educated on CHD samples was compared to models trained absolutely on structurally normal hearts. Deep neural network based autoencoders [33] had been constructed for denoising and elimination of acoustic shadowing artefacts based on routine echocardiographic apical 4-chamber perspectives and overall performance was assessed by visible evaluation and cross entropy is evaluated. The study establishes the capability of autoencoders for denoising and artefact removal in sufferers with congenital heart disorder and structurally normal hearts. The models trained entirely on samples from structurally normal hearts perform reasonably in CHD and the statistics illustrates the value of dedicated image augmentation systems trained particularly on CHD samples..

The statistics of relevant studies articles posted in the recognition of atrial septal defect by employing deep learning in the imaging modalities is depicted in Figure 8. Major articles have been published withinside the peroid 2019 - 2021. The advent of efficient deep learning algorithms advised the research in ASD detection.

Figure 8 Statistics of research articles



CONCLUSION

Deep learning has demonstrated tremendous capacity in recognising ASD. These techniques have proved their performance as effective gear in dealing with defect detection within the areas of preprocessing, characteristic extraction, feature selection, classification, and additionally in clustering. DL may be integrated in all of the modalities used for the recognition of the ASD. The overall performance of various diagnostic strategies have been mentioned in terms of the defect detection accuracy and algorithm parameters. Echocardiography has been recognized as very powerful for the recognition of ASD. MRCNN model furnishes higher overall performance in detecting the cardiac chambers. The deep learning model Echonet offers higher interpretation of enlarged chambers. As a summary, we are able to conclude that an efficient deep learning model for the identification of ASD could be extremely advantageous for the benefit of sufferers and the sonographers.

REFERENCES

1. Lindsey D. Allan. Echocardiographic detection of congenital heart disease in the fetus: Present and future. *British heart journal*, 74(2):103, 1995.
2. Margarita Brida, Massimo Chessa, David Celermajer, Wei Li, Tal Geva, Paul Khairy, Massimo Griselli, Helmut Baumgartner, and Michael A Gatzoulis. Atrial septal defect in adulthood: a new paradigm for congenital heart disease. *European Heart Journal*, 2021.
3. David S Celermajer. Atrial septal defects: Even simple congenital heart diseases can be complicated. *European Heart Journal*, 39(12):999–1001, March 2018.
4. Arun Gopalakrishnan. Atrial Septal Defect - Systematic Assessment Prior to Device Closure. *Kerala Journal of Cardiology*, 1:61–68, September 2017.
5. Karen López-Linares Román, María Inmaculada García Ocaña, Nerea Lete Urzelai, Miguel Ángel González Ballester, and Iván Macía Oliver. Medical image segmentation using deep learning. In *Deep Learning in Healthcare*, pages 17–31. Springer, 2020.
6. Anthony J Weinhaus and Kenneth Roberts. *Anatomy of the Human Heart*. Springer, page 29, 2005.
7. Elena Surkova, Sonya V Babu-Narayan, Thomas Semple, Siew Yen Ho, and Wei Li. International journal of cardiology congenital heart disease the achd multi-modality imaging series: Imaging of atrial septal defects in adulthood. *International Journal of Cardiology Congenital Heart Disease*, page 100188, 2021.
8. C. L. Van Velzen, S. A. Clur, M. E. B. Rijlaarsdam, C. J. Bax, E. Pajkrt, M. W. Heymans, M. N. Bekker, J. Hruda, C. J. M. De Groot, and N. A. Blom. Prenatal detection of congenital heart disease—results of a national screening programme. *BJOG: An International Journal of Obstetrics & Gynaecology*, 123(3):400–407, 2016.
9. Constantina Aggeli, Eleftherios Tsiamis, and Costas Tsioufis. The significance of shunt directionality of iatrogenic atrial septal defect in different clinical scenarios: Concerns on management. *International Journal Of Cardiovascular Imaging*, 2021.
10. Nermin Bayar, S. akir Arslan, Erkan Köklü, Göksel Cagirci, Serkan Cay, Zehra Erkal, Raif Umur Ayoglu, and Selçuk Küçükseymen. The importance of electrocardiographic findings in the diagnosis of atrial septal defect. *National Library of Medicine*, page 6, 2015.
11. Gary Webb and Michael A Gatzoulis. Atrial septal defects in the adult: recent progress and overview. *Circulation*, 114(15):1645–1653, 2006.
12. Gail E Peterson, M Elizabeth Brickner, and Sharon C Reimold. Transesophageal echocardiography: clinical indications and applications. *Circulation*, 107(19):2398–2402, 2003.
13. Itzhak Kronzon, Paul A. Tunick, Robin S. Freedberg, Naresh Trehan, Barry P. Rosenzweig, and Matthew E. Schwinger. Transesophageal echocardiography is superior to transthoracic echocardiography in the diagnosis of sinus venosus atrial septal defect. *Journal of the American College of Cardiology*, 17(2):537–542, February 1991.
14. Karim A. Diab, Younes Boujemline, and Ziyad M. Hijazi. Update on shunt closure in neonates and infants. *Expert Review Of Cardiovascular Therapy*, 2021.
15. Nazzareno Galiè, Marc Humbert, Jean-Luc Vachiery, Simon Gibbs, Irene Lang, Adam Torbicki, Gérald Simonneau, Andrew Peacock, Anton Vonk Noordegraaf, Maurice Beghetti, Ardeschir Ghofrani, Miguel Angel Gomez Sanchez, Georg Hansmann, Walter Klepetko, Patrizio Lancellotti, Marco Matucci, Theresa McDonagh, Luc A. Pierard, Pedro T. Trindade, Maurizio Zompatori, and Marius Hoeper. 2015 ESC/ERS Guidelines for the diagnosis and treatment of pulmonary hypertension: The Joint Task Force for the Diagnosis and Treatment of Pulmonary Hypertension of the European Society of Cardiology (ESC) and the European Respiratory Society (ERS) Endorsed by: Association for European Paediatric and Congenital Cardiology (AEPC), International Society for Heart and Lung Transplantation (ISHLT). *European Respiratory Journal*, 46(4):903–975, October 2015.
16. Jiaming Wang, Tao You, Kang Yi, Yaqin Gong, Qilian Xie, Fei Qu, Bangzhou Wang, and Zhaoming He. Intelligent Diagnosis of Heart Murmurs in Children with Congenital Heart Disease. *Journal of Healthcare Engineering*, 2020:1–9, 2020.
17. Andrey Osadchiy, Aleksandr Kamenev, Vladimir Saharov, and Sergei Chernyi. Signal processing algorithm based on discrete wavelet transform. *Designs*, 5(3):41, 2021.

18. Olaf Ronneberger, Philipp Fischer, and Thomas Brox. U-net: Convolutional networks for biomedical image segmentation. In Nassir Navab, Joachim Hornegger, William M. Wells, and Alejandro F. Frangi, editors, *Medical Image Computing and Computer-Assisted Intervention – MICCAI 2015*, pages 234–241, Cham, 2015. Springer International Publishing.
19. Árni Kristjánsson and Árni Gunnar Ásgeirsson. Attentional priming: recent insights and current controversies. *Current opinion in psychology*, 29:71–75, 2018.
20. Zahra Hoodbhoy, Uswa Jiwani, Saima Sattar, Rehana Salam, Babar Hasan, and Jai K. Das. Diagnostic Accuracy of Machine Learning Models to Identify Congenital Heart Disease: A Meta-Analysis. *Frontiers in Artificial Intelligence*, 4:97, 2021.
21. Yar Muhammad, Muhammad Tahir, Maqsood Hayat, and Kil To Chong. Early and accurate detection and diagnosis of heart disease using intelligent computational model. *Scientific Reports*, 10(1):19747, December 2020.
22. Rohit Bharti, Aditya Khamparia, Mohammad Shabaz, Gaurav Dhiman, Sagar Pande, and Parneet Singh. Prediction of Heart Disease Using a Combination of Machine Learning and Deep Learning. *Computational Intelligence and Neuroscience*, 2021:1–11, July 2021.
23. Yu Lu, Xianghua Fu, Xiaoqing Li, and Yingjian Qi. Cardiac Chamber Segmentation Using Deep Learning on Magnetic Resonance Images from Patients Before and After Atrial Septal Occlusion Surgery. In *2020 42nd Annual International Conference of the IEEE Engineering in Medicine & Biology Society (EMBC)*, pages 1211–1216, Montreal, QC, Canada, July 2020. IEEE.
24. Alex Sherstinsky. Fundamentals of recurrent neural network (rnn) and long short-term memory (lstm) network. *Physica D: Nonlinear Phenomena*, 404:132306, Mar 2020.
25. Hiroki Mori, Kei Inai, Hisashi Sugiyama, and Yoshihiro Muragaki. Diagnosing Atrial Septal Defect from Electrocardiogram with Deep Learning. *Pediatric Cardiology*, 42(6):1379–1387, August 2021.
26. Indra Den Bakker. *Python Deep Learning Cookbook: Over 75 Practical Recipes on Neural Network Modeling, Reinforcement Learning, and Transfer Learning Using Python*. Packt Publishing, Birmingham, UK, 2017.
27. Jim McCambridge, John Witton, and Diana R Elbourne. Systematic review of the Hawthorne effect: new concepts are needed to study research participation effects. *Journal of clinical epidemiology*, 67(3):267–277, 2014.
28. Amirata Ghorbani, David Ouyang, Abubakar Abid, Bryan He, Jonathan H. Chen, Robert A. Harrington, David H. Liang, Euan A. Ashley, and James Y. Zou. Deep learning interpretation of echocardiograms. *npj Digital Medicine*, 3(1):10, December 2020.
29. Siti Nurmaini, Muhammad Naufal Rachmatullah, Ade Iriani Sapitri, Annisa Darmawahyuni, Adithia Jovandy, Firdaus Firdaus, Bambang Tutuko, and Rossi Passarella. Accurate Detection of Septal Defects With Fetal Ultrasonography Images Using Deep Learning-Based Multiclass Instance Segmentation. *IEEE Access*, 8:196160–196174, 2020.
30. Philippe Burlina. Mrcnn: A stateful fast r-cnn. In *2016 23rd International Conference on Pattern Recognition (ICPR)*, pages 3518–3523, 2016.
31. Vishal Chandra, Vinay Singh, and Prattay Guha Sarkar. A survey on the role of deep learning in 2d transthoracic echocardiography. *Int J Sci Technol Res*, 9:7060–5, 2020.
32. Gerhard-Paul Diller, Astrid E. Lammers, Sonya Babu-Narayan, Wei Li, Robert M. Radke, Helmut Baumgartner, Michael A. Gatzoulis, and Stefan Orwat. Denoising and artefact removal for transthoracic echocardiographic imaging in congenital heart disease: Utility of diagnosis specific deep learning algorithms. *The International Journal of Cardiovascular Imaging*, 35(12):2189–2196, December 2019.
33. Wei Wang, Yan Huang, Yizhou Wang, and Liang Wang. Generalized autoencoder: A neural network framework for dimensionality reduction. In *2014 IEEE Conference on Computer Vision and Pattern Recognition Workshops*, pages 496–503, 2014.