

Case Report on Choroid Plexus Papilloma

Rajnandini Bawankar¹, Ruchira Ankar², Vaishali Tembhe³, Aniket Pathade⁴

¹Final year Basic Bsc student Smt. Radhikabai Meghe Memorial College of Nursing Sawangi Meghe Wardha.

^{2,3}Department of Medical-Surgical Nursing, Smt. Radhikabai Meghe Memorial College of Nursing, Datta Meghe Institute of Medical Sciences, Sawangi, Wardha, Maharashtra.

⁴Research Scientist, Jawaharlal Nehru Medical College, Datta Meghe Institute of Medical Sciences, Sawangi, Wardha, Maharashtra.

Abstract

Choroid Plexus Papillomas (CPPs) is also known as benign but rare central nervous system(CNS) which affect the tufts of villi that make the ventricular system choroid plexus, which is responsible for production of cerebrospinal fluid(CSF). They make up between 0.5-1% in adult and 3-4% of paediatric group. Here we are introducing 11-year-old- female who visited with her parents in paediatric outpatient unit with the complaints of headache in the frontal region and backregion. She had 4-5 episodes of vomiting in previous week, she also developed the double vision since last 2 days. The patient underwent Magnetic Resonance Imaging of the brain and found the evidence of papilla enema in both eyes. Patient went to eye department for Vitreo-retained(VR) surgery. After that client was shifted to ward for the further management where she was administered the appropriate paediatric dose of antiedema and antiepileptic medication and other supportive measures. After treatment, the patient's condition was improved than before. Symptoms such as blurred vision relieved after surgery. These tumours rarely develop in children's third ventricles, fourth ventricles or CP angle.

Keywords: choroid plexus Papillomas, extra-ventricular, lateral ventricle papilloma.

INTRODUCTION

A category of benign tumours called choroid plexus Papillomas (CPPs) develops from the choroid plexus, a structure consisting of tufts of villi located within the ventricular system that secretes cerebrospinal fluid (CSF). They make up between 0.5-1% of adult and 3-4% of kids. (1) The third ventricle and the temporal horn are the two locations where CPP occurs least frequently.

Only 4% of CPPS in children under the age of five include the third ventricle, 16% involve the fourth ventricle, and nearly 80% begin in the lateral ventricle. These tumours have been classified as benign histologically, neuroectodermal in origin, and WHO grade I. Complete or gross complete removal of these tumours frequently cures the patient and virtually eliminates the risk of recurrence. (2)

These tumours present unique therapeutic concerns primarily because of their young age at presentation, high vascularity, and potential for CSF hypersecretion, among other distinctive characteristics. (3)

The most frequent locations in children and adults, respectively, are the atrium of the lateral ventricle and the fourth ventricle. The third ventricle, the cerebellopontine (CP) angle, the cerebral parenchyma, the cerebellum, and other sites are rare. (4) The atrium of lateral ventricle in children and fourth ventricle in adult are most frequent location. Only a few occurrence have been described for the third ventricle, cerebellopontine(CP)angle and cerebral parenchyma, which are all uncommon location. (5)

In the majority of instances, children arrive with elevated intracranial pressure (ICP). The location of the lesion affects other clinical characteristics. The preferred course of treatment is surgical removal, and specific surgical techniques must be used depending on the location, size, and extent of the lesion. (6)

Address for correspondence: Rajnandini Bawankar
Final year Basic Bsc student Smt. Radhikabai Meghe Memorial College of
Nursing Sawangi Meghe Wardha.

This is an open access journal, and articles are distributed under the terms of the Creative Commons Attribution-NonCommercial-ShareAlike 4.0 License, which allows others to remix, tweak, and build upon the work non-commercially, as long as appropriate credit is given and the new creations are licensed under the identical terms.

For reprints contact: pnrjournal@gmail.com

How to cite this article: Rajnandini Bawankar, Ruchira Ankar, Vaishali Tembhe, Aniket Pathade, Case Report on Choroid Plexus Papilloma, J PHARM NEGATIVE RESULTS 2022;13: 941-943.

Access this article online

Quick Response Code:



Website:
www.pnrjournal.com

DOI:
10.47750/pnr.2022.13.03.146

Case presentation:

A 11-year-old girl visited to general practitioner in her locality with the complaint of headache since 15 days, nausea, vomiting of 4 to 5 episode from 7 days. Doctor prescribed antiemetic medication and some analgesic. The pain was subsided and vomiting also reduced.

After some days she got sign of blurred vision with the symptoms of nausea, vomiting and headache hence her parents took her to paediatric outpatient department. She has under gone through the radiological investigation Magnetic resonance imaging (MRI), blood investigation and ophthalmological examination. In MRI there is irregular soft tissue density lesion showing avid enhancement noted in the posterior third ventricle region with CSF cleft appearing heterogeneously on T2W1/FLAIR hypo intense on T1W1 and showing restriction on DWI and low signal on ADC and blooming on GRE. The child has under gone through the Vitreo-retained (VR) surgery. And she was treated with Intravenous fluid, Inj. metronidazole 100mL, Inj. Pantoprazole 40mg once a day, inj. Tramadol in 100ml, Inj. Emset 4mg post operatively.

Some lesion was visible on non-contrast computed tomography (CT). The ophthalmological call was done. After investigation the doctor suggested for the operation to recover the eye. Therefore the anaesthesia was administered to the client according to the requirement, further the surgery has performed. Client ventriculo-peritoneal (VP) shunt was carried out, then a conclusive operation. In the seated position, a supracerebellar infratentorial approach was made. The tumour was vascular, soft to firm, friable, reddish, and linked to the choroidal arteries by a single pedicle. Early security of the artery feeder allowed for a successful en bloc removal. Postoperative imaging revealed no residual tumour, and the child's recovery from surgery was outstanding. After treatment, the patient's condition improves. Condition of the patient were improved after surgery hence patient was discharged with the advice to follow up after 3 weeks.

Discussion:-

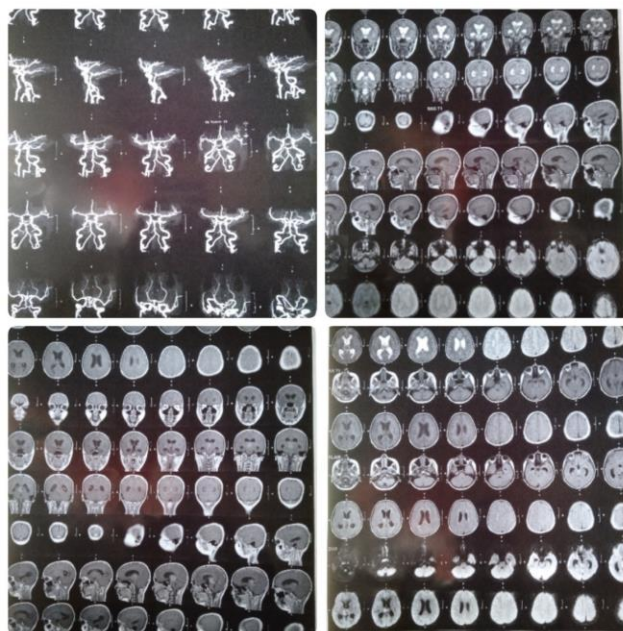
CPP are being, infrequent central nervous system tumour. Overproduction of cerebrospinal fluid (CSF), which arise from the choroid plexus boarding the ventricles and is derived from the neuroectoderm, is the defining feature of these malignancies. In most of the cases, hydrocephalus is present. The cases of this include excessive CSF production, direct tumour obstruction of CSF routes, recurrent microhaemorrhages resulting in arachnoid adhesions and increase CSF protein contraction. (7-15)

In children lateral ventricle and adults fourth ventricles, they are most frequently seen in the atrium. (8) These have been a few report of fourth ventricular CPP in children, with an incidence of 10-20%, however they are uncommon in area like the CP angle and posterior third ventricle. CPPs are well-

defined soft, grayish-red cauliflower-like masses with noticeable peripheral lobulations and focal grittier patches as a result of calcification. There may be some haemorrhaging and cystic degeneration in some regions. The major blood supply for the choroid plexus tumours in the lateral ventricle is formed by the anterior choroidal artery, lateral posterior choroidal artery, and medial posterior choroidal artery. The posterior inferior cerebellar artery's choroidal branches typically supply fourth ventricle choroid plexus tumours. (16-22)

Most of the time, a vascular pedicle connects the tumours to the choroid plexus. While tumours of the third ventricle are generally linked to its roof, cancers of the lateral ventricles most frequently arise in the trigone region of the choroid plexus. The CPPs are joined to the posterior medullary velum in the fourth ventricle. (23)

Due to the pedicular connection, which allows for the free movement of the tumours inside the ventricles, there can occasionally be an acute constriction of the ventricles caused by gravity, leading to bobble head doll syndrome. In our case, the tumour also possessed a pedicular attachment that emerged from the temporal horn's choroid plexus, with the anterior choroidal artery serving as its vascular supply. (24-27)



Conclusion:-

CPP are infrequent, being tumours. These tumours are rarely develop in children in third ventricle or forth ventricle, or CP angle. The most typical manifestation is increase ICP. When there are conforming imaging finding in children, they should always be taken into account in the different diagnosis. The client came with the complaint of nausea, vomiting, headache and blurred vision. After surgical management the condition of patient was good.

REFERENCES

- Castro Castro J, Lista Martínez O, Cuevas Álvarez EC, Iglesias Meleiro JM, Pérez López C. Choroid plexus papilloma of the third ventricle. A case report. *Neurocirugia (Astur : Engl Ed)*. 2020 May-Jun;31(3):151-154. English, Spanish. doi: 10.1016/j.neucir.2019.06.003. Epub 2019 Aug 7. PMID: 31401052.
- McCrea HJ, Lara-Reyna J, Perera I, Uribe R, Chotai S, Savage N, Hersh EH, Haussner T, Souweidane MM. Colloid cysts of the third ventricle in children. *J Neurosurg Pediatr*. 2021 Apr 23;27(6):700-706. doi: 10.3171/2020.10.PEDS18458. PMID: 33892476.
- Lam KY, Lo CY, Fan ST, Luk JM. Telomerase activity in pancreatic endocrine tumours: a potential marker for malignancy. *Mol Pathol*. 2000 Jun;53(3):133-6. doi: 10.1136/mp.53.3.133. PMID: 10897332; PMCID: PMC1186919.
- Prasad GL, Mahapatra AK. Case series of choroid plexus papilloma in children at uncommon locations and review of the literature. *Surg Neurol Int*. 2015 Sep 28;6:151. doi: 10.4103/2152-7806.166167. PMID: 26500797; PMCID: PMC4596056.
- Sæhle T, Eide PK. Characteristics of intracranial pressure (ICP) waves and ICP in children with treatment-responsive hydrocephalus. *Acta Neurochir (Wien)*. 2015 Jun;157(6):1003-14. doi: 10.1007/s00701-015-2410-z. Epub 2015 Apr 14. PMID: 25870129.
- Redzic ZB, Preston JE, Duncan JA, Chodobski A, Szmydynger-Chodobska J. The choroid plexus-cerebrospinal fluid system: from development to aging. *Curr Top Dev Biol*. 2005;71:1-52. doi: 10.1016/S0070-2153(05)71001-2. PMID: 16344101.
- Scotti G, Musgrave MA, Fitz CR, Harwood-Nash DC. The isolated fourth ventricle in children: CT and clinical review of 16 cases. *AJR Am J Roentgenol*. 1980 Dec;135(6):1233-8. doi: 10.2214/ajr.135.6.1233. PMID: 6779530.
- Zagórska-Swiezy K, Litwin JA, Gorczyca J, Pityński K, Miodoński AJ. Arterial supply and venous drainage of the choroid plexus of the human lateral ventricle in the prenatal period as revealed by vascular corrosion casts and SEM. *Folia Morphol (Warsz)*. 2008 Aug;67(3):209-13. PMID: 18828104.
- Gomez DG, Potts DG. The lateral, third, and fourth ventricle choroid plexus of the dog: a structural and ultrastructural study. *Ann Neurol*. 1981 Oct;10(4):333-40. doi: 10.1002/ana.410100404. PMID: 7316486
- Chen T, Mastorakos GM, Swanson KI, Eschbacher JM, Smith KA. Temporal Horn Choroid Plexus Papilloma Presenting with Seizures in Adulthood: Clinical Case Report and Review of the Literature. *World Neurosurg*. 2019 Dec;132:403-407. doi: 10.1016/j.wneu.2019.08.201. Epub 2019 Sep 5. PMID: 31493601.
- Chalakh, S., P. Desai, and D. Rajput. "Impact of Pesticide Awareness Module (PAM) in Improving the Knowledge of Farmers Community about Pesticide Poisoning: A Pre- and Post- Intervention Study in Wardha District in Maharashtra, India." *Journal of Pharmaceutical Research International*, July 27, 2021, 160-66. <https://doi.org/10.9734/jpri/2021/v33i38B32111>.
- Chamat, Ayush, Ninad Nagrale, and Nandkishor Bankar. "COVID 19 in Geriatric Patients in Vidharbha Region." *Journal of Pharmaceutical Research International*, July 24, 2021, 245-49. <https://doi.org/10.9734/jpri/2021/v33i38A32081>.
- Chandak, Aditi Vinay, Surekha Dubey Godbole, Tanvi Rajesh Balwani, and Tanuj Sunil Patil. "An Awakening Alarm for Dental Professionals in Pandemic of Covid-19." *Journal of Evolution of Medical and Dental Sciences* 10, no. 15 (April 12, 2021): 1098-1101. <https://doi.org/10.14260/jemds/2021/235>.
- Chandak, Pooja Ghanshyam, Manoj Ghanshyamdasj, Chandak Chandak, Kajol Naresh Relan, Madhulka Chandak, Chanchal Rathi, and Aditya Patel. "Nanoparticles in Endodontics - A Review." *Journal of Evolution of Medical and Dental Sciences* 10, no. 13 (March 29, 2021): 976-82. <https://doi.org/10.14260/jemds/2021/209>.
- Chandak, Sejal, Bhushan Madke, Sugat Jawade, and Adarshlata Singh. "Hydroxyurea-Induced Azure Lunula." *Journal of Dermatology and Dermatologic Surgery* 25, no. 1 (2021): 44. https://doi.org/10.4103/jdds.jdds_14_20.
- Deshmukh, Sourabh G., Trupti Thakre, Jaya Gupta, and Rohit Waskar. "A Case Study on Management of Tinea Cruris with Classical Vaman Karma." *Journal of Pharmaceutical Research International*, June 30, 2021, 195-202. <https://doi.org/10.9734/jpri/2021/v33i33B31811>.
- Deshpande, Meghana Ajay, Sudhindra Baliga, Nilima Thosar, Nilesh Rathi, Shirramji Jyothishi, Pranjali Vilas Deulkar, and Sphurti Pramod Bane. "Evaluation of Antibacterial Efficacy of Triphala Toothwipes on Oral Streptococcus Mutans Count in Intellectually Disabled Children." *Special Care in Dentistry* 41, no. 5 (September 2021): 619-25. <https://doi.org/10.1111/scd.12597>.
- Deshpande, Shilpa Bhaskarrao, Shweta Parwe, and Milind Nisargandha. "Role of Argwadha Nitya Virechana in Madhumeha (Diabetes Mellitus-II): A Case Study." *Journal of Pharmaceutical Research International*, June 26, 2021, 170-76. <https://doi.org/10.9734/jpri/2021/v33i33B31808>.
- Devi, Akojam Nisha. "Overview of COVID-19 Pandemic: Transmission, Epidemiology and Diagnosis." *Journal of Pharmaceutical Research International*, July 23, 2021, 174-81. <https://doi.org/10.9734/jpri/2021/v33i38A32073>.
- Devi, M. Shavina. "Dietary and Immunomodulatory Measures for Boosting Immunity to Fight Covid-19." *Bioscience Biotechnology Research Communications* 14, no. 6 (June 15, 2021): 180-85. <https://doi.org/10.21786/bbrc/14.6.39>.
- Devkumar, Shreerag, Rakesh Kumar Jha, and Dhruva Hari Chandi. "Long Term Effect of COVID-19 on the Brain: Review." *Journal of Pharmaceutical Research International*, July 31, 2021, 1-4. <https://doi.org/10.9734/jpri/2021/v33i39B32173>.
- Dhage, Prasad. "Rehabilitation of Tennis Elbow (Lateral Epicondylitis) with Physical Therapy: A Case Report." *Bioscience Biotechnology Research Communications* 14, no. 6 (June 15, 2021): 81-83. <https://doi.org/10.21786/bbrc/14.6.19>.
- Dhande, Rajasbala Pradeep, Shirish V. Vaidya, Megha Manoj, Rohan Kumar Singh, and Harshith Gowda K.B. "Sternal Involvement in Anterior Mediastinal Seminoma - A Rare Presentation." *Journal of Evolution of Medical and Dental Sciences* 10, no. 23 (June 7, 2021): 1799-1802. <https://doi.org/10.14260/jemds/2021/371>.
- Dhanvijay, Roshani, and Ruchira Ankar. "Guillain-Barré Syndrome: A Rare Case Report." *Journal of Pharmaceutical Research International*, October 26, 2021, 263-67. <https://doi.org/10.9734/jpri/2021/v33i47A33012>.
- Dhanvijay, Roshani P., and Savita Pohekar. "Efficacy of Relaxation Therapy on the Breathing Pattern among Bronchial Asthma Patients." *Journal of Pharmaceutical Research International*, August 31, 2021, 55-60. <https://doi.org/10.9734/jpri/2021/v33i42B32424>.
- Dhanvijay, Roshani, and Savita Pohekar. "Assessment of Auto-Rickshaw Drivers Knowledge Regarding the Effects of Air Pollution on Health and Its Prevention." *Journal of Pharmaceutical Research International*, August 20, 2021, 20-26. <https://doi.org/10.9734/jpri/2021/v33i41B32340>.