

# EVALUATION OF INCIDENCE OF VARIOUS TYPES OF CORONOID PROCESS IN SOUTH INDIAN POPULATION.

<sup>1</sup>Padmapriya. A, <sup>2</sup>Lavanya Prathap\*, <sup>3</sup>Ganesh Lakshmanan

<sup>1</sup>Undergraduate student, Saveetha Dental college and hospitals, Saveetha institute of medical and technical sciences Saveetha university, Chennai-600077

<sup>2</sup>\*Associate Professor, Department of Anatomy Saveetha Dental college and hospitals, Saveetha institute of medical and technical sciences Saveetha university, Chennai-600077

<sup>3</sup>Senior Lecturer, Department of Anatomy Saveetha Dental college and hospitals, Saveetha institute of medical and technical sciences Saveetha university, Chennai-600077

## Abstract

**Introduction:** The mandible is the facial skeleton's largest and most strong bone. Coronoid process which is present in the mandible gives attachment to temporalis muscle. Coronoid process varies in shape and size which is used for forensic identification. The morphology of the coronoid process is due to hormonal and genetic changes. The Coronoid process acts as a perfect donor for reconstruction of orbit. Orthopantomography is a radiographic method used to visualize mandibles. It also provides a rotational view of the jaw. The aim of the study is to analyse the various shapes of the coronoid process in the South Indian population using OPG.

**Materials and methods:** The study was conducted in a private dental college. This study was classified according to gender-male and female. Different shapes of the coronoid process were analysed in the study A total of 80 sample radiographs were included in the study. The collected data was tabulated and analysed statistically using chi square test for its significance using SPSS version 2.3.

**Results:** There are different shapes of coronoid process in males and females. In our study round shaped coronoid processes were found common in males and triangular shaped coronoid processes were found common in females. Flattened shaped coronoid process on the right was found only in females.

**Conclusion:** From obtained results within the limitations of the study it can be concluded that round and triangular shape is observed to be a common occurrence and there is no significant difference found between males and females population. Future studies with live models and larger sample size should be conducted.

**Keywords:** Coronoid process; mandible; orthopantomogram; forensic identification; innovative techniques.

**DOI:** 10.47750/pnr.2022.13.S03.216

## INTRODUCTION:

The mandible is the facial skeleton's largest and most strong bone. Coronoid process which is present in the mandible gives attachment to temporalis muscle. Coronoid process varies in shape and size which is used for forensic identification. The morphology of the coronoid process is due to hormonal and genetic changes. The Coronoid process acts as a perfect donor for reconstruction of orbit. (Parveen *et al.*, 2018) The shape of the coronoid processes is due to hormonal and genetic changes. They also act as an anthropological marker for race detection. They are also used for gender identification which is not reliable. (Pradhan *et al.*, 2014) Coronoid processes are used for reconstructive purposes-maxillofacial surgery, trauma, tumours, etc. The coronoid fracture was caused due to limitation of mandible movement and swelling of the particular region. Various radiographic methods have been used to treat coronoid fractures and traumas. (Kasat and Bhuiyan, 2016)

This study plays a key role in identification of DNA matching and fingerprint analysis. Generally identification of gender was done with bone. But it is a very challenging task due to skull remnants remaining. The coronoid process of the mandible is becoming increasingly relevant as a graft material in all aspects of cranio-maxillofacial reconstruction. Due to this gender determination was done with mandibles. The shape of the coronoid process acts as an evolutionary marker used for forensic identification. Maxillofacial radiography such as orthopantomogram(OPG's) helps to identify various shapes of the coronoid process. (Srivastava *et al.*, 2016) Orthopantomography is a radiographic method used to visualize mandibles. It also provides a rotational view of the jaw. Out of all the methods OPG's were found to be cost efficient. Various invitro and invivo studies were done to

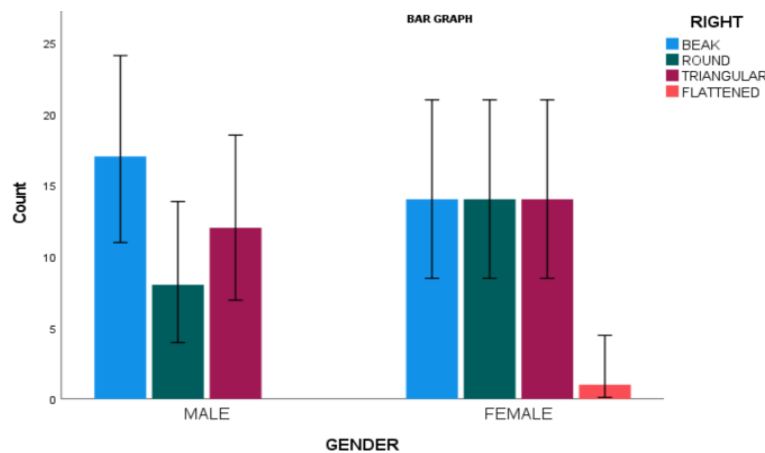
analyse the various shapes of the coronoid process in different populations of the world.(Ashwinirani *et al.*, 2016).Our team has extensive knowledge and research experience that has translate into high quality publications (Dinesh *et al.*, 2013; Krishnan and Lakshmi, 2013; Muthukrishnan and Warnakulasuriya, 2018; Sekar *et al.*, 2019; Gomathi *et al.*, 2020) (Sathivel *et al.*, 2008; Panda *et al.*, 2014; Govindaraju, Neelakantan and Gutmann, 2017; Johnson *et al.*, 2020; Saraswathi *et al.*, 2020).This present study is to analyse the various shapes of the coronoid process in the South Indian population.

**MATERIALS AND METHODS:**

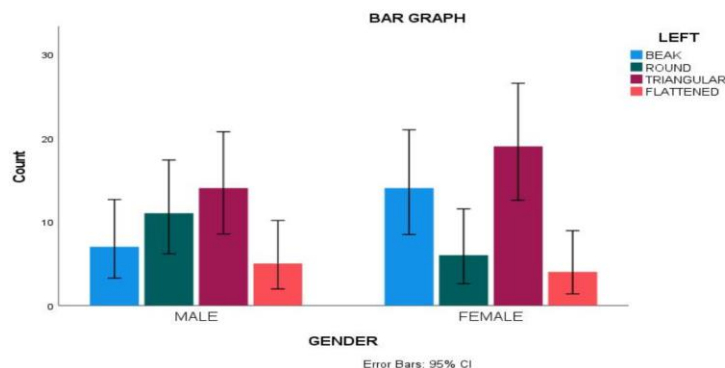
This is a retrospective study conducted in a private dental college. A total of 80 (37 males and 43 females) radiographs were taken and included in the study. This study was classified according to gender-male and female.Patients aged 10 years and above and High quality OPG's with respect to coloration and angulation were included. Exclusion criteria- Patients affected with dental and maxillofacial fractures, joint disjunction, traumas, pathological lesions around temporomandibular joints were excluded and Patients undergoing surgery or orthodontic purposes were neglected from the study. Data were analyzed statistically by SPSS 2.3. Data was set and analysed by chi square test with bar charts and cross tabs.

**RESULTS:**

This study showed various shapes of coronoid processes in males and females.. Out of 80, 37 were males and 43 were females. The most common shape of the coronoid process found in males is round shape (41.5%) whereas in females the most common shape of the coronoid process is triangular shape (40%). Flattened shaped coronoid processes were not found in the right coronoid process of males whereas found in females with 11.5%.



**Figure-1** represents the variation of right coronoid processes between genders. X-axis represents gender, Y-axis represents number of samples. The most commonly found coronoid process is round in males. Triangular and round were commonly found in females. The mean value of the right coronoid process is statistically not significant (p=0.213) between gender.



**Figure-2:** This graph represents the variation of left coronoid processes between genders. X-axis represents gender, Y-axis represents number of samples. The most commonly found coronoid process is triangular in both males and females. The mean value of the right coronoid process is statistically not significant ( $p=0.364$ ) between genders.

## DISCUSSION:

Our study showed various shapes of the coronoid process in males and females. The results showed that The most common shape of the coronoid process found in males is round whereas in females the most common shape of the coronoid process is triangular. Flattened shaped coronoid processes were not found in the right coronoid process of males whereas found in females.

Previous study was done with variations of coronoid processes among males and females. There is no variation of shapes of the coronoid process in males and females due to hormonal factors. They concluded that a triangular shaped coronoid process was commonly found followed by round shaped coronoid processes. The variation of shape of the coronoid process was not statistically significant ( $p>0.05$ ). This study said about morphological variations of coronoid processes and reconstructive surgeries such as flooring and anthropology. The structure of coronoid process is used in forensic identification and sex determination. It is also used for determination of heredity. But sex determination with shape and size of coronoid process is not reliable. (Shakya and Nagraj, 2013).

A previous research was conducted to evaluate the various options. In adult Indians, there are various types of coronoid processes on both sides, as well as to determine the viability of coronoid morphology experience in sex determination. They determined the many forms of coronoid processes in adult Indians. on both sides, as well as to test the viability of coronoid morphology experience in the occurrence of rarer forms such as double coronoid phase, subcoronoid sutures, and so on, which were not seen in the current study due to sample size limitations. (Saini *et al.*, 2011)

This study showed various shapes of coronoid processes in males and females using orthopantomogram. Orthopantomography is a radiographic method used to visualize mandibles. It also provides a rotational view of the jaw. Out of all the methods OPG's were found to be cost efficient. OPG shows different shapes of the coronoid process bilaterally which is appreciated. Previously evaluation of coronoid process and condylar process were done using CBCT (Cone Beam Computed Tomography) ; they provide transition of dental diagnosis and possess 2D (two dimensional) and 3D (three dimensional) (Al-Ghurabi and Al-Bahrani, 2021).

Flattened shaped coronoid processes were found only in females which accounted for less percentage in accordance to previous study. Morphological variations are caused due to development and growth. Therefore morphology of the coronoid process is due to chewing habits, hormonal factors, heredity and growth. (Ashwinirani *et al.*, 2016)

Coronoid processes are used for reconstructive purposes-maxillofacial surgery, trauma, tumours, etc. The coronoid fracture was caused due to limitation of mandible movement and swelling of the particular region. Various radiographic methods have been used to treat coronoid fractures and traumas. The traumas can be observed by panoramic radiographs. CBCT were used for identifying coronoid fractures in accordance with previous study. Our study showed the various shapes of the coronoid process in the South Indian population using orthopantomogram. (Gunduz, 2019) The limitations of the study are that only retrospective studies were done so far.

Since this study had a small sample size, future research should incorporate OPGs from a variety of population groups to investigate how ethnic groupings differ, as well as a bigger sample size that includes a variety of ethnic groups. Future studies with large sample size can be conducted to get more reliable results and make the context evident,

## CONCLUSION:

From obtained results within the limitations of the study it can be concluded that round and triangular shape is observed to be a common occurrence and there is no significant difference found between males and females population. Future studies with live models and larger sample size should be conducted to make the context evident.

**ACKNOWLEDGEMENT:** We thank Saveetha Dental College and Hospitals for the successful completion of study.

**CONFLICT OF INTEREST:** The author declares that there was no conflict of interest in the present study.

**SOURCE OF FUNDING:** The present study was supported by following agencies:

- Saveetha Dental College
- Saveetha Institute of Medical and Technical Sciences (SIMATS)
- Saveetha University
- National insurance building, Parrys.

**REFERENCES:**

1. Al-Ghurabi, Z.H. and Al-Bahrani, Z.M. (2021) 'Cone Beam Computed Tomography Evaluation of the Morphological Variation and Width in Mandibular Condyle', *Journal of Craniofacial Surgery*. doi:10.1097/scs.00000000000007465.
2. Ashwinirani, S.R. et al. (2016) 'Gender determination by radiographic analysis of mental foramen in the Maharashtra population of India', *Journal of Forensic Dental Sciences*, p. 176. doi:10.4103/0975-1475.195114.
3. Dinesh, S.P.S. et al. (2013) 'An indigenously designed apparatus for measuring orthodontic force', *Journal of clinical and diagnostic research: JCDR*, 7(11), pp. 2623–2626.
4. Gomathi, A.C. et al. (2020) 'Anticancer activity of silver nanoparticles synthesized using aqueous fruit shell extract of Tamarindus indica on MCF-7 human breast cancer cell line', *Journal of drug delivery science and technology*, 55, p. 101376.
5. Govindaraju, L., Neelakantan, P. and Gutmann, J.L. (2017) 'Effect of root canal irrigating solutions on the compressive strength of tricalcium silicate cements', *Clinical oral investigations*, 21(2), pp. 567–571.
6. Gunduz, K. (2019) 'A Detailed CBCT Study of "Coronoid Foramina" and Accessory Foramina of the Mandible: a Unique Anatomic Variation', *Acta Clinica Croatica*. doi:10.20471/acc.2019.58.04.16.
7. Johnson, J. et al. (2020) 'Computational identification of MiRNA-7110 from pulmonary arterial hypertension (PAH) ESTs: a new microRNA that links diabetes and PAH', *Hypertension research: official journal of the Japanese Society of Hypertension*, 43(4), pp. 360–362.
8. Kasat, P.A. and Bhuiyan, P.S. (2016) 'A study on coronoid process of the dry adult human mandibles', *Journal of the Anatomical Society of India*, pp. 9–14. doi:10.1016/j.jasi.2016.07.007.
9. Krishnan, V. and Lakshmi, T. (2013) 'Bioglass: A novel biocompatible innovation', *Journal of advanced pharmaceutical technology & research*, 4(2), pp. 78–83.
10. Muthukrishnan, A. and Warnakulasuriya, S. (2018) 'Oral health consequences of smokeless tobacco use', *The Indian journal of medical research*, 148(1), pp. 35–40.
11. Martin-Moreno, J. M. (2020). Facing the COVID-19 challenge: When the world depends on effective public health interventions. *South Eastern European Journal of Public Health*, 14 doi:10.4119/seejph-3442
12. Mone, I., Kraja, B., Hyska, J., & Burazeri, G. (2021). Chocolate intake is associated with a lower body mass index in adult men and women in transitional albania. *South Eastern European Journal of Public Health*, 16, 1-9. doi:10.11576/seejph-4297
13. Msokwa, R. (2021). Improving access to health services in malawi. *South Eastern European Journal of Public Health*, 2021(Special Issue 2) doi:10.11576/seejph-4383
14. Mubarakah, K., Nurjanah, N., Handayani, S., Astarini, H. R., Maharani, A. W., Masitoh, D., . . . Yulianah, S. D. (2022). Tuberculosis literacy and stigma: Female activists in five areas with the lowest treatment success rate in semarang, indonesia. *South Eastern European Journal of Public Health*, 2022(Special Issue 2) doi:10.11576/seejph-5330
15. Panda, S. et al. (2014) 'Platelet rich fibrin and xenograft in treatment of intrabony defect', *Contemporary clinical dentistry*, 5(4), pp. 550–554.
16. Parveen, S. et al. (2018) 'A Morphological Study of Coronoid Process of Adult Human Dry Mandibles', *Journal of Medical Science And clinical Research*. doi:10.18535/jmscr/v6i4.27.
17. Pradhan, S. et al. (2014) 'Anatomical Study of Various Shapes of Mandibular Coronoid Process in Relation to Gender & Age', *IOSR Journal of Dental and Medical Sciences*, pp. 09–14. doi:10.9790/0853-13820914.
18. Saini, V. et al. (2011) 'Mandibular ramus: an indicator for sex in fragmentary mandible', *Journal of forensic sciences*, 56 Suppl 1, pp. S13–6.
19. Saraswathi, I. et al. (2020) 'Impact of COVID-19 outbreak on the mental health status of undergraduate medical students in a COVID-19 treating medical college: a prospective longitudinal study', *PeerJ*, p. e10164. doi:10.7717/peerj.10164.
20. Sathivel, A. et al. (2008) 'Anti-peroxidative and anti-hyperlipidemic nature of Ulva lactuca crude polysaccharide on D-galactosamine induced hepatitis in rats', *Food and chemical toxicology: an international journal published for the British Industrial Biological Research Association*, 46(10), pp. 3262–3267.
21. Sekar, D. et al. (2019) 'Methylation-dependent circulating microRNA 510 in preeclampsia patients', *Hypertension research: official journal of the Japanese Society of Hypertension*, 42(10), pp. 1647–1648.
22. Shakya, S. and Nagraj, S.K. (2013) 'Morphology of Coronoid Process and Sigmoid Notch in Orthopantomograms of South Indian Population', *World Journal of Dentistry*, pp. 1–3. doi:10.5005/jp-journals-10015-1193.
23. Srivastava, A. et al. (2016) 'Morphometric Analysis of Foramen Magnum in Gender Determination: A Radiographic Study', *International Journal of Preventive and Clinical Dental Research*, pp. 246–250. doi:10.5005/jp-journals-10052-005.