

Comparison Of The Accuracy Of Two Dimensional Radiographic Method With Cone Beam Computed Tomography In Assessment Of The Direction Of Impacted Maxillary Canine- A Radiographic Study

Dr. Kinnari Shah B.D.S , M.D.S¹ , Dr. Alap Shah B.D.S, M.D.S² , Dr. Anisha N. Prasad³ , Dr. Bharvi Jani B.D.S, M.D.S⁴ , Dr. Nidhi Agarwal B.D.S, M.D.S⁵ , Dr. Hemangi Raithatha B.D.S, M.D.S⁶

¹Senior Lecturer, Department of Orthodontics & Dentofacial Orthopaedics, Karnavati School of Dentistry, Uvarsad, Gandhinagar, Gujarat kinnarithakore27@gmail.com

²Professor and Head , Department of Orthodontics & Dentofacial Orthopaedics, Karnavati School of Dentistry, Uvarsad, Gandhinagar, Gujaratalap_shah06@yahoo.com

³Reader, Department of Orthodontics, Karnavati School of Dentistry, Gandhinagar, Gujarat, India-382422 anisha@karnavatiuniversity.edu.in

⁴Senior Lecturer, Department of Orthodontics & Dentofacial Orthopaedics, Karnavati School of Dentistry, Uvarsad, Gandhinagar, Gujarat . bharvijani@karnavatiuniversity.edu.in

⁵Senior Lecturer, Department of Orthodontics and Dentofacial Orthopaedics, Karnavati School of Dentistry, Uvarsad, Gandhinagar, Gujarat nidhi@karnavatiuniversity.edu.in

⁶Senior Lecturer, Department of Orthodontics & Dentofacial Orthopaedics, Karnavati School of Dentistry, Gandhinagar, Gujarat, India-382422 hemangiraithatha26@gmail.com

Corresponding author:

Dr. Kinnari Shah B.D.S , M.D.S

Senior Lecturer, Department of Orthodontics & Dentofacial Orthopaedics, Karnavati School of Dentistry, Uvarsad, Gandhinagar, Gujarat. kinnarithakore27@gmail.com

DOI: 10.47750/pnr.2022.13.S04.302

Abstract

Introduction: Maxillary canine is usually the last to erupt in the arch and therefore shows higher chances of impaction. Routinely used radiographic examination for impacted canine is Orthopantomogram (OPG) which has many limitation as it is a two dimensional (2D) image. Recently three dimensional (3D) imaging, Cone Beam Computed Tomography (CBCT), have been introduced which helps us with accurate three dimensional diagnosis of the impacted canine. This study was carried out to compare the radiographic diagnostic accuracy of CBCT with that of panoramic radiography for the localization of impacted maxillary canines.

Aims and Objectives: This study was carried out to compare the radiographic diagnostic accuracy of CBCT with that of panoramic radiography for the assessment of the position of impacted maxillary canines by three angular parameters and to determine a formula to get the accurate reading of 3D (CBCT) determined position of impacted canine from a 2D reading for all the three angles.

Materials and Method: 30 maxillary impacted canines were studied with standard OPG, CBCT and OPG generated from CBCT. Three angular measurements were studied namely, angle of maxillary impacted canine with the adjacent lateral incisor, occlusal plane and midline in OPG, CBCT and CBCT OPG.

Result: CBCT was found to be most accurate of all the three methods for all the three angular measurements. An equation was generated to calculate 3D measurements for all the three angular measurements using a 2D value.

Keywords: CBCT, Impacted canine, Orthopantomogram

INTRODUCTION:

Diagnosis of maxillary impacted canine plays an important role in orthodontics as canine is an important tooth for stability of arch and for an esthetic smile curve. User friendly and non-invasive two dimensional (2D) radiological imaging were the preferred method of choice for visualizing the intra-alveolar location of ectopic and impacted canines due to relatively easy availability of the procedure in dental offices as well as lower emission of radiation dose. However, 2D images have the drawbacks of magnification¹, tooth distortion and overlapping of structures due to the projection of complex three dimensional (3D) structures onto plain film, which reduce their diagnostic accuracy. Further, panoramic radiography has a limited diagnostic value in detecting early or mild root resorption.²⁻⁵

3D assessment of root resorption and root surface changes is required, especially in cases where the root of the lateral incisor is likely to show resorption and those cases where there are chances of ankylosis of canine.⁶ Computed Tomograph (CT) scan can be used to detect the position of the impacted canine and the extent of resorption of the adjacent root⁷ but, the high radiation dose is a major disadvantage, particularly in young children whose developing organs show greater response, for a longer duration of time, to radiation effects.^{3,9}

Cone Beam Computed Tomograph (CBCT) units emit a conical-shaped X-ray beam⁹ with reduced radiation exposure and is considered to be superior to other radiographic techniques in visualizing the maxillofacial region, especially in the diagnosis of the position of ectopically erupting teeth.¹⁰⁻¹³ without any overlap in sagittal, axial, and coronal planes. CBCT units have shorter acquisition scan times and are useful in analyzing the location of impacted canines with sub-millimetre spatial resolution images of high diagnostic accuracy which helps in better understanding at a lower cost.^{3,9-}

¹¹ Angular measurements are more commonly used comparative parameters for localizing the impacted canines radiographically.^{5,7,14-19}

Though CBCT is superior, it may not be feasible to get it everywhere. This study was carried out to compare the accuracy of 3D CBCT with that of panoramic radiography for the diagnosis of the position of impacted maxillary canines by three angular parameters and to determine a formula to get the accurate reading of 3D (CBCT) determined position of impacted canine from a 2D reading for all the three angles.

MATERIALS AND METHOD:

In the present study, 30 patients (aged 14-19 years) visiting the Department of Orthodontics and Dentofacial Orthopedics, Karnavati School of Dentistry, Uvarvad, Gandhinagar, with impacted maxillary canine were selected retrospectively. The patients were explained about the procedure orally and through bilingual patient information sheet and written informed consent was obtained from the patients as well as their parents.

Exclusion criteria

1. Patients with any syndrome or systemic disease
2. Patient with history of trauma to the maxillofacial region and any other contraindication for radiation exposure

Standard OPG were taken for each participant using an X MIND PANO D+ DIGITAL cephalostat (Figure 1). CBCT were obtained for each patient using Carestream (CS) 9000 3D Extraoral Imaging System (Figure 2). Each Maxillary impacted canine was assessed by CS 3D imaging software 3.2.9, Carestream health Inc. 3D Dicom data were recorded with the patient in natural head position with exposure factors of 90 kV, 10 mA, and 11.26s.

Image reconstruction was done for anatomical measurements. The imaging data was displayed on a Personal Computer monitor and reconstructed slices were 1 mm thick. An OPG was generated from the CBCT in the software which was also considered for examination.

Maxillary Impacted Canine Measurements On Standard OPG, OPG obtained from CBCT and CBCT Image:

To determine the position of maxillary impacted canine, three angles were measured (Figure 5, 6) in standard OPG, with CS 3D imaging software 3.2.9 in OPG obtained from CBCT and CBCT 3D image namely,

- A) Angle of impacted canine to the lateral incisor.
- B) Angle of impacted canine to midline.
- C) Angle of impacted canine to occlusal plane.

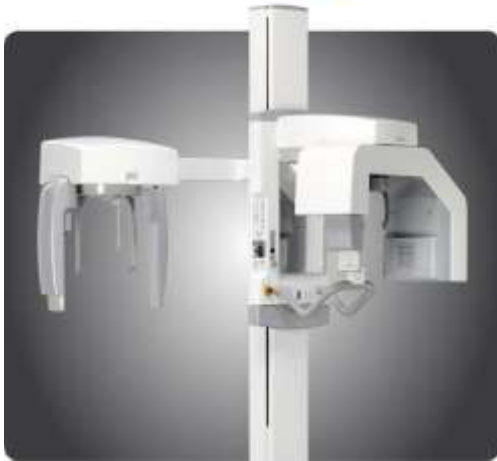

Figure 1: Digital OPG machine (X MIND PANO D+ DIGITAL)

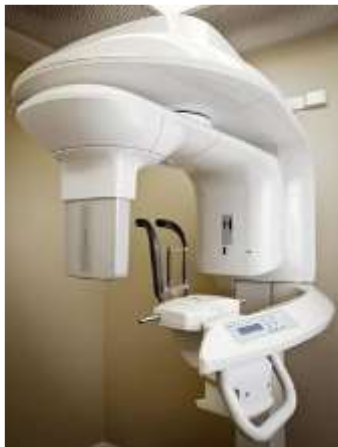

Figure 2: CBCT machine (CS 9000 3D Extraoral Imaging System by carestream)

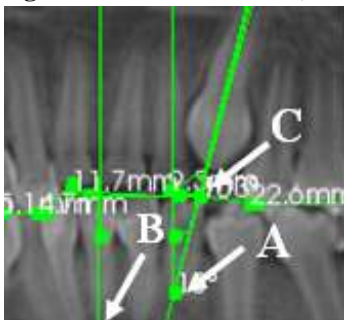


Figure 3: Angles measured in OPG

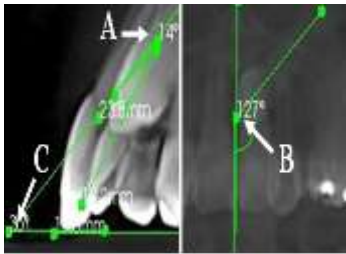


Figure 4: Angles measured in CBCT

STATISTICAL ANALYSIS

Data regarding the maxillary impacted canine measurements were analyzed using Statistical Package for Social Sciences (SPSS) for windows v.18.0 (SPSS Inc., Chicago, IL, USA). The mean and standard deviations were calculated for the same. One way Analysis of Variance (ANOVA) test was carried out to compare differences between three angular measurements in OPG, CBCT and CBCT.

Linear Regression line analysis was done to find out the error in all three groups and to predict the most accurate method for diagnosis. Linear Regression Formula was generated to calculate accurate reading of 3D from 2D image reading of all three groups. The generated formula can be used to calculate a 3D value using a 2D value for angular measurements of impacted canine.

RESULT

One way ANOVA test shows no significant difference between the three angular measurements.

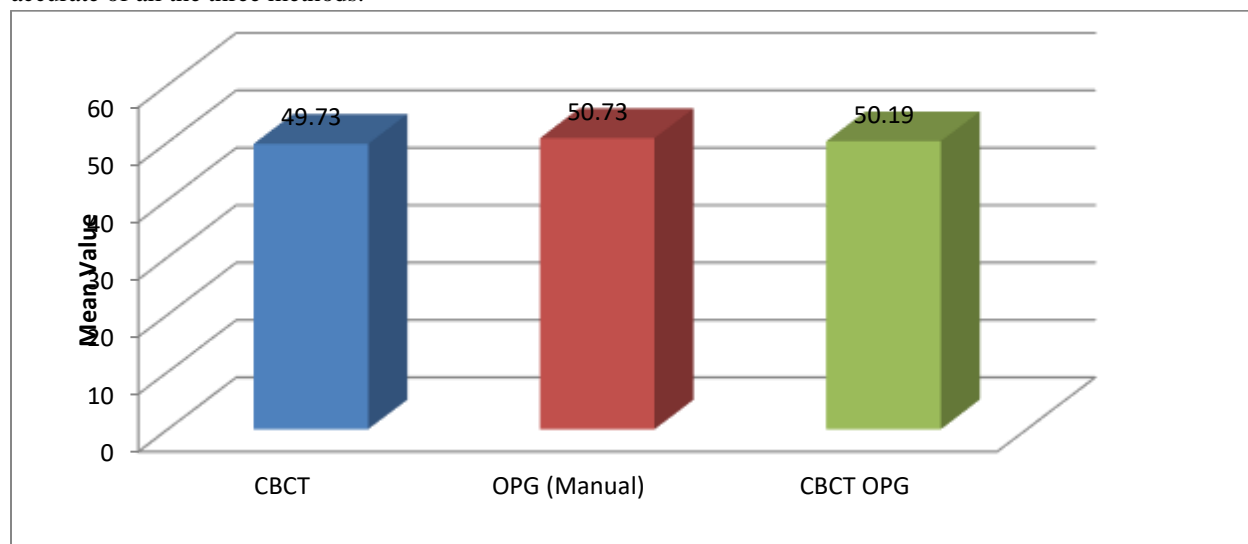
		N	Mean	SD	Standard Error	Min.	Max.	ANOVA p Value
Occlusal plane	OPG	30	50.73	22.37	4.085	14	80	0.984
	CBCT OPG	30	50.19	21.17	3.865	15	80	
	CBCT	30	49.73	20.41	3.727	16	88	
Lateral incisor	OPG	30	47.78	27.79	5.074	10	95	0.560
	CBCT OPG	30	45.87	27.33	4.990	9	93	
	CBCT	30	40.43	26.82	4.897	8	84	
Midline	OPG	30	40.08	26.72	4.878	6	81	0.510
	CBCT OPG	30	40.00	24.36	4.448	4	80	
	CBCT	30	33.70	21.72	3.966	4	74	

Table 1: One Way Anova Test To Compare The Three Angular Measurements

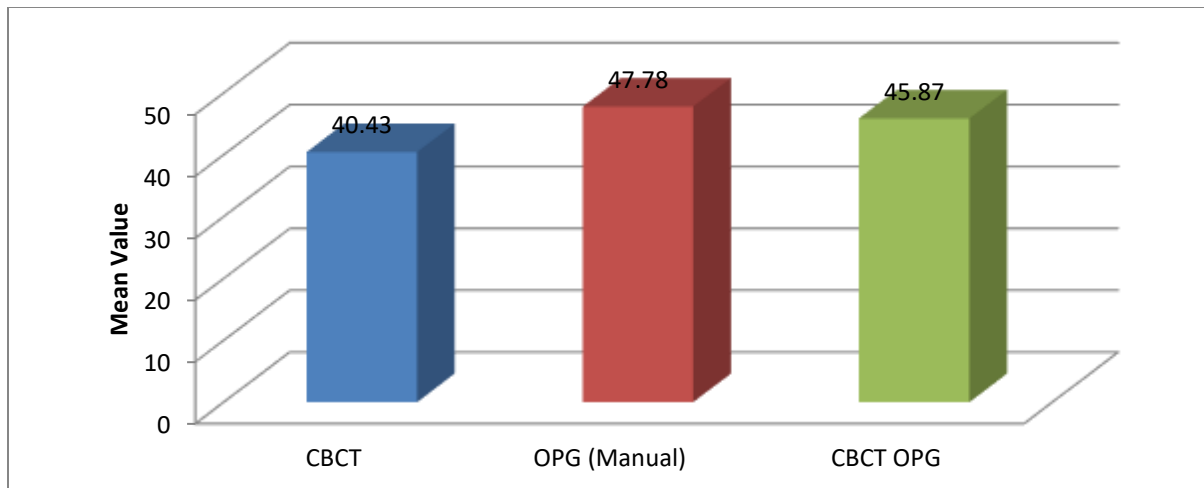
Table 2: Linear Regression Line Analysis To Determine The Standard Error And Accuracy Of The Three Methods:

		N	Mean	SD	Std. Error	R SQUARE
Occlusal plane	CBCT	30	49.73	20.41	3.727	
	OPG	30	50.73	22.37	4.085	0.766
	CBCT OPG	30	50.19	21.17	3.865	0.725
Lateral incisor	CBCT	30	40.43	26.82	4.897	
	OPG	30	47.78	27.79	5.074	0.908
	CBCT OPG	30	45.87	27.33	4.990	0.913
Midline	CBCT	30	33.70	21.72	3.966	
	OPG	30	40.08	26.72	4.878	0.943
	CBCT OPG	30	40.00	24.36	4.448	0.923

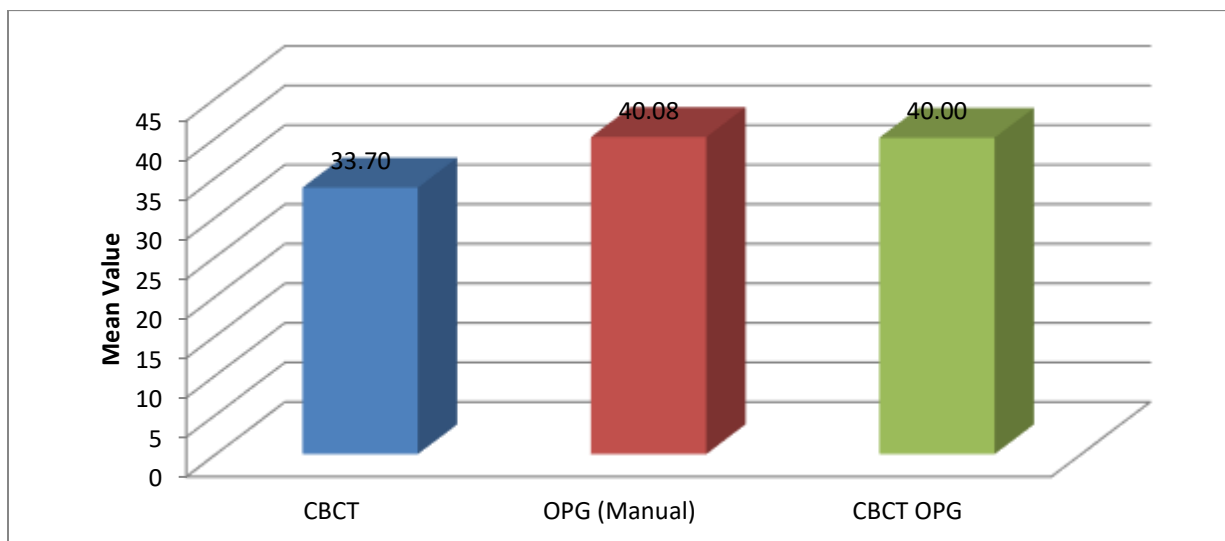
The standard error of CBCT for impacted canine angulations with occlusal plane, lateral incisor and midline are 3.727, 4.897 and 3.966 respectively, which are less as compared to OPG and CBCT OPG which suggest that CBCT is more accurate of all the three methods.



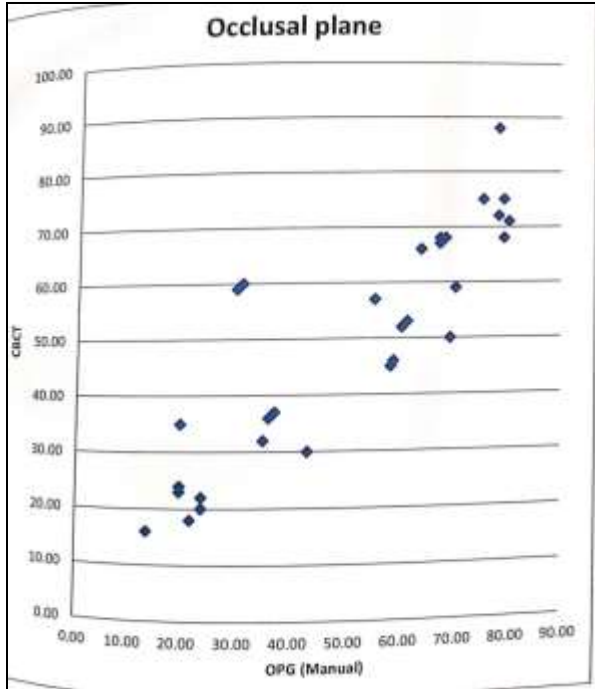
Graph 1: Comparison of all three calculating methods for impacted maxillary canine with occlusal plane



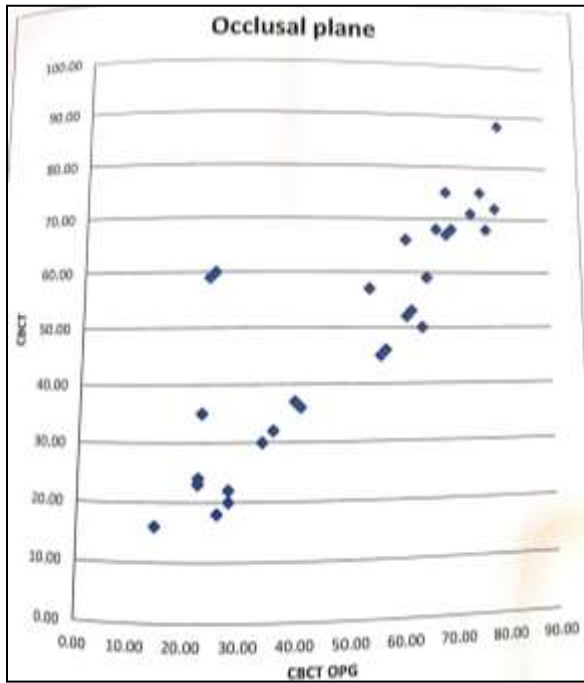
Graph 2: Comparison of all three calculating methods for impacted maxillary canine angle with lateral incisor



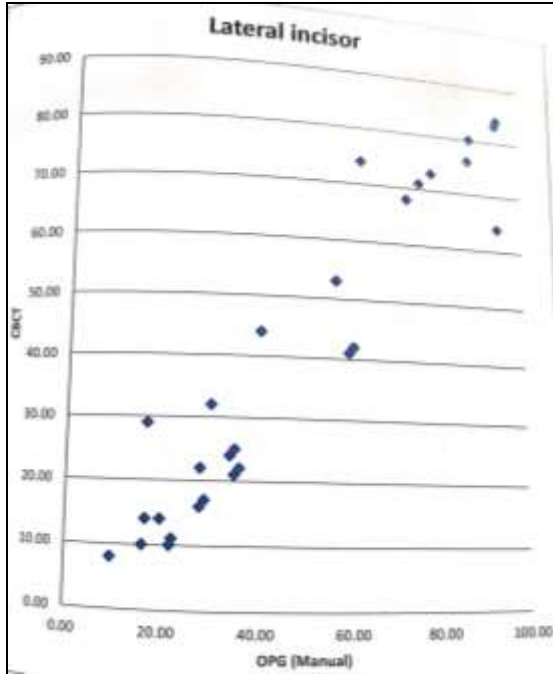
Graph 3: Comparison of all three calculating methods for impacted maxillary canine angle with midline



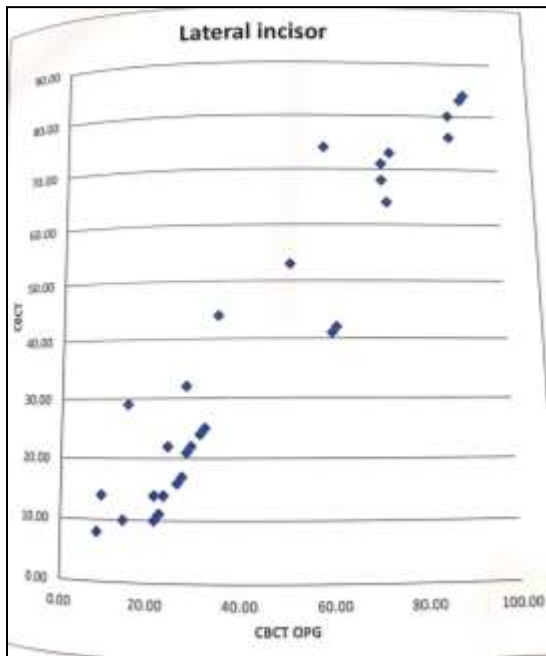
Graph 4 Comparison of the value of OPG with CBCT for impacted canine angle with occlusal plane



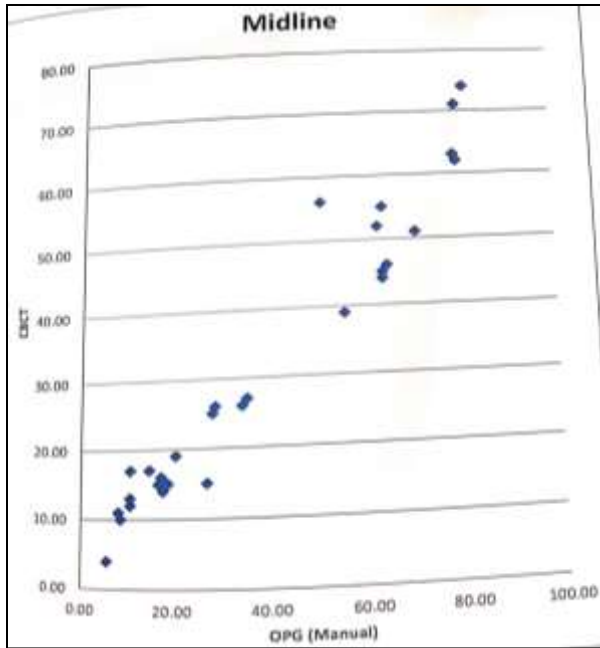
Graph 5 Comparison of the value of CBCT OPG with CBCT for impacted maxillary canine angle with occlusal plane



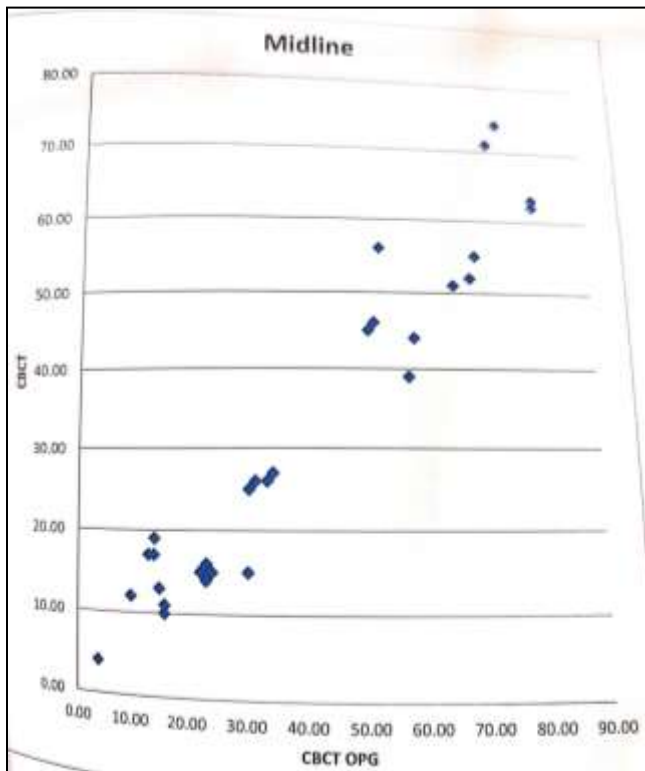
Graph 6 Comparison of the value of OPG with CBCT for impacted canine angle with lateral incisor



Graph 7 Comparison of the value of CBCT OPG with CBCT for impacted maxillary canine angle with lateral incisor



Graph 8 Comparison of the value of OPG with CBCT for impacted canine angle with midline



Graph 9 Comparison of the value of CBCT OPG with CBCT for impacted maxillary canine angle with midline

Comparison Of All The Three Calculating Methods:

Graph 4 and 5 show the scattered diagram comparing the angulation of impacted canine with occlusal plane between OPG and CBCT and that between CBCT and CBCT OPG respectively. It shows that when the value of the angulation in OPG and CBCT OPG increases, there is an increase in the CBCT value. The scattered diagram in Graph 6 and 7

shows that when the angulation of maxillary impacted canine with lateral incisor in OPG and CBCT OPG increases then the value in CBCT also increases. As the angulation of maxillary impacted canine with midline in OPG and CBCT OPG increases, the value increases in CBCT as well as shown in Graph 8 and 9.

LINEAR REGRESSION EQUATION:

A Linear regression equation had been generated to get the accurate reading of 3D (CBCT) from a 2D reading for all the three angles with the maxillary impacted canine:

$$Y=A+BX$$

Where Y is dependent variable and X is independent variable

Using the following equation to find A and B

$$\sum Y = \mu A + B \sum X$$

$$\sum XY = A \sum X + B \sum X^2$$

Angle with Occlusal Plane:

$$CBCT = 3.025 + 0.9592 \times OPG \text{ (Manual)}$$

$$CBCT = 6.2723 + 0.8831 \times CBCT \text{ OPG}$$

Angle With Lateral Incisor:

$$CBCT = 7.8578 + 0.9874 \times OPG \text{ (Manual)}$$

$$CBCT = 6.5042 + 0.9735 \times CBCT \text{ OPG}$$

Angle With Midline:

$$CBCT = 0.1687 + 1.1944 \times OPG \text{ (Manual)}$$

$$CBCT = 3.6980 + 1.0772 \times CBCT \text{ OPG}$$

DISCUSSION:

Intraoral 2D images were not considered to be accurate diagnostic tools for the detecting palatal root resorption of the lateral incisor.²⁰ 3D images are less influenced by the position of patient and overlap of the adjacent structures, they are not affected by the deformations observed on 2D panoramic images which may explain the differences obtained in the measurement in this study. Accuracy and reliability of angular parameters is increased which further aids in detecting the accurate position of the impacted maxillary canine.

According to Nagpal et al in 2009²¹, OPG and CBCT images show significant difference in locating the impacted canine because CBCT images provide accurate diagnostic information of the position of impacted canine in all the three planes namely, sagittal, axial, and coronal plane, without overlap. 3D images demonstrate higher association between the prevalence of root resorption of maxillary incisors and presence of impacted canines.^{4,10,12} When compared with 3D CT scans, panoramic radiography are found to be less reliable for assessment of incisor root resorption associated with impacted canines.^{1,22} Additionally, CBCT is considered to be more accurate than other radiographic methods for visualizing the maxillofacial region and as a useful tool for orthodontists in the assessment of ectopically erupting teeth.^{9,23,24}

The comparison of the angles of impacted canine with occlusal plane, midline and lateral incisor in all the three methods suggested that CBCT, which is a 3D image, is more accurate method and the result showed no significant difference between the three angular parameters. This study also concluded that if the value of any of the three angle increases in OPG and CBCT OPG then the angle in CBCT image also increases.

A Linear regression equation was generated using SPSS software to get the accurate reading of 3D (CBCT) from a 2D reading for all the three angles with the maxillary impacted canine. This formula can be useful in judging the exact position of canine in OPG especially in smaller towns where CBCT is not feasible. So, a 3D accurate reading for maxillary impacted canine can be obtained from a 2D data with the help of this formula.

CONCLUSION:

In present study it was found that CBCT (3D) imaging proved to be more reliable method for diagnosis of impacted canine. From the present study, we could derive a statistical formula which could help in assessing the position of maxillary impacted canine form OPG (2D) with accuracy of CBCT (3D) in case when CBCT is not available.

REFERENCES:

1. Freisfeld M, Dahl IA, Jäger A et al. X-ray diagnosis of impacted upper canines in panoramic radiographs and computed tomographs. *J Orofac Orthop* 1999; 60:177–184.
2. Preda L, et al. The use of spiral computed tomography in the localization of impacted maxillary canines. *Dento Maxillo Facial Radiology* 1997; 26: 236–241.
3. Heimisdottir K, Bosshardt D, Ruf S. Can the severity of root resorption be accurately judged by means of radiographs? A case report with histology. *American Journal of Orthodontics and Dentofacial Orthopedics* 2005; 128: 106–109.
4. Ericson S, Kurol P J. Resorption of incisors after ectopic eruption of maxillary canines: a CT study. *Angle Orthodontist* 2000; 70: 415–423.
5. Ericson S, Kurol J. Radiographic examination of ectopically erupting maxillary canines. *Am. J Orthod Dentofacial Orthop* 1987; 91:483–492.
6. Ericson S, Kurol J. CT diagnosis of ectopically erupting maxillary canines—a case report. *European Journal of Orthodontics* 1988; 10: 115–121.
7. Ericson S, Kurol J. Resorption of maxillary lateral incisors caused by ectopic eruption of the canines. A clinical and radiographic analysis of predisposing factors. *Am. J Orthod Dentofacial Orthop* 1988; 94:503–513.
8. Sameshima GT, Sinclair PM. Predicting and preventing root resorption: Part II. Treatment factors. *Am J Orthod Dentofacial Orthop* 2001; 119:511–515.
9. Scarfe W C, Farman A G, Sukovic P. Clinical applications of cone-beam computed tomography in dental practice. *Journal of the Canadian Dental Association* 2006; 72: 75–80.
10. Walker L, Enciso R, Mah J. Three-dimensional localization of maxillary canines with cone-beam computed tomography. *American Journal of Orthodontics and Dentofacial Orthopedics* 2005; 128: 418–423.
11. Korbmacher H, et al. Value of two cone-beam computed tomography systems from an orthodontic point of view. *J Orofac Orthop* 2007; 68:278–289.
12. Liu D G, et al. Localization of impacted maxillary canines and observation of adjacent incisor resorption with cone-beam computed tomography. *Oral Surgery, Oral Medicine, Oral Pathology, Oral Radiology and Endodontics* 2008; 105: 91–98.
13. Chen Y, et al. Three-dimensional spiral computed tomographic imaging: a new approach to the diagnosis and treatment planning of impacted teeth. *Am J Orthod Dentofacial Orthop* 2006; 130:112–116.
14. Stivaros N, Mandall NA. Radiographic factors affecting the management of impacted upper permanent canines. *Journal of Orthodontics* 2000; 27: 169–173.
15. Warford J, et al. Prediction of maxillary canine impaction using sectors and angular measurement. *American Journal of Orthodontics and Dentofacial Orthopedics* 2003; 124: 651–655.
16. Stramotas S, Geenty J P, Petocz P, Darendeliler M A. Accuracy of linear and angular measurements on panoramic radiographs taken at various positions in vitro. *European Journal of Orthodontics* 2002; 24: 43–52.
17. Laster W S, Ludlow J B, Bailey L J, Hershey H G. Accuracy of measurements of mandibular anatomy and prediction of asymmetry in panoramic radiographic images. *Dento Maxillo Facial Radiology* 2005; 34: 343–349.
18. Volchansky A, Cleaton-Jones P, Drummond S, Bönecker M. Technique for linear measurement on panoramic and periapical radiographs: a pilot study. *Quintessence International* 2006; 37: 191–197.
19. Follin M E, Lindvall A M. Detection of lingual root resorptions in the intraoral radiographs. An experimental study. *Swedish Dental Journal* 2005; 29: 35–42.
20. Quereshy F A, Savell T A, Palomo J M. Applications of cone beam computed tomography in the practice of oral and maxillofacial surgery. *Journal of Oral and Maxillofacial Surgery* 2008; 66: 791–796.
21. Nagpal A, Pai K M, Setty S, Sharma G. Localization of impacted maxillary canines using panoramic radiography. *Journal of Oral Science* 2009; 51: 37–45.
22. Honey O B et al. Accuracy of cone-beam computed tomography imaging of the temporomandibular joint: comparisons with panoramic radiology and linear tomography. *American Journal of Orthodontics and Dentofacial Orthopedics* 2007; 132: 429–438.
23. Schmuth G P, Freisfeld M, Koster O, Schuller H. The application of computerized tomography (CT) in cases of impacted maxillary canines. *European Journal of Orthodontics* 1992; 14: 296–301.
24. Angelopoulos C, et al. Comparison between digital panoramic radiography and cone-beam computed tomography for the identification of the mandibular canal as part of presurgical dental implant assessment. *Journal of Oral and Maxillofacial Surgery* 2008; 66: 2130–2135.